



## Large colon volvulus due to meconium impaction in a neonatal foal: a case report

Omid Azari<sup>a</sup>, Seyed mahdi Ghamsari<sup>a</sup>, Ali Roustaei<sup>a</sup>, Omid Koohestani<sup>b</sup>, Ahad Hassani<sup>c</sup>

<sup>a</sup> Department of Surgery and Radiology, Faculty of Veterinary Medicine, University of Tehran, Tehran, Iran.

<sup>b</sup> Student of Veterinary Medicine, Faculty of Veterinary Medicine, University of Tehran, Tehran, Iran.

<sup>c</sup> Doctor of Veterinary Medicine, Equine Practitioner in Tehran Province, Tehran, Iran .

### ABSTRACT

A 36 hours old foal was presented with abdominal pain and undefecation that did not respond to medical treatment. Physical examination revealed marked abdominal distension, mild tachycardia, tachypnea and high rectal temperature. Radiographic and ultrasonographic investigations confirmed the meconium impaction and large colon involvement. The case was recommended for urgent exploratory celiotomy. Close observation during surgery showed distention of small and large intestine and 360° volvulus of left colon associated with meconium impaction in small colon. After decompression and correction of large colon, impacted meconium was removed from the lumen via small colon enterotomy. The foal was recovered uneventfully and did not show any complication during 2 weeks follow up. This report suggested failure to pass meconium can cause other gastrointestinal disorders in neonatal foals.

### Keywords

Neonate foal, Meconium impaction, Colon volvulus, Colic pain

Number of Figures: 2  
Number of Tables: 0  
Number of References: 20  
Number of Pages: 7

### Abbreviations

LCV: large colon volvulus

## Introduction

Colic is a prevalent condition in equine neonates, which is a significant concern due to vast differential diagnosis possibilities, management difficulty, and non-pathognomonic clinical signs[1]. Abdominal pain may be caused by gastrointestinal origin (e.g., impactions, gastric ulcer) or extra-gastrointestinal one (e.g., mesenteric abscess, ovarian tumor) [2]. Studies revealed that most foals' gastrointestinal colic can be solved medically and will not require surgery[3]. Concurrent disorders, nonspecific clinical signs, and potential post-surgery medical problems, along with decreasing survival rate over time since the condition occurred, make the judgment intricate[1,3]. Surgical abdominal pains in foals are mainly associated with the small intestine. Large colon illnesses also include medical (Acute and chronic diarrhea) and surgical (obstruction). Large intestine obstructions are classified into simple, non-strangulating, and strangulating[1,4]. Meconium impaction is the simple and non-strangulating obstruction, and one of the most common causes of colic in equine neonate[5]. Retention of meconium may happen due to delayed ingestion of colostrum, dystocia, prematurity, low birth weight, birth asphyxia, and dehydration[6]. Impaction of meconium often resolved medically, and surgical intervention should be performed in unresponsive cases[6]. Large colon volvulus (LCV) and intussusception are strangulating obstructions, and both are reported rarely in neonate foals[1,4]. Despite the difficulty of making differentiating between surgical and medical therapy, foals with strangulating obstruction must be operated in the minimum time owing to the time-dependent success rate[3,4].

LCV usually begins rapidly and may lead to luminal obstruction and strangulating colic[4]. In this regard, neonates may show respiratory and cardiovascular signs, which can be helpful in diagnosis along with paraclinical evaluations. Generally, colon volvulus in horses with a degree exceeding 270° has a poor prognosis which even becomes lesser through time[7]. Many studies stated the fact that with faster referring and diagnostic processes and, eventually, operation, the survival rate will increase significantly[1,3,7].

In this case report, the clinical sign, diagnostic testing, and surgical findings of a 36 hours old neonate foal with a meconium retention followed by 360° large colon volvulus, will be described.

## Case Presentation

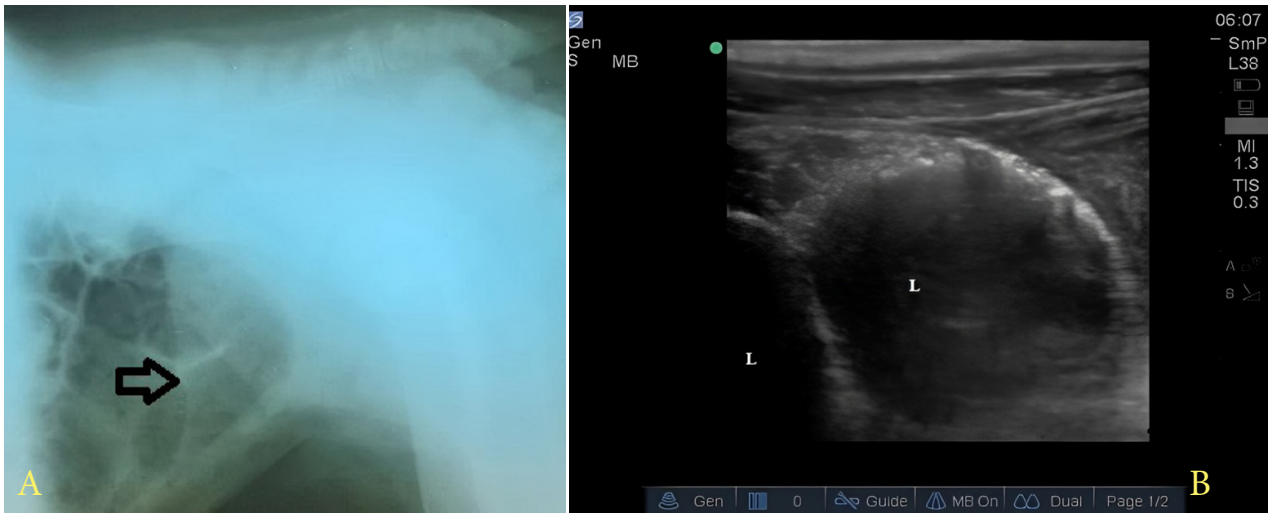
A 36 hours old male thoroughbred neonate foal weighing 48 kg, was presented with signs of abdominal pain and failure to pass the meconium to the large

animal veterinary hospital, University of Tehran. This case was referred to surgery after failure of medical therapy including enema by a veterinary practitioner. The colt demonstrated diminished appetite and was also letargic. No obvious abnormality had been found in the childbearing and gestation period. At the time of physical examination, the foal was alert and abdominal distension and moderate colic pain was evident. A digital examination of the rectum did not reveal meconium retention. On physical examination, the foal showed tachycardia (135 beats/min) and tachypnea (62 breaths/min), and high rectal temperature (40.2°C). Hematological examination revealed normal in red blood cell count ( $10.2 \times 10^{12}/L$ ), hemoglobin concentration (125 g/L) and hematocrit (43%). White blood cell count mildly increased ( $12 \times 10^9/L$ ) with neutrophilia.

Standing Radiography projection showed marked gaseously distended intestinal loops in caudoventral and middle aspect of abdomen measuring 1.5 to 1.7 times of first lumbar vertebrae with meconium retention in distal colon (Figure 1.A). For further examination, transabdominal ultrasonography was performed when the foal was in the lateral position that revealed gas-fluid distended, hypomotile and circular appearance of large and small intestinal loops with normal wall thickness (Figure 1.B). A multiple hyperechoic immobile well-defined curved surface with dirty distal shadowing artifacts was prominent in the small colon represented the meconium impaction. Free fluid was not noted in the peritoneal or retroperitoneal cavities. Meconium impaction was the primary diagnosis and we did not correlate severe distention of intestinal loops observing in Ultrasonography and radiography with retention of meconium, so based on paraclinical findings, and because the meconium impaction did not respond to medical treatment, an emergency exploratory celiotomy was recommended that accepted by the owner.

## Surgical Treatment

Intravenous catheters were placed in an aseptic fashion and sterile isotonic fluid (Sodium Chloride 0.9%, Intravenous Infusion) were given pre and intra-operatively (8mL/kg/h). The foal was pre-medicated with intravenous injection of flunixin meglumine (1.1 mg/kg BW) and Midazolam (0.1 mg/kg BW). Anaesthesia was induced using ketamine (2.2 mg/kg BW, IV) and maintained with isoflurane in medical oxygen on a semi-closed circle system. Then, the foal was positioned in dorsal recumbency and ventral surface of abdomen was prepared for aseptic surgery. A ventral midline incision (15 cm length) was created through the linea alba starting at the umbilicus and extending cranially.



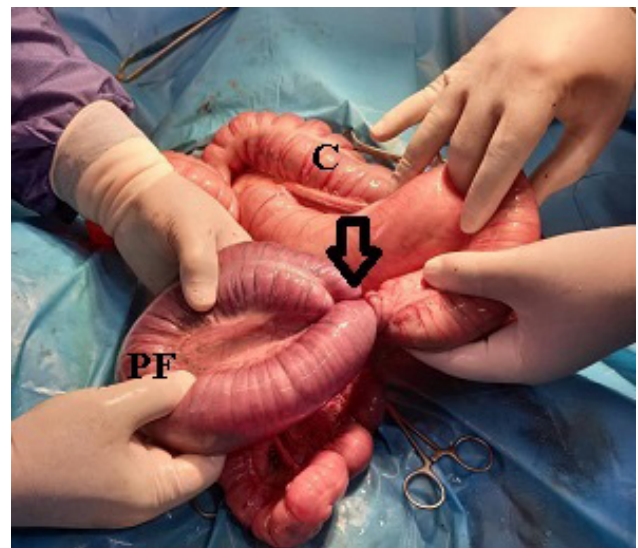
**Figure 1.**

A: Radiology, Standing radiography of foal abdomen shows marked gaseously distended intestinal loops (arrow) in caudoventral and middle aspect of abdomen. B: sonography, Sonographic imaging shows large intestinal loops (L) are dilated with fluid and gas echogenicity. Wall thickness is normal.

Initial exploration of abdominal cavity revealed marked distention of large colon. Also, mild non-specific small intestinal distension was present presumably due to the secondary ileus. The colon was decompressed of gas using an 18-gauge needle attached to a suction unit. Further exploration confirmed meconium impaction at distal region of small colon, and also 360° volvulus of left colons at the level of the sternal and diaphragmatic flexures (Figure 2). The twisted colon was corrected and the pelvic flexure was replaced in the correct orientation. Clinical evaluation of the colon including serosal colour, pulses in the ventral and dorsal colic arteries and colon motility showed that the tissue was alive. After that, the impaction of meconium was tried to break down by careful trans-luminal massage in combination with a warm water enema, but the attempt was unsuccessful and consequently, the enterotomy incision was performed in small colon and impacted meconium was removed. The enterotomy was closed in interrupted lembert pattern with 2-0 polyglactin 910 (Vicryl). The small intestinal contents were decompressed into the caecum, followed by decompression of both colon and caecum of free gas, using needle and suction unit. The abdominal viscera were copiously lavaged with warm normal saline and ventral midline incision was closed, routinely.

The foal recovered without any problem. Postoperative treatment included intravenous administration of 22000 IU/kg sodium benzylpenicillin QID, 6.6 mg/kg gentamicin SID and 1.1 mg/kg flunixin-meglumine SID, for 3 days. The foal discharged from the hospital, 3 days after the surgery. During two week

follow up, the owner declared that the foal defecated normally and had good appetite.



**Figure 2.**

On laparotomy exploration, a 360 degree volvulus (arrow) was observed in the left colon of neonate foal. PF: Pelvic flexure; C: Cecum

## Discussion

This study describes the clinical findings and surgical intervention of volvulus and meconium impaction occurring in 36 hours old foal. The simultaneous occurrence of these disorders is relatively rare in foals.

Among the colic origins, large colon volvulus have been reported rarely in foals[7]. Colon volvulus observed by Abutarbush et al. is the fourth most common cause of colic on presentation of adult hors-

es with an incidence of 7.3% [8]. In adult horses, LCV has an incidence of 10-21% among the surgical colics [9,10]. Large colon volvulus is 1st cause of euthanasia in surgical colics of mature horses. Mair and Smith (2005) revealed that volvulus is an important and killing condition, so initial recognition of this deadly disease is highly advisable [9]. Phillips and Walmsley (1993) reported that 53% of horses with surgical colic had a lesion of the large intestine of which one-third had LCV [11]. Although LCV is a common cause of surgical colic in adult horses, but less commonly reported in foals [12].

Vatistas et al. (1996) reported 5 foals among the 67 surgical colic had LCV [13]. In the study conducted by Adams et al. (1988) including 20 neonatal foals, torsion at the sternal and diaphragmatic flexures was observed in 3 foals [14]. In a review article of 119 abdominal surgery in foals, 5 foals had LCV, of which 4 patients were older than 3 months [15]. LCV was not reported in 137 neonate foals was reviewed in the University of Pennsylvania [3].

There are rare reports of LCV in 3 day-old neonates same as our report that the location of volvulus was the sternal and diaphragmatic flexures [1,12,14] reflecting these flexures may be a main site for LCV in neonatal foals. However, in adult horses, most of the volvulus occurs in cecal base or near the cecocolic fold because the colon region is freely movable in abdominal cavity and has a few attachments to the abdominal wall. Contributing factors for colonic motility is unknown in foals although differences in the morphology and density of myenteric plexuses between foals and adult horses have been reported and could influence colon motility pattern with animal age [1].

In a recent study concurrent large colon volvulus and atresia coli in 18 hours old foal was described and atresia coli result to hypoxia and inflammation may cause of LCV through the colon motility change [12]. A 360° LCV with meconium retention and intestinal incarceration has been described in 36 hours old colt [16]. We speculated that impaction in distal part of colon may cause of ileus and subsequently inflammation and vascular damage result in altered colon motility causing LCV.

Large-breed horses, post foaling, multiple colic episodes, feeding hay and restricted grazing are the risk factors for colonic volvulus in adult horses [12]. These factors are not contributed for the foals, but congenital malformation, undiagnosed colitis, abnormalities of the myenteric plexuses and intrauterine hypoxic injury to the colon put at foals to risk of LCV [1]. In the current patient, congenital malformation of the colon was not observed.

Due to small size of ponies and foals, transrectal palpation of the abdominal organs is out of the mind,

and it is suggested that paraclinical examinations such as radiography and transcutaneous abdominal ultrasound be used to make a correct diagnosis. Radiography is a good diagnostic tool for distinguishing lesions of the large and small intestines and had a sensitivity of 96% for detecting gastrointestinal disease in foals and the width of enlarged intestinal loops was measured with the length of the first lumbar vertebral body [17]. In the current patient markedly distention of intestinal loops measuring 1.5 to 1.7 times the L1 body length vertebrae showed obstruction caused by meconium impaction. For further evaluation, ultrasound was done and gaseous/fluid distention of the intestinal loops was noted and we did not speculate the LCV in this patient. Large colon volvulus diagnosis by transabdominal ultrasound in foals associated with difficulties reported by others [12,18]. However, Pease et al (2004) described that ultrasound finding in colon torsion in adult horses, including wall thickening in ventral site  $\geq 9$  mm, had a sensitivity of 67 % and a specificity of 100 % with high positive predictive value 100%, and also in another recent study marked large colon wall thickening proposed strangulated large intestine in neonatal foals [1,19]. It is suggested to measure colon wall thickening in colic foals that may support the colon strangulation, although no sign of wall thickening was observed in our ultrasound findings. Meconium impaction as described in the ultrasound of nonmoving sharp-edged particle in this report, close to description of sand impaction in adult horses, however, radiography is the gold standard for diagnosis of sand colic [20].

It is believed that survival rate in LCV surgery in horses depends on serosal colour of affected colon, degree of rotation and some laboratory and cardiopulmonary parameters. In more reports about the LCV in foals, euthanasia is selected for patients as the vascular compromise of colon and serosal colour changes [1], although patient in our study has no sign of discoloration of strangulated colon and survived two weeks follow up.

In conclusion, according to the current case report, distention of colon due to the meconium impaction may increase the risk of colon displacement or volvulus in foals that it urgently needs to surgical intervention.

### Authors' Contributions

O.A and S.G performed surgery and manuscript writing. A.R and O.K performed paraclinical examinations, review literature and manuscript draft. A.H performed clinical examination and case follow-up.

## Acknowledgments

Many thanks to the technical staff of the large animal hospital of Veterinary Faculty of Tehran University.

## Conflict of Interests

The authors declare that there is no conflict of interest.

## References

1. du Preez S, Trope GD, Owens C, Hughes KJ. Volvulus of the large colon in a neonatal foal. *Equine Vet Educ.* 2018;30[6]:306–11. DOI: 10.1111/eve.12730.
2. Nikahval B, Vesal N, Ghane M. Surgical correction of small colon faecalith in a Dare-Shuri foal. *Turkish J Vet Anim Sci.* 2009;33[4]:357–61. DOI: 10.3906/vet-0802-14.
3. MacKinnon MC, Southwood LL, Burke MJ, Palmer JE. Colic in equine neonates: 137 cases [2000–2010]. *J Am Vet Med Assoc.* 2013;243[11]:1586–95. DOI: 10.2460/javma.243.11.1586.
4. Constable PD, Hinchcliff KW, Done SH, Grünberg WBT-VM [Eleventh E, editors. 8 - Diseases of the Alimentary Tract–Ruminant. In W.B. Saunders; 2017. p. 436–621. Available from: <https://www.sciencedirect.com/science/article/pii/B9780702052460000085>.
5. Prange T. Small colon obstructions in foals. *Equine Vet Educ.* 2013;25[6]:293–6. doi: 10.1111/eve.12040.
6. Auer JA, Stick JA. *Equine surgery-E-book.* Elsevier Health Sciences; 2018.
7. Jones SL, Fecteau G, Hullinger PJ, Bickett-Weddle DA, St. Jean G, Nichols S, et al. • Chapter 32 - Diseases of the Alimentary Tract. In: Smith BP, Van Metre DC, Pusterla NBT-LAIM [Sixth E, editors. St. Louis [MO]: Mosby; 2020. p. 702–920. e35. Available from: <https://www.sciencedirect.com/science/article/pii/B978032355445900032X>.
8. Abutarbush SM, Carmalt JL, Shoemaker RW. Causes of gastrointestinal colic in horses in western Canada: 604 cases [1992 to 2002]. *Can Vet J.* 2005;46[9]:800.
9. Mair TS, Smith LJ. Survival and complication rates in 300 horses undergoing surgical treatment of colic. Part 1: Short-term survival following a single laparotomy. *Equine Vet J.* 2005 Jul;37[4]:296–302. DOI: 10.2746/0425164054529409.
10. Gonzalez LM, Fogle CA, Baker WT, Hughes FE, Law JM, Motsinger-Reif AA, et al. Operative factors associated with short-term outcome in horses with large colon volvulus: 47 cases from 2006 to 2013. *Equine Vet J.* 2015;47[3]:279–84. DOI: 10.1111/evj.12273.
11. Phillips TJ, Walmsley JP. Retrospective analysis of the results of 151 exploratory laparotomies in horses with gastrointestinal disease. *Equine Vet J.* 1993;25[5]:427–31. DOI: 10.1111/j.2042-3306.1993.tb02985.x.
12. McGovern KF, Gough RL. Large Colon Volvulus in a Neonatal Foal Secondary to Atresia Coli. *J Equine Vet Sci.* 2022;119:104114. DOI: 10.1016/j.jevs.2022.104114.
13. Vatistas NJ, Snyder JR, Wilson WD, Drake C, Hildebrand S. Surgical treatment for colic in the foal [67 cases]: 1980–1992. *Equine Vet J.* 1996 Mar;28[2]:139–45. doi: 10.1111/j.2042-3306.1996.tb01606.x.
14. Adams R, Koterba AM, Brown MP, Cudd TC, Baker WA. Exploratory celiotomy for gastrointestinal disease in neonatal foals: a review of 20 cases. *Equine Vet J.* 1988 Jan;20[1]:9–12. DOI: 10.1111/j.2042-3306.1988.tb01442.x.
15. Cable CS, Fubini SL, Erb HN, Hakes JE. Abdominal surgery in foals: a review of 119 cases [1977–1994]. *Equine Vet J.* 1997 Jul;29[4]:257–61. DOI :10.1111/j.2042-3306.1997.tb03120.x.
16. Lillich JD, Goggin JM, Valentino LW, Flaminio M, Rush BR. Volvulus of the large colon in a foal. *Equine Vet Educ.* 2000;12[1]:18–9. DOI: 10.1111/j.2042-3292.2000.tb01757.x
17. Fischer Jr AT, Kerr LY, O'Brien TR. Radiographic diagnosis of gastrointestinal disorders in the foal. *Vet Radiol.* 1987;28[2]:42–8. DOI: 10.1111/j.1740-8261.1987.tb01722.x
18. McAuliffe SB. Abdominal ultrasonography of the foal. *Clin Tech Equine Pract.* 2004;3[3]:308–16. DOI: 10.1053/j.ctep.2005.02.008.
19. Pease AP, Scrivani P V, Erb HN, Cook VL. Accuracy of increased large-intestine wall thickness during ultrasonography for diagnosing large-colon torsion in 42 horses. *Vet Radiol Ultrasound.* 2004;45[3]:220–4. DOI: 10.1111/j.1740-8261.2004.04038.x.
20. Korolainen R, Ruohoniemi M. Reliability of ultrasonography compared to radiography in revealing intestinal sand accumulations in horses. *Equine Vet J.* 2002;34[5]:499–504. DOI: 10.2746/042516402776117764.

**COPYRIGHTS**

©2024 The author(s). This is an open access article distributed under the terms of the Creative Commons Attribution (CC BY 4.0), which permits unrestricted use, distribution, and reproduction in any medium, as long as the original authors and source are cited. No permission is required from the authors or the publishers.

**How to cite this article**

Azari O, Ghamsari SM, Roustaei A, Koohestani O, Hassani A. Large colon volvulus due to meconium impaction in a neonatal foal: a case report. Iran J Vet Sci Technol.2024; 16(1): 60-65.

DOI: <https://doi.org/10.22067/ijvst.2023.83244.1276>

URL [https://ijvst.um.ac.ir/article\\_44563.html](https://ijvst.um.ac.ir/article_44563.html)