



## Comparing the protective effects of L-carnitine and *Silybum marianum* aqueous extract after diazinon-induced hepatotoxicity in male rat liver

Forough Masoumi, Mehrdad Shariati, Mokhtar Mokhtari

Department of Biology, Kazerun Branch, Islamic Azad University, Kazerun, Iran

### ABSTRACT

Diazinon (DZN), as an organophosphorus pesticide, induces oxidative stress leading to the generation of free radicals, and causes some pathological changes in the body. The purpose of this study was to assess the protective effects of L-carnitine (LC) and *Silybum marianum* aqueous extract (SMAE) against DZN-induced hepatotoxicity in male rat liver. Rats were assigned in 9 groups and were subjected to different combinations of DZN, SMAE, and LC. Thirty days after the treatment by oral gavage, blood samples were taken and serum levels of aspartate aminotransferase (AST), alanine aminotransferase (ALT), alkaline phosphatase (ALP), gamma-glutamyl transferase (GGT), Albumin (Alb) and total protein (TP) were measured using photometric method. The liver samples were also evaluated histopathologically. The DZN treatment significantly increased the AST, ALT, ALP and GGT levels ( $p < 0.05$ ) and conversely decreased the Alb and TP levels ( $p < 0.05$ ). Moreover, administration of the DZN resulted in lymphocytic inflammation, congestion, hepatocytes apoptosis, and lesser sinusoidal space. However, administration of SMAE and LC along with DZN treatment stabilized the ALT, ALP, GGT, Alb and TP levels ( $p > 0.05$ ), but increased the AST levels significantly compared to the control ( $p < 0.05$ ). Besides that, lesser structural alterations and improvement in the liver tissue were observed. These findings suggest that co-administration of SMAE and LC could reduce DZN-induced hepatic tissue damages and improve the hepatic biochemical parameters in male rats.

### Keywords

Diazinon, L-carnitine, *Silybum marianum*, Hepatotoxicity, Rat

### Abbreviations

DZN: Diazinon  
OP: Organophosphorus pesticide  
LC: L-carnitine  
SAME: *Silybum Marianum* Aqueous Extract  
SM: *Silybum Marianum*  
AST: Aspartate aminotransferase  
ALT: Alanine aminotransferase  
ALP: Alkaline phosphatase  
GGT: Gamma-glutamyl transferase  
Alb: Albumin  
TP: Total protein

## Introduction

Liver is the largest gland in the body which performs a variety of functions, including protein synthesis, storing required substances, metabolic functions, disinfecting harmful substances, producing and secreting bile as well as controlling metabolism [1]. Organophosphorus pesticide (OP) refers to various toxic compounds that contain phosphorus in their basic structure. They have been introduced to the world market since 1960s. Since they were more potent than other toxins such as organochlorine, OP compounds replaced other toxins rapidly. In 1970, due to their environmental and food chain contamination they were only used in certain cases in developed countries, however, they are still used in some countries [2].

One of the most important OPs used to control insects in agriculture is DZN. This compound is easily and quickly (within a few hours) absorbed by the intestine [3,4]. This compound inhibits acetylcholine esterase through the phosphorylation of amino acid serine at its active site, resulting in the accumulation of acetylcholine in cholinergic synapses, and causing cholinergic seizure and brain injury and death in acute cases [5,6]. DZN is also absorbed through skin and respiratory tract, and rapidly metabolized to diazoxide in the liver. Most OP compounds are converted to active toxic metabolites in the liver by the cytochrome P450 system through oxidative desulphurization [7]. It should be noted that the side effects of these compounds depend on the type of toxin, dose, duration of exposure and also the tissue. The main mechanism of OP action, especially DZN, is inhibiting acetylcholine esterase [8]. They are alkylated agents that react with cellular macromolecules, such as proteins, nucleic acids and lipids, and alter their functions [9]. Some researchers believe that DZN induces oxidative stress by producing free radicals and reactive oxygen, and induces cell death in organisms by increasing lipid peroxidation [10]. Indeed, exposure to DZN causes severe histopathologic damages in the kidney and liver [11].

Antioxidant compounds play an important role in preventing damages and pathological changes caused by free radicals. For example, LC prevents oxidative stress and regulates nitric acid, cellular respiration, and the activity of enzymes involved in oxidative stress [12,13]. The antioxidant system consists of three enzymes: glutathione peroxidase, catalase and superoxide dismutase. As an antioxidant compound, LC can protect these enzymes against oxidative damage; it is also very effective in modulating age-related changes [14]. Food sources of amino acid carnitine are very important. Approximately 75% of total carnitine is

obtained from carnitine, lysine, and methionine food sources [15]. The condition of carnitine in the human body depends on the body composition, sex and diet. There are two sources for these amino acids: (1) diet and (2) degradation of endogenous proteins. Micronutrients such as iron, vitamin C, pyridoxine and niacin are essential for the synthesis of carnitine [16].

The plant *Silybum marianum* (SM) is an annual or biennial plant of the *Asteraceae* family [17]. SM has global vegetation and is native to Iran as well [18]. SM contains silybin, isosilybin, silydianin and taxifolin, which are collectively called flavonoids silymarin. Silymarin is found in all parts of the plant and is considered as the main and effective compound of SM. The main pharmacological properties of this plant include: antioxidant, anti-inflammatory and anti-cancer effects and also protecting hepatic cells against many liver toxins [19,20].

Since LC and SM show antioxidant and anti-inflammatory effects and are used in the treatment of liver disorders, in this study, we tried to investigate their possible hepatoprotective effects in DZN-induced hepatic damage in male rats.

## Results

### Biochemical analysis findings

Table 1 and 2 represent the mean and standard deviation (SD) of the serum levels of ALT, AST, ALP, and GGT as well as Alb and TP among different groups, respectively. The findings of this study showed that there was no significant difference in the serum levels of ALT, AST, ALP, GGT, Alb and TP between the control and sham groups ( $p > 0.05$ ). Compared to the control and sham groups, the serum levels of ALT, AST, ALP, and GGT increased significantly ( $p < 0.05$ ) in the DZN15 group, while the serum levels of Alb and TP decreased significantly ( $p < 0.05$ ).

Statistical comparison of the results showed that there were no significant differences in the serum levels of ALT, AST, ALP, GGT, Alb and TP in the SMAE100, LC300 and SMAE100 + LC300 groups, when compared to the control and sham groups ( $p > 0.05$ ).

In the DZN15+MS100 and DZN15+LC300 groups, the serum levels of ALT, AST, ALP, and GGT increased significantly compared to the control and sham groups ( $p < 0.05$ ); however, they showed a significant decrease compared to the DZN15 group ( $p < 0.05$ ). In addition, the serum levels of Alb and TP decreased significantly in the DZN15 + MS100 and DZN15 + LC300 groups compared to the control and sham groups ( $p < 0.05$ ); while, showed a significant increase compared to the DZN15 group ( $p < 0.05$ ).

In the DZN15 + SMAE100 + LC300 group, the se-

**Table 1**

Comparison of serum levels of aspartate aminotransferase (AST), alanine aminotransferase (ALT), alkaline phosphatase (ALP), and gamma glutamyl transferase (GGT) in different groups.

Groups	AST (u/l)	ALT (u/l)	ALP (u/l)	GGT (u/l)
Control	359.87 ± 10.46	82.37 ± 5.18	777.62 ± 16.26	5.37 ± 0.406
Sham	365.12 ± 09.49	84.87 ± 4.51	769.75 ± 13.62	5.27 ± 0.541
DZN15	782.25 ± 11.81 <sup>a</sup>	180.25 ± 9.06 <sup>a</sup>	1278.62 ± 37.30 <sup>a</sup>	11.43 ± 0.462 <sup>a</sup>
SMAE100	362.25 ± 10.12 <sup>b</sup>	84.62 ± 7.81 <sup>b</sup>	779.00 ± 18.60 <sup>b</sup>	5.26 ± 0.434 <sup>b</sup>
LC300	356.00 ± 09.05 <sup>b</sup>	85.42 ± 4.57 <sup>b</sup>	773.00 ± 16.69 <sup>b</sup>	4.87 ± 0.281 <sup>b</sup>
SMAE100 + LC300	352.25 ± 08.27 <sup>b</sup>	81.00 ± 4.24 <sup>b</sup>	769.75 ± 14.95 <sup>b</sup>	4.91 ± 0.285 <sup>b</sup>
DZN15 + LC300	533.00 ± 07.65 <sup>a,b</sup>	115.125 ± 5.56 <sup>a,b</sup>	1001 ± 55.79 <sup>a,b</sup>	7.68 ± 0.318 <sup>a,b</sup>
DZN15 + SMAE100	513.28 ± 07.52 <sup>a,b</sup>	105.42 ± 10.57 <sup>a,b</sup>	949.00 ± 73.07 <sup>a,b</sup>	6.87 ± 1.17 <sup>a,b</sup>
DZN15+ SMAE100 + LC300	411.87 ± 13.95 <sup>a,b</sup>	90.25 ± 4.13 <sup>b</sup>	804.12 ± 19.88 <sup>b</sup>	5.22 ± 0.310 <sup>b</sup>

Data is shown as mean ± SD.

a,  $p < 0.05$  as compared to the control and sham groups

b,  $p < 0.05$  as compared to the DZN15 group

**Table 2**

Comparison of serum levels of Albumin (Alb) and Total protein (TP) in different groups.

Groups	Alb (g/dl)	TP (g/dl)
Control	3.55 ± 0.244	6.58 ± 0.473
Sham	3.53 ± 0.277	6.52 ± 0.337
DZN15	1.75 ± 1.92 <sup>a</sup>	3.85 ± 0.272 <sup>a</sup>
SMAE100	3.60 ± 0.261 <sup>b</sup>	6.28 ± 0.485 <sup>b</sup>
LC300	3.52 ± 0.269 <sup>b</sup>	6.20 ± 0.258 <sup>b</sup>
SMAE100 + LC300	3.97 ± 0.361 <sup>b</sup>	6.00 ± 0.392 <sup>b</sup>
DZN15 + LC300	2.68 ± 0.247 <sup>a,b</sup>	5.30 ± 0.272 <sup>a,b</sup>
DZN15 + SMAE100	3.24 ± 0.403 <sup>a,b</sup>	5.23 ± 0.297 <sup>a,b</sup>
DZN15 + SMAE100 + LC300	3.47 ± 0.265 <sup>b</sup>	6.67 ± 0.310 <sup>b</sup>

Data is shown as mean ± SD.

a,  $p < 0.05$  as compared to the control and sham groups

b,  $p < 0.05$  as compared to the DZN15 group

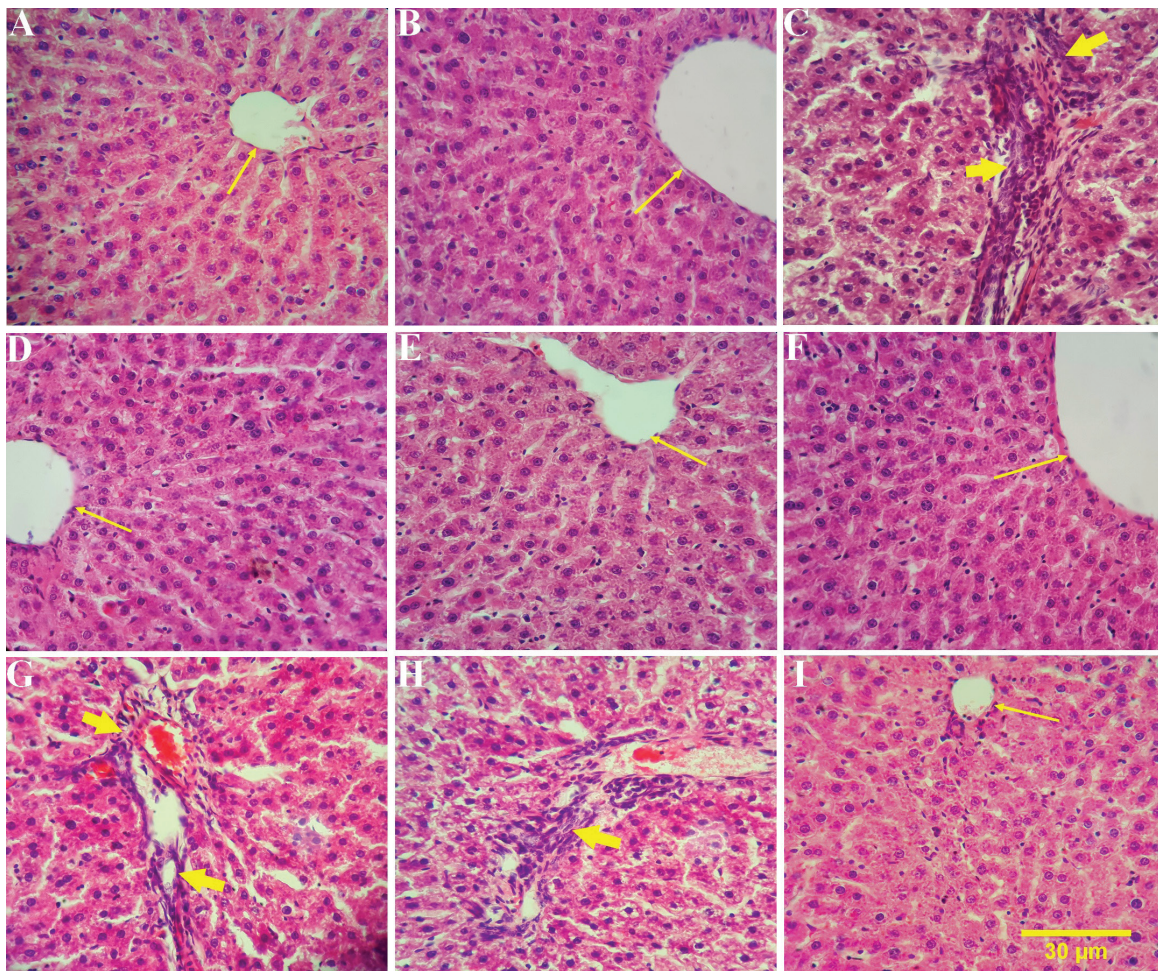
rum levels of ALT, AST, ALP, and GGT decreased significantly compared to the DZN group ( $p < 0.05$ ) but the serum levels of Alb and TP increased significantly ( $p < 0.05$ ). Although, there was no significant difference in the serum levels of ALT, ALP, GGT, Alb and TP ( $p > 0.05$ ), the serum levels of AST increased significantly in the DZN15 + SMAE100 + LC300 group compared to the control and sham groups ( $p < 0.05$ ).

### Histopathological findings

Histopathological findings on the liver tissues indicated that the liver parenchymal cells, sinusoid spaces and central vein in the control and sham groups were

completely normal and were not damaged (Figure 1A and 1B). In the DZN15 group, lymphocytic inflammation, congestion, hepatocyte apoptosis, and lesser sinusoidal space were observed (Figure 1C). There were no signs of liver damage in the LC300, SMAE100, and SMAE100 + LC300 groups (Figure 1D, 1E and 1F). In the DZN15 + LC300 and DZN15 + SMAE100 groups, lymphocytic inflammation and vacuolization of cytoplasm were detected (Figure 1G and 1H). Histological cross-sectional study in the DZN15 + SMAE100 + LC300 group revealed lesser pathological changes and improvement in the liver tissue compared to the DZN group (Figure 1I).





**Figure 1**

Histopathological analysis of liver in different groups. H&E 100× (A-I). A) Control, B) Sham, C) DZN15, D) SMAE100, E) LC300, F) SMAE100+LC300, G) DZN15+ LC300, H) DZN15+SMAE100, I) DZN15+SMAE100+LC300.

## Discussion

In the present experimental study, the effects of LC, SMAE and DZN toxin on the serum levels of hepatic enzymes (ALP, ALT, AST and GGT), Alb and TP in adult male rats were investigated. Since these hepatic enzymes are intracellular, and enter bloodstream in cases where cell damage occurs, it can be concluded that DZN is able to damage hepatocytes.

In the present study, the elevated level of ALP in the DZN15 group is possibly the result of the cholestasis, and the increase in the levels of ALT and AST in this group is likely to result from liver cell necrosis. Similarly, it has been shown that the intake and absorption of DZN by the liver increases the serum levels of ALT, ALP and AST in mice [21]. Also, in their experiments on rabbits, Solati et al., reported that DZN increases activities of ALT, ALP and AST [22], which is consistent with the results of this study. Gokcimen et al., reported that DZN caused pathological changes including hepatocyte necrosis and infiltration of inflammatory cells due to the activity of detoxification of the liver and the production of high levels of free radicals

in the liver cells in rats [23]. OP damage the cells and tissues of the body by increasing lipid peroxidation, cell apoptosis and free radical production as well as inhibition of the activity of antioxidant enzymes such as superoxide dismutase, glutathione peroxidase and catalase [24,25].

In the SMAE100, LC300 and SMAE100+LC300 groups, administrating SMAE and LC alone as well as co-administration of SAME+LC did not make a significant difference in the serum levels of AST, ALT, ALP, GGT, Alb and TP in comparison with the control and sham groups. However, in all three groups compared to the DZN group, the serum levels of liver enzymes decreased significantly, while the serum levels of Alb and TP increased significantly. In accordance with the results of biochemical parameters, histopathologic study in all three groups indicated that the liver tissue structure was completely normal and similar to the control and sham groups. It has been reported that the use of natural antioxidant compounds can play an important role in improving and decreasing oxidative stress damages. The safety of synthetic antioxidants has always been questioned, therefore, using natural

plant sources has been considered with regard to active antioxidant compounds in the recent years (26). SM has a wide range of biochemical effects on various tissues of the body (27). This plant inhibits metabolic disorders by increasing cellular glutathione level and due to the fact that it is a potent antioxidant, it can prevent metabolic disturbances and apoptosis by removing free oxygen radicals (28,29).

It has been shown that prescribing LC at a dose of 100 mg/kg can increase glutathione levels (30). LC stimulates the complex of pyruvate dehydrogenase and increases the entry of pyruvate into the beta oxidation pathway, which causes more use of oxygen and lipids oxidation. It also reduces the production of free radicals by reducing the production of Acetyl-CoA and helps to repair the oxidative damage of the phospholipid membrane and ultimately to prevent apoptosis (31).

Administering LC and SMAE in the DZN15 + LC300 and DZN15 + SMAE100 groups showed that compared to the control and DZN15 groups, the serum levels of AST, ALT, ALP and GGT significantly increased and decreased, respectively, while the serum levels of Alb and TP decreased and increased significantly, respectively. Also, according to histopathologic results and the significant changes in biochemical parameters, lymphocytic inflammation and vacuolization of cytoplasmic space of hepatocytes were observed. The results of this study indicate that the administration of LC and SMAE alone in the doses used can improve the relative biochemical parameters and histopathologic changes compared to the DZN15 group, however, it seems that co-administration of LC and SMAE would be effective in reducing further hepatotoxicity effects induced by DZN.

According to the results obtained for DZN15+SMAE100+LC300 group, simultaneous administration of SMAE and LC reduces the serum levels of ALT, ALP and AST relative to the DZN15 group. This means that the simultaneous use of both the extract and the drug has an effective protective effect on the hepatocyte damages caused by DZN. Polyphenolic compounds in the SMAE and LC can protect the liver cells against DZN toxin through different mechanisms. They may preserve the cell membrane stability through preventing the oxidation of membrane lipids by the active metabolites produced from DZN intake. They can also repair cell damages by stimulating protein synthesis in damaged cells. Phenolic compounds may also reduce the damage caused by DZN through stimulating detoxification systems as well as increasing the glutathione-reduction capacity of the hepatocytes [27,32,33]. Of course, these effects can be more noticeable in the long term consumption of SMAE and LC.

It can be argued that SMAE prevents the progression of liver damage and inhibits liver cirrhosis by its numerous properties such as antioxidant, anti-lipid peroxidase, anti-fibrotic, anti-inflammatory, immune-regulation and liver cell regeneration. The significantly decreased AST and ALT levels in the DZN15+SMAE100 group confirms that the compounds present in SMAE can protect outer membrane of the hepatocytes, preventing penetration of toxic substances as well as increasing the ribosomal protein synthesis and thus, improving liver function [34].

In an in vitro study, Gulchin showed that LC has an antioxidant effect against free radicals of superoxide and hydrogen peroxide [35]. Hence, as an antioxidant compound capable of destroying free radicals, LC is able to reduce the damage caused by DZN in the liver tissue.

According to our results, the serum levels of Alb and TP significantly declined in the DZN15 groups. Alb is one of the most important circulating proteins that accounts for more than half of the plasma protein. It is made by the liver and secreted in the bloodstream. Blood Alb level is a sensitive and valuable parameter of liver function and its decline is a sign of liver failure [36]. A recent study by Yehia et al., on rabbits poisoned with DZN reports a decrease in Alb and TP levels; this decline was considered to be the result of an increase in proteolytic activity due to post-poisoning stress [37].

Since the levels of Alb and TP significantly declined in the DZN15 group while their levels increased significantly in the groups receiving mixture of DZN, LC and or SMAE, it can be argued that DZN toxin damages hepatic tissues leading to failure in producing enough Alb, but when the SMAE and LC are used (especially in the DZN15+SMAE100+LC300 group) the liver functions are restored. In other words, the concomitant use of the toxin, extract or the drug may have effective protective influences on the liver cells against the damage caused by DZN. These beneficial effects may essentially be the result of antioxidant properties of phenolic compounds present in SM, which allows them to act as reducing agents (hydrogen donor and oxygen inactivator). In general, the results of this study showed that the combination of SMAE and LC can have beneficial effects on restoring serum levels of hepatic enzymes and proteins like Alb in rats intoxicated by DZN. This combination may have antioxidant properties capable of eliminating free radicals leading to a reduction in DZN-induced hepatic injuries that provides a suitable therapeutic approach to use in such toxin poisoning.



## Material and methods

### Animals

Seventy-two adult male Wistar rats weighing  $220 \pm 20$  g and 2 months old were provided from the animal house of Kazerun Islamic Azad University and were kept at the same place. The animals were supplied with water and food ad libitum. During the study, animals were exposed to standard conditions at  $22 \pm 2$  °C, 12-hour light and 12-hour darkness cycles and 70% humidity in polycarbonate cages. The protocol of this study was approved by the Ethics Committee of Islamic Azad University of Kazerun, Iran, in relation to working with laboratory animal care (No. IR.Kiau 15230509971001).

### Medications

LC was purchased from Merck Company (Germany) and technical DZN with 95 percent purity was obtained from Sam Gol Company (Iran). Normal saline was used to prepare LC solution.

### Preparing SMAE

The aerial part of the SM contains the stem and seeds dried and then powdered. 100 g of the powder was added to 500 ml of distilled water and mixed well, and then kept at room temperature for 24 hours. The mixture was mixed using magnetic heating stirrer at 60 °C for 1 hour. The extract was centrifugated for 20 minutes at 10,000 rpm and then filtered. The extract was stored in the refrigerator until it was used [38].

### Study design

The animals were assigned in 9 groups of 8 each including: the control group (left untreated and only received water and food), the sham group (received normal food, water and 1 ml distilled water as the drug solvent), the DZN group (received 15 mg/kg DZN), the SMAE100 group (received 100 mg/kg SM aqueous extract), the LC300 group (received 300 mg/kg LC), the SMAE100+LC300 group (received 100 mg/kg SM aqueous extract and 300 mg/kg LC in the afternoon), the DZN+LC300 group (received 15 mg/kg DZN in the morning and 300 mg/kg LC in the afternoon), the DZN+SMAE100 group (received 15 mg/kg DZN in the morning and 100 mg/kg SM aqueous extract in the afternoon), and the DZN+SMAE100+LC300 group (received 15 mg/kg DZN in the morning and 100 mg/kg SM aqueous extract as well as 300 mg/kg LC in the afternoon). The extract and the drugs were administered in all groups by oral gavage for 30 days. The acute oral LD50 (the dose to kill half the population of laboratory animals) of DZN have been determined to be 1250 mg/kg body weight for the rats [39,40]. The basis for selecting the dose of DZN and LC was based on the previous studies (40,41).

### Biochemical analysis

At the end of the treatment period, animals were anesthetized with diethyl ether (Merck, Germany), and blood samples were taken from their left heart ventricle using a 5 ml sterile syringe. Blood samples were transferred into the test tubes without anticoagulant, and were centrifugated at 5000 rpm for 15 minutes. The supernatant (serum) was isolated by sampler, transferred to new tubes, covered by Parafilm, and stored at -20 °C to be tested later. The serum levels of AST, ALT, ALP, GGT, Alb and TP were evaluated spectrophotometrically (Pars kits, Pars Co., Iran) using the Technicon RA-1000 machine (USA).

### Histopathological analysis

After blood sampling, and euthanasia, the animal's abdomi-

nal cavity was opened and the livers of all rats were removed. The tissue samples were washed with physiological normal saline and fixed in 10% formalin buffer solution. After the dehydration in alcohol with increasing concentrations of 60% to absolute, they became transparent using xylene and then were blocked in paraffin. 10 sections of 5-micron thickness of each liver tissue were stained by H & E method and eventually, the tissue changes were studied using a light microscope. In each section, five different areas were randomly investigated, and the number of lymphocytes, the levels of apoptosis, congestion, sinusoidal spaces, and vacuolization of cytoplasm were studied.

### Statistical analysis

The results were analyzed using SPSS software version 20 (SPSS Inc., Chicago, IL, USA). The results normalization were confirmed using the Kolmogorov-Smirnov test. The significance level was defined as  $p < 0.05$ , and was applied to examine the significant difference between the experimental and control groups by one-way ANOVA and post-hoc Tukey's tests. The results are shown as mean  $\pm$  standard deviation (SD) in the tables.

### Acknowledgment

We thank Department of Biology, Kazerun Branch of Islamic Azad University for providing the facilities of physiological laboratory.

### Author Contributions

Designed the experiments, performed statistical analysis and revised the manuscript: M.S., M.M. Performed histopathological analysis and wrote the manuscript: F.M. All authors approved the final version of the manuscript.

### Conflict of Interest

None declared.

### References

1. Raju SBG, Battu RG, Manju latha YB, Srinivas K. Antihepatotoxic activity of smilax china roots on CCL4 induced hepatic damage in rats. *Int J Pharm Pharm Sci.* 2012;4:494-6.
2. Pehkonen SO, Zhang Q. The degradation of organophosphorus pesticides in natural waters: A critical review. *Crit Rev Env Sci Tec.* 2002;32:17-72.
3. GarWtt SJ, Jones K, Mason HJ, Cocker J. Exposure to the organophosphate diazinon: data from a human volunteer study with oral and dermal doses. *Toxicol Lett.* 2002;134:105-13.
4. Ogutcu A, Uzunhisarcikli M, Kalender S, Durak D, Bayraktar F, Kalender Y. The effects of organophosphate insecticide diazinon on malondialdehyde levels and myocardial cells in rat heart tissue and protective role of vitamin E. *Pes Biochem Physiol.* 2006;86:93-98.
5. Abdollahi M, Mostafalou S, Pournourmohammadi S, Shadnia S. Oxidative stress and cholinesterase inhibition in salvia and plasma of rats following subchronic exposure to malathion. *Comp Biochem. Physiol.* 2004;137:29-34.
6. Singh B, Dogra TD, Tripathi CB. A study of serum cholinesterase activity in agricultural and industrial workers occupationally exposed to organophosphates insecticides. *Int J Med Toxicol.* 2002;5:2-5.

7. Zhang HX, Sultatos LG. Biotransformation of the organophosphorus insecticides parathion and methyl effects of black tea extract. *Clinica Chimica Acta*. 2005;358:131-38.
8. Kappers WA, Edwards RJ, Murray S, Boobis AR. Diazinon is activated by CYP2C19 in human liver. *Toxicol Appl Pharmacol*. 2001;177:68-76.
9. Mohamed SS, Desouky TA, Mohamed SR, Naguib KM, Helmy MH. Antioxidant compounds from rice straw extract and their effect on diazinon insecticide hazard. *Middle East J Appl Sci*. 2015;5:687-94.
10. Sargazi Z, Nikravesh MR, Jalali M, Sadeghnia HR, Rahimi Anbarkeh F. Apoptotic effect of organophosphorus insecticide diazinon on rat ovary and protective effect of vitamin E. *IJT*. 2016;10:37-44.
11. Tsitsimpikou C, Tzatzarakis M, Fragkiadaki P, Kovatsi L, Stivaktakis P, Kalogeraki A, et al. Histopathological lesions, oxidative stress and genotoxic effects in liver and kidneys following long term exposure of rabbits to diazinon and propoxur. *Toxicology*. 2012; 307: 109-14.
12. Kolodziejczyk J, Saluk-Juszczak J, Wachowicz B. L-carnitine protects plasma components against oxidative alterations. *Nutrition*. 2011;27:693-99.
13. Ribas G, Manfredini V, Marco M, Vieira R, Wayhs C, Vanzin C, et al. Prevention by l-carnitine of DNA damage induced by propionic and l-methylmalonic acids in human peripheral leukocytes in vitro. *Mutat Res*. 2010;702:123-28.
14. ArokiaRani P, Panneerselvam C. Carnitine as a free radical scavenger an aging. *Exp Gerontol*. 2001;36:1713-26.
15. Steiber A, Kerner J, Hoppel C. Carnitine: a nutritional, biosynthetic and functional perspective. *Mol Aspects Med*. 2004;25:455-73.
16. Sayed-Ahmed M. Role of carnitine in cancer chemotherapy-induced multiple organ toxicity. *Saudi Pharm J*. 2010;18:195-206.
17. Francis R. *The wild flower hey*. 4th ed. Frederick: Warne Publisher; 2006.
18. Cacho M, Moran M, Corchete P, Fernández Tárrago J. Influence of medium composition on the accumulation of flavonolignans in cultured cells of *Silybum marianum* (L.) Gaertn. *Plant Sci*. 1999;144:63-68.
19. Kumar Kalla P, Chitti S, Aghamirzaei ST, Senthilkumar R, Arjunan S. Anti-cancer activity of silymarin on MCF-7 and NCIH-23 cell lines. *Adv Biol Res*. 2014;8:57-61.
20. Gupta OP, Sing S, Bani S, Sharma N, Malhotra S, Gupta BD, et al. Anti-inflammatory and anti-arthritis activities of silymarin acting through inhibition of 5-lipoxygenase. *Phyto-medicine*. 2000;7:21-24.
21. Gomes J, Dawodu AH, Lloyd O, Revitt DM, Anilal SV. Hepatic injury and disturbed amino acid metabolism in mice following prolonged exposure to organophosphorus pesticides. *Hum Exp Toxicol*. 1999;18:33-37.
22. Solati A, Tavasoli A, Koochi MK, Marjanmehr SH, Nekouie Jahromi OA. The toxic pathologic effects of Diazinon on histopathological biochemical and hemathological parameters in Rabbits by dermal exposure of toxin. *J Vet Res*. 2011;66:103-12.
23. Gockcimen A, Gulle k, Demirin H, Bayram D, Kocak A, Altunsa I. Effects of diazinon at different doses on rat liver and pancreas tissues. *Pest Bp*. 2007;87:103-108.
24. Altuntas I, Kilinc I, Orhan H, Demirel R, Koylu H, Delibas N. The effects of diazinon on lipid peroxidation and antioxidant enzymes in erythrocytes in vitro. *Hum Exp Toxicol*. 2004; 23:9-13.
25. Fattahi, E, Parivar K, Jorsaraei SGA, Moghadamnia AA. The effect of diazinon on the leydig cells and the level of sex hormones in mice. *J Babol Univ Med Sci*. 2007;9:15-22.
26. Osawa T, Kato Y. Protective role of antioxidative food factors in oxidative stress caused by hyperglycemia. *Ann NY Acad Sci*. 2005;1043:440-51.
27. Schuppan D, Jia JD, Brinkhaus B, Hahn EG. Herbal products for liver diseases. *Hepatology* 1999;30:1099-1104.
28. Campos R, Garrido A. Silybin dihemisuccinate protects against glutathioine depletion and lipid peroxidation induced by acetaminophen on rat liver. *Plant. Meidca*. 1998; 55:417-429.
29. Gazak R, Wahterova D and Kren V. Silybin and Silymarin. New and emerging applications in medicine. *Current Medicinal Chemistry* 2007;14:1-23.
30. El-habit O, Ahmed M, Gabry M, Kahil M, Osman A. Modulation of induced cardiocytotoxicity and genotoxicity of Doxorubicin in rat by L-Carnitine. *J egypt Nat Cancer Inst* 2000;12:267-274.
31. Karlic H, Lohninger A. Supplementation of L-carnitine in athletes: does it make sense? *Nutrition* 2004;20:709-15.
32. Peyrat-Maillard MN, Bonnely S, Ber-set C. Determination of the antioxidant activity of phenolic compounds by coulometric detection. *Talanta*. 2000;51:709-16.
33. Zix MH, Agarwal R. Novel cancer chemopreventive effects of a flavonoid antioxidant silymarin. *Biochm Biophys Res Commun*. 1997;239:334-39.
34. Schonfeld JV, Weisbrod B, Muller MK. Silibinin aplant extract with antioxidant and membrane stabilizing properties, protects exocrine pancreas from cyclosporine toxicity. *CMLS*. 1997;53:917-20.
35. Gulcin I. Antioxidant and antiradical activities of L-carnitine. *Life Sci*. 2006;78:803-11.
36. Rezaei-Tavirani M, Mahdavi SM, Heidarjan E. Electrochemical study of attaching the active substance HPB to human serum Albumin. *J Ilam Uni Med Sci*. 2006;4:38-43.
37. Yehia M, El-Banna SG, Okabm AB. Diazinon toxicity affects histophysiological and biochemical parameters in rabbits. *Exp Toxicol Pathol*. 2006;59:215-25.
38. Sajadi SM, Nasrollahzadeh M, Maham M. Aqueous extract from seeds of *Silybum marianum* L. as a green material for preparation of the Cu/Fe<sub>3</sub>O<sub>4</sub> nanoparticles: A magnetically recoverable and reusable catalyst for the reduction of nitroarenes. *J Colloid Interface Sci*. 2016;469:93-98.
39. Woodward K, Marrs T, Waters MD. *Toxicological effects of veterinary medicinal products in humans*. 1th ed. Cambridge: RSC Press; 2012.
40. Rahimi. S. Zamiri MJ. Shariati M. Changizi-Ashtiyani S. Moghadamnia D. Rahimi A. Effect of Diazinon on pituitary-gonadal axis and histological alteration of seminiferous tubules in adult rat testis. *J Gorgan Univ Med Sci*. 2016;18:23-28.
41. Hussein SA, Abd El-Hamid OM, Hemandan HS. Protective effect of l-carnitine on metabolic disorders, oxidative stress, antioxidant status and inflammation in a rat model of insulin resistance. *BVMJ*. 2013; 25:99-112.





## مقایسه اثرات محافظتی ال کارنیتین و عصاره آبی خار مریم پس از سمیت کبدی القا شده با دیازینون در کبد موش صحرائی نر

فروغ معصومی، مهرداد شریعتی، مختار مختاری

گروه زیست شناسی، واحد کازرون، دانشگاه آزاد اسلامی، کازرون، ایران

### چکیده

دیازینون (DZN) یک آفت کش ارگانوفسفور (OP)، با ایجاد استرس اکسیداتیو منجر به تولید رادیکال های آزاد و تغییرات پاتولوژیک در بدن است. هدف این مطالعه بررسی اثرات محافظتی ال کارنیتین (LC) و عصاره آبی خار مریم (SMAE) در برابر سمیت کبدی القا شده با DZN در کبد موش صحرائی نر است. موش ها در ۹ گروه (n=۸) شامل کنترل، شم، LC300، SMAE100، DZN15، SMAE100 + LC300، DZN15 + LC300، DZN15 + SMAE100 قرار گرفتند. ۳۰ روز پس از درمان تحت گواژ دهانی، نمونه خون گرفته شد و سطح سرمی آسپاراتات آمینوترانسفراز (AST)، آلانین آمینو ترانسفراز (ALT)، آلکالین فسفاتاز (ALP)، گاما گلوتامیل ترانسفراز (GGT)، آلبومین (Alb) و پروتئین تام (TP) با استفاده از روش فوتومتریک اندازه گیری شد. همچنین، کبد موش ها جدا گردید و مورد ارزیابی هیستوپاتولوژیک قرار گرفت. درمان با DZN15 به طور معناداری سطح AST، ALT، ALP و GGT را افزایش داد ( $p < 0.05$ ) و برعکس، میزان Alb و TP را کاهش داد ( $p < 0.05$ ). تجویز DZN15 موجب التهاب لنفوسیتی، پرخونی، آپوپتوزیس هیپاتوسیت ها و کوچکتر شدن فضای سینوزوئیدی شد. با این حال، درمان با DZN15 + SMAE100 سطح ALT، ALP، GGT، Alb و TP را تغییر نداد ( $p < 0.05$ )، اما سطح AST را به میزان قابل توجهی نسبت به گروه کنترل افزایش داد ( $p < 0.05$ ). همچنین، تغییرات ساختاری کمتر و بهبود در بافت کبد مشاهده شد. یافته های این مطالعه نشان می دهد که تجویز همزمان SMAE و LC می تواند آسیب های بافت کبدی القا شده با DZN را کاهش دهد و پارامترهای بیوشیمیایی کبدی را در موش های صحرائی بهبود بخشد.

### واژگان کلیدی

دیازینون، ال کارنیتین، خار مریم، سمیت کبدی، موش صحرائی