

An outbreak of ulcerative stomatitis due to mouse barely (*Hordeum murinum*) in horse

Gholamreza Mohammadi^{1*}, Kamran Sardari¹

¹ Department of Clinical Sciences, School of Veterinary Medicine, Ferdowsi University of Mashhad, Mashhad, Iran.

Received: May 1, 2009

Accepted: June 5, 2009

Abstract

Stomatitis and gingivitis were diagnosed in twenty-six of 96 horses at a club in Mashhad, Iran. Clinical examination of the affected horses revealed varying degrees of ulceration at the gum-tooth margins with many awns (seed heads) embedded in ulcers. The ulcers were painful, up to 5 cm in diameter, and located at the labial-gingival junction, the lingual frenulum, the base of the lingual dorsum, soft palate, and the sides of the tongue. The evaluation of feed ingredients which had been fed to the affected horses showed contamination of alfalfa hay to mouse barley (*Hordeum murinum*) seed heads. After removal of the contaminated hay from the ration, the ulcers healed slowly over about 3 weeks.

Key words: Ulcerative stomatitis, gingivitis, *Hordeum murinum*, horse.

Corresponding author: Gholamreza Mohammadi
Email: gmohamad@ferdowsi.um.ac.ir
Tel: +98 511 8788944
Fax: +98 511 8763852

The mucous membranes of the lips, oral cavity, gingiva, tongue, and oropharynx, are commonly subjected to varying degrees of trauma. In herbivores, the coarse nature of pasturage and roughage can cause laceration or abrasions of the mucosa (Jones et al., 1997; McCluskey and Mumford 2000; Radostits et al., 2007). Sharp awns or spines on plants like as *Hordeum murinum* were reported a health hazard for dogs and other domestic animals (Brennan and Ihrke ,1983; Koutinas et al., 2003; Ammari et al., 2000; Aslani, 2002). *Hordeum murinum* (mouse barley) is an annual weedy grass that grows in pastures

and gardens throughout the temperate Northern hemisphere. It also contaminates the forage such as alfalfa. Different physical injuries have been reported in sheep and cattle due to penetration of awns of this plant (Aslani, 2002). *Hordeum murinum* awns can cause multiple painful nodules on the lips of horses (Radostits et al., 2007). This paper describes an outbreak of ulcerative stomatitis in horses due to *Hordeum murinum* awns, which can be an important cause of stomatitis and should be differentiated from other causes of ulcerative stomatitis.

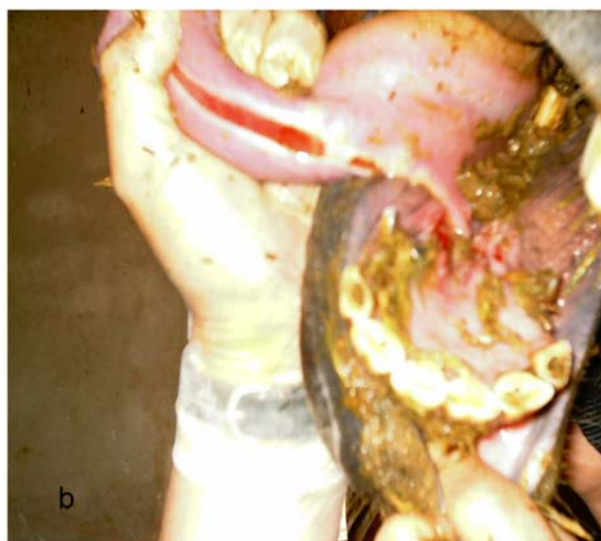
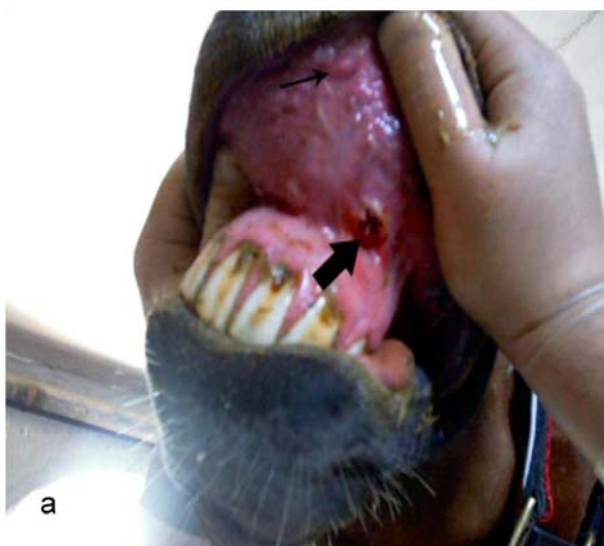

Figure 1: a; Plant- awn ulcers in the labial vestibule is evident in an affected horse. b; Plant- awn ulcers in the ventral surface of the tongue is evident in an affected horse.

Case Report

In early May 2004, a horse riding club in Mashhad suburb was visited because of the report of inappetence and drooling in several horses. A total of 96 horses of different breeds and ages were kept in two different stables (which we refer to A and B thereafter). Twenty- six (13 male and 13 female) horses were kept in stable A and seventy (45 male

and 25 female) horses were kept in stable B. The horses had been fed a mixture of alfalfa hay and grain obtained from different sources and free access to water. They were bedded on clean straw obtained from a common source. The horses were kept in individual box stalls, but were otherwise allowed to commingle outdoor.

Table1: Result of haematological and biochemistry examination of 12 affected horses to physical stomatitis due to *Hordeum murinum* (Mean \pm SD)

	Affected animals	Reference values*
PCV%	30.60 \pm 3.43	32-53
Haemoglobin (g/dl)	11.09 \pm 1.34	11-19
Erythrocyte ($10^9/\mu\text{l}$)	5.74 \pm .63	6.8-12.9
Leucocyte (μl)	8518 \pm 2958	5400-14300
Fibrinogen(mg/dl)	545 \pm 29	200-400
Total protein(g/dl)	7.3 \pm .58	6 -7.7
Urea(mg/dl)	20 \pm 4.3	10-24
Creatinine(mg/dl)	1.1 \pm 0.34	0.9-1.9

* Kaneko JJ: Clinical Biochemistry of domestic Animals. 5th Ed, New York, Academic press 1997.




Figure2: a; *Hordeum murinum* (mouse barley) caused physical disruption of tissues and organs such as oral cavity and skin. b; The spikelet cluster is held together by a portion of rachis.

Horses began to refuse eating hay, while showing excess salivation several days ago. On clinical examination, vital signs were normal. There was no abnormality on conjunctival mucous membranes. Examination of the oral cavity revealed varying degrees of ulcerative lesions in the mouth. The lesions were large (2-8 cm long and 5 mm wide) and linear in shape. There were very painful and located at the labial-gingival frenulum, the base of the lingual dorsum, soft palate, and the sides of the tongue (Fig 1 a & b). The affected tissues bled easily on palpation. Brown, fuzzy material containing plant awns mixed with saliva adhered to the incisors at the gingival margin. The awns were embedded in the tissue perpendicular to the surface. Samples of the plant material from the gums were scraped onto slides for microscopic examination. In addition, samples of alfalfa hay were obtained and high contamination of alfalfa hay to *Hordeum murinum* was identified by The Herbarium Center of the Ferdowsi University of Mashhad (Fig 2 a & b). Blood samples were collected by jugular venepuncture from 12 affected horses. Results of a complete blood count were not remarkable (table 1). Microscopic examination of samples removed from the lesions revealed awns from the *Hordeum murinum*. By removal of the contaminated food, and treating oral lesions, the ulcers began to heal slowly over the course of next three weeks.

Discussion

Oral ulcers and erosions are often attributed to physical trauma induced by coarse forage or plant awns. There are few reports of grass awn-associated stomatitis in horses, and some reports are anecdotal (Turnquist et al., 2001). Two reported outbreaks in horses incriminated

yellow bristle grass (*Setaria lutescens*), and a third outbreak in horses has been caused by triticale hay (Bankowski et al., 1956; Linnabary et al., 1986). In this report, for the first time we report an outbreak of ulcerative stomatitis in horse due to *Hordeum murinum* seed heads. In many cases of ulcerative or erosive stomatitis, an offending awn or other parts of the plant may not be detected. Examination of forage available to the horse with erosive stomatitis should be conducted to identify potential irritants (McCosker and Keenan, 1983; Peterson and Schultheiss, 1984; Turnquist et al., 2001; Radostits et al., 2007). *Hordeum murinum* (mouse barley) is a common grass in the northeastern regions of Iran, and where else it is found in abundance it may cause forms of a traumatic stomatitis which is needed to be differentially diagnosed from other forms of stomatitis. Based on the results of haematological analysis and epidemiologic investigation, the possibility of infectious (e.g. vesicular stomatitis) and non infectious diseases (e.g. in cases with uremia) that are also able to cause dramatic lesions in mouth was ruled out. Demonstration of plant awns in the lesions and in hay samples, as well as resolution of the lesions after removal of the hay from the horses' diet, confirmed the diagnosis.

References

- Ammari, F. F., K. T. Faris, and T. M. Mahafza. 2000. Inhalation of wild barley into the airways: two different outcomes. *Saudi Med J*. 2:468-470.
- Aslani, M. R. 2002. Various physical injuries and complications due to *Hordeum murinum* in sheep and cattle. *World Veterinary Congress 27th*, Tunis, Tunisia.
- Bankowski, R. A., R. W. Wichmann, and E. E. Stuart. 1956. Stomatitis of cattle and horses due to yellow bristle grass (*Setaria lutescens*). *J Am Vet Med Assoc*. 129:149-152.
- Brennan, K. E. and P. J. Ihrke. 1983. Grass awn migration in dogs and cats: a retrospective study of 182 cases. *J Am Vet Med Assoc*. 182:1201-1204.
- Duff, S. and D. McGahie. 2001. Mouth ulcers in horses. *Vet Rec* 149:431.
- Gehlen, H., P. Stadler, J. Zentek, and E. Deegen. 1999. Ulcerative stomatitis in a horse: *Tierarztliche Praxis. Ausgabe G, Grosstiere/Nutztiere* 27:256-257 285-287.
- Jones, T. C., R. D. Hunt, and N. W. King. 1997. Traumatic lesions. Page 1043 in *Veterinary pathology*. William & Wilkins Company.
- Koutinas, C. K., L. G. Papazoglou, M. N. Saridomichelakis, A. F. Koutinas, and M. N. Patsikas. 2003. Caudal mediastinal abscess due to a grass awn (*Hordeum* spp) in a cat *J. Feline Med. Surg* 5:43-46.
- Linnabary, R. D., J. E. Henton, J. P. Held, and R. D. Black. 1986. Oral ulcerations in a horse caused by grass awns. *Journal of Equine Veterinary Science* 6:20-22.
- McCluskey, B. J. and E. L. Mumford. 2000. Vesicular stomatitis and other vesicular, erosive, and ulcerative diseases of horses. *Vet Clin North Am Equine Pract*. 16:457-469.
- McCosker, J. E. and D. M. Keenan. 1983. Ulcerative stomatitis in horses and cattle caused by triticale hay *Aust Vet J*. 60:259.
- Peterson, D. E. and P. C. Schulte's. 1984. Ulcerative stomatitis in horses due to ingestion of hay containing plant awns *Vet Med Small Anim Clin*. 79:1509-1512.

- Radostitis, O. M., G. C. C., D. C. Blood, and K. W. Hinchcliff. 2007. Plant materials causing physical damage *in* veterinary medicine. A textbook of the diseases of cattle, sheep, pigs, goats and horses. W. B. Saunders Company.
- Turnquist, S. E., E. N. Ostlund, J. M. Kreeger, and J. R. Turk 2001. Foxtail-induced ulcerative stomatitis outbreak in a Missouri stable J Vet Diagn Invest. 13:238-240.
- Ya-nong, G. 1981. Oral injuries and fistulae of the head in horses caused by millet awns in Inner Mongolia. Chinese Journal of Veterinary Medicine. 7:13-16.

شیوع تورم دهانی اولسراتیو در اسب ناشی از هوردئوم مورینوم

غلامرضا محمدی^۱، کامران سرداری^۱

^۱ گروه علوم در مانگاهی، دانشکده دامپزشکی دانشگاه فردوسی مشهد، مشهد، ایران

دریافت مقاله: ۸۷/۱۲/۲۵ پذیرش نهایی: ۸۸/۳/۲۵

چکیده

التهاب مخاط دهان و لثه در ۲۶ راس از ۹۶ راس اسب در یک آموزشگاه سوارکاری در مشهد، ایران تشخیص داده شد. معاینه درمانگاهی اسب‌های مبتلا درجات مختلفی از زخم در حد فاصل لثه و دندان حاوی داسه‌های متعدد (نوک بذر) را آشکار ساخت. زخم‌های دردناک با اندازه بیش از ۵ سانتی متر در محل اتصال لب به لثه، لگام زبان، قاعده پستی زبان، کام نرم و سطوح جانبی زبان قرار داشتند. بررسی غذای حیوانات مبتلا آلودگی یونجه با نوک بذر هوردئوم مورینوم را نشان داد. پس از حذف یونجه آلوده از جیره غذایی، زخم‌ها به تدریج و پس از ۳ هفته التیام یافتند.

واژه‌های کلیدی: شیوع، تورم دهانی اولسراتیو، اسب، هوردئوم مورینوم