



## Histopathologic aspects of pancreatic islet cell tumor in a dog

Javad Khoshnegah,<sup>a</sup> Hossein Nourani,<sup>b</sup> Ali Mirshahi<sup>a</sup>

<sup>a</sup> Department of Clinical Sciences, Faculty of Veterinary Medicine, Ferdowsi University of Mashhad, Mashhad, Iran.

<sup>b</sup> Department of Pathobiology, Faculty of Veterinary Medicine, Ferdowsi University of Mashhad, Mashhad, Iran.

### ABSTRACT

A 12-year-old 4.3 kg intact female Terrier presented with a history of lethargy, anorexia, and melena for one month. The animal was dull and depressed. Dermatologic examination revealed some focal erythematous, crusty, and papulopustular lesions over the ventral abdomen. Ultrasonographic evaluation displayed an abnormal parenchymal pattern of the liver, which was noticed in the cranial part of the abdomen with diffuse hepatic involvement with irregular, hypoechoic, and heterogeneous ill-defined areas [a honeycomb-like echotexture]. Lateral thoracocervical radiograph showed numerous well-defined, small lytic lesions [polyostotic punched-out lesions] in the dorsal spinous process of axis bone in C2-C5 and pelvis that were likely metastatic lesions. Despite hospitalization and treatment, the dog died after 2 weeks and a necropsy was performed. At postmortem examination, a 5-cm mass was observed in the pancreas adjacent to duodenal loops which was finally diagnosed as a pancreatic tumor. Abnormal laboratory findings included elevated blood urea nitrogen, creatinine, cholesterol, total bilirubin, aspartate aminotransferase, alkaline phosphatase, gamma-glutamyltranspeptidase, and calcium. Histopathological examination of the affected pancreas revealed neoplastic cells which were arranged mainly as solid nests or clusters and the amounts of the tumor stroma among the cellular clusters or individual neoplastic cells were scant. According to an immunohistochemical study which was positive for chromogranin A, the condition was diagnosed as a pancreatic islet cell tumor. Although rare, pancreatic islet tumors should be included in the differential diagnosis of abdominal discomforts, pancreatic inflammation, and hepatopathies. The final diagnosis of the tumor is achieved by combining imaging techniques and advanced histopathologic evaluations.

### Keywords

*Tumor, Pancreatic islet cell tumor, Histopathology, Immunohistochemistry, Dog*

### Abbreviations

C2-C5: Cervical vertebrae  
GI: Gastrointestinal

Number of Figures: 2  
Number of Tables: 2  
Number of References: 12  
Number of Pages: 5

## Introduction

Pancreatic endocrine tumors have been reported in various species including humans, dogs, cats, and ferrets [1]. In order to diagnose pancreatic endocrine tumors, the pathologist should confirm the neuroendocrine nature of the tumor cells. These tumors have various microscopic results, and immunohistochemical staining with different kinds of markers like chromogranin A, synaptophysin, and neuron-specific enolase, can usually confirm the neuroendocrine origin [2]. It can be difficult to accurately evaluate the degree of malignancy of pancreatic endocrine tumors but other features of the tumors, including local invasion and metastases to lymph nodes and distant organs, are helpful to explain their malignant nature [3]. There are different commonly recognized pancreatic endocrine tumors like gastrinomas, insulinomas, glucagonomas, and somatostatinomas. Although these different types of pancreatic endocrine tumors share some clinical features and histological aspects, they differ in their pathogenesis, hormonal syndromes produced, many aspects of biological behavior, and most importantly, in their response to chemotherapy and/or molecular targeted therapies. Here, we presented the histopathological appearance of a pancreatic islet cell tumor in an old Terrier dog. To the best of our knowledge, this is the first report of pancreatic tumors in Iran.

## Case Presentation

A 12-year-old female Terrier dog weighing 4.3 Kg was presented to the Ferdowsi University of Mashhad Veterinary Teaching Hospital with a history of lethargy, anorexia, and melena for approximately one month. On physical examination, the animal was dull and depressed with a normal body condition score. Dermatologic examination revealed some focal erythematous, crusty, and papulopustular lesions over the ventral view of the abdomen. Differential diagnoses included endocrinopathies and malignancies. Complete blood count showed 1 % nucleated red blood cells and lymphopenia (520; Reference 1000-4800). Serum biochemistry revealed elevated blood urea nitrogen (88; Reference 10-28), creatinine (3.19; Reference 0.5-1.5), cholesterol (286; Reference 135-270), total bilirubin (0.43; Reference 0.1-0.4), aspartate aminotransferase (471; Reference 23-66), alkaline phosphatase (6470; Reference 20-156), gamma-glutamyltranspeptidase (45.5; Reference 1.2-6.4) and calcium (12.40; Reference 9-11.3). Other parameters, including C-reactive protein, were within normal ranges (Table 1, and 2).

Diagnostic imaging evaluations consisted of ultrasonography and radiology. Abdominal ultrasonogra-

phy was performed with a 7.5 MHz linear transducer (Mindray, 6600 vets, China). The abnormal parenchymal pattern of the liver was noticed in the cranial part of the abdomen (Figure 1a). Diffuse hepatic involvement with irregular, hypoechoic, and heterogeneous ill-defined areas (a honeycomb-like echotexture) was observed that may be due to metastatic lesions or primary neoplasia. Lateral thoracocervical radiograph showed numerous well-defined, small lytic lesions (polyostotic punched-out lesions) in the dorsal spinous process of axis bone in C2-C5 and pelvis that are likely metastatic lesions (Figure 1b).

Characteristic ultrasound features of the evenly distributed hypoechoic nodular pattern, reflecting the neoplastic cells in the liver, which were consistent with the typical honeycomb pattern of superficial necrolytic dermatitis. Pancreatic mass was not detected by ultrasonography but later at necropsy, a mass was detected.

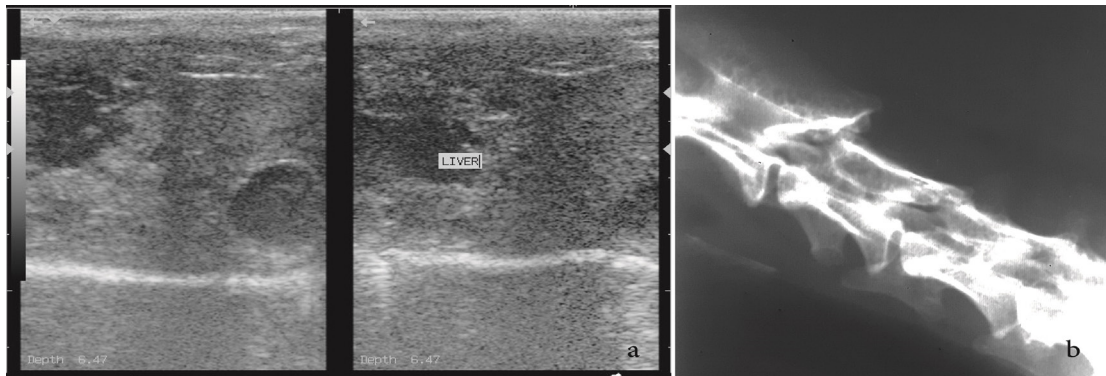
In spite of hospitalization and supportive treatment, the dog died after 2 weeks, and a necropsy was performed. At postmortem examination of the case, a 5 cm mass was observed in the pancreas adjacent to duodenal loops, which was finally diagnosed as a pancreatic tumor. The Liver was diffusely pale and had rounded margins and hepatomegaly was another prominent finding. Histopathological samples were taken from the liver and the suspected unknown mass

**Table 1.**  
Haematological findings

Hematologic findings	patient	Reference values <sup>a</sup>
Hematocrit (%)	39	36-60
Hemoglobin (g/dl)	12.2	12.1-20.3
Red Blood Cell ( $\times 10^6/\mu\text{l}$ )	6.3	4.8-9.3
MCV (fl)	63	58-79
MCH (pg)	28	19-28
MCHC (g/dl)	37	30-38
Platelets ( $\times 10^3/\mu\text{l}$ )	225	170-400
White blood cells ( $\times 10^3/\mu\text{l}$ )	11050	6.02-16.02
Mature neutrophils ( $\times 10^3/\mu\text{l}$ )	9750	2060-10600
Band neutrophils ( $\times 10^3/\mu\text{l}$ )	0	0-300
Lymphocytes ( $\times 10^3/\mu\text{l}$ )	550	690-4500
Monocytes ( $\times 10^3/\mu\text{l}$ )	100	0-840
Eosinophils ( $\times 10^3/\mu\text{l}$ )	650	0-1200
Basophils ( $\times 10^3/\mu\text{l}$ )	0	0-150

James K. Klaassen, Reference Values in Veterinary Medicine LABORATORY MEDICINE VOLUME 30, NUMBER 3 MARCH 1999

## Pancreatic islet cell tumor in a dog

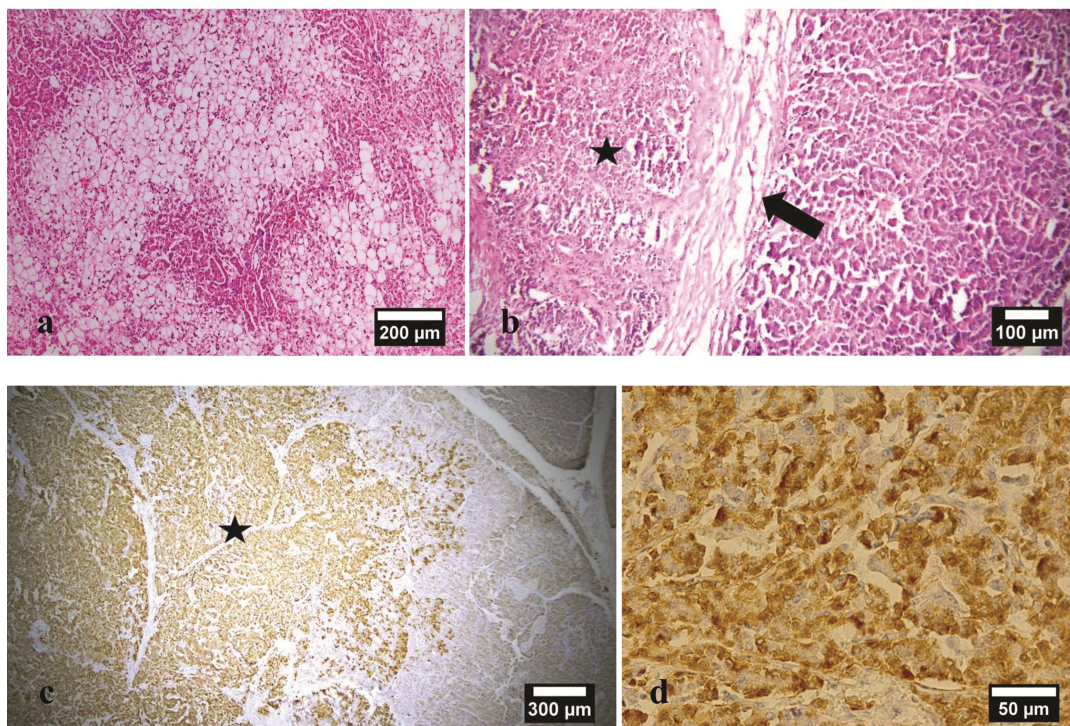


**Fig 1.**

(a) Sagittal images of liver ultrasonography showed diffuse hepatic involvement with irregular, hypoechoic and heterogeneous ill-defined areas. (b) Lateral cervical radiograph showed numerous well-defined, small lytic lesions [punched-out lesions] in the dorsal spinous process of C2.

in the pancreas and then, then fixed in 10% formalin before being embedded in paraffin. Some sections of the mass were used for immunohistochemical study for chromogranin A detection [4]. Histopathological examination of the liver revealed a severe and diffuse vacuolar change of hepatocytes. Most of the affected hepatocytes had clear and swollen cytoplasm (Figure 2a). In the affected pancreas, neoplastic cells were arranged mainly as solid nests or clusters, and the amounts of the tumor stroma among the cellular clus-

ters or individual neoplastic cells were scant. Prominent and hyalinized collagenous connective tissue was observed between the neoplastic region and normal exocrine acini, and also in some parts of the tumor that formed a few separated microscopic areas within the tumor. An immunohistochemical study showed that the neoplastic cells were positive for chromogranin A (Figure 2b-2d). Based on postmortem, histopathological, and immunohistochemical findings, the condition was diagnosed as pancreatic islet cell tumor.



**Fig 2.**

(a) Severe vacuolar change of the hepatocytes in the affected case. (b) The neoplastic region [asterisk] is separated from the exocrine pancreatic tissue by a connective tissue capsule. (c) Immunohistochemical staining is positive for chromogranin A in the neoplastic area [asterisk]. (d) Higher magnification of the positive neoplastic cells for chromogranin A.

**Table 2.**  
Serum biochemistry results

Biochemistry findings	patient	Reference values <sup>a</sup>
Total protein (g/dl)	7.5	5-7.4
Albumin (g/dl)	3.1	2.7-4.4
BUN (mg/dl)	88	4-27
Creatinine (mg/dl)	3.19	0.5-1.6
Glucose (mg/dl)	135	70-138
Cholestrol (mg/dl)	286	92-328
Bilirubin Total (mg/dl)	0.43	0.1-0.3
Alkaline phosphatase (IU/L)	6470	5-131
Alanine aminotransferase (IU/L)	156	12-118
Aspartate aminotransferase (IU/L)	471	15-66
Gamma-glutamyltranspeptidase	45.5	1.2-6.4
Calcium	12.4	9-11.3
Creatinine kinase (IU/L)	78	59-895

## Result & Discussion

The islet cell tumors are immunohistochemically reactive to multiple hormones and can secrete different kinds of hormones including insulin, glucagon, somatostatin, pancreatic polypeptide, and gastrin, either singly or in combination [5].

Our case was a dog who presented with concurrent skin lesions, hepatic failure, and lytic bone involvement. The skin lesions are caused by degeneration of keratinocytes, resulting in epidermal edema and necrosis [6]. The precise mechanism underlying the development of skin disease in islet cell tumors remains unknown, but one of the proposed mechanisms is the occurrence of hypoaminoacidaemia, which may induce keratinocyte necrosis through epidermal protein deficiency [7]. Unfortunately, we were not able to take a skin biopsy sample during the examination and necropsy of delayed diagnosis of the tumor (missing data). Although not confirmed histopathologically, the presentation of the skin lesions in the present case resembles typical skin lesions of superficial necrolytic dermatitis [6, 8].

With pancreatic tumors, the signs can be vague or nonspecific (10); signs may include loss of appetite, vomiting, watery diarrhea, lethargy, pain in the abdomen, and weight loss. If the tumor has metastasized such as the bones, the clinician may notice lameness. Most of the affected dogs also have non-regenerative anemia, mild hyperglycemia, increased

serum liver enzyme activities, and a honeycomb-appearing liver on abdominal ultrasonography. [6, 8]. The dog presented here had a history of lethargy, anorexia, and melena for approximately one month. These unremarkable signs might be due to concurrent pancreatitis, inflammation of the GI tract, and/or cholangiohepatitis.

Laboratory abnormalities observed in the present case indicate severe hepatocellular dysfunction. A wide variety of reasons, including, for instance, metastasis of pancreatic tumor, concurrent GI disease, and/or cholangiohepatitis reported as reasons for these abnormal findings.

Bone lesions in the present case, might be due to metastatic invasion of the tumor, which was not confirmed histopathologically. Skeletal metastases including both osteolytic and osteoblastic lesions have been described. In people, a prevalence range of 5 to 20 percent of these lesions has been reported [9]. Most patients have widely metastatic disease at the time of diagnosis.

As emphasized in the present study, immunohistochemistry has become an essential ancillary examination for the identification and classification of these kinds of tumors. In the present case, the neoplastic cells were positive for chromogranin A, which is specific to endocrine cells. Chromogranin A, due to its primary expression throughout the neuroendocrine system, is a widely accepted biomarker for the assessment of neuroendocrine tumors [11].

Many authors believe that the prognosis of islet cell tumors is grave, although surgical removal of a pancreatic tumor may be curative in the unlikely scenario that metastasis has not occurred [11]. Clinicians should be aware of the uncommon early manifestations of islet cell tumors. Early diagnosis allows complete surgical removal of the neoplasm and provides the only chance of a cure. Additional case studies are needed to further characterize the cytomorphologic features and clinical presentation of pancreatic islet cell tumors in dogs.

## Authors' Contributions

MJavad Khoshnegah: Supervision, Conceptualization, Visualization, Resources, Writing- Reviewing and Editing.

Hossein Nourani: Methodology, Investigation, Writing- Reviewing and Editing.

Ali Mirshahi: Methodology, Investigation, Validation

## Acknowledgements

No acknowledgements.

## Competing Interests

The authors declare that there is no conflict of interest.

## References

- Goutal MC, Brugmann BL, Ryan KA. Insulinoma in Dogs: A Review. *Journal of the American Animal Hospital Association*. 2012; 48: 151–63. Doi:10.5326/JAAHA-MS-5745.
- Duan K, and Mete O. Algorithmic approach to neuroendocrine tumors in targeted biopsies: Practical applications of immunohistochemical markers. *Cancer Cytopathology*. 2016; 124: 871-84. Doi: 10.1002/cncy.21765.
- Halfdanarson TR, Rubin J, Farnell MB, Grant CS, Petersen GM. Pancreatic endocrine neoplasms: Epidemiology and prognosis of pancreatic endocrine tumors. *Endocrine-Related Cancer*. 2008; 15: 409–27. Doi:10.1677/ERC-07-0221.
- Finotello R, Marchetti V, Nesi G, Arvigo M, Baroni G, Vannozzi I, Minuto F. Pancreatic islet cell tumor secreting insulin-like growth factor type-II in a dog. *Journal of Veterinary Internal Medicine*. 2009; 23: 1289–92. Doi:10.1111/j.1939-1676.2009.0387.x.
- Tetsuhidem I, Igarashim H, Jensenm RT. Pancreatic neuroendocrine tumors: clinical features, diagnosis, and medical treatment: advances. *Best Practice & Research: Clinical Gastroenterology*. 2012; 26: 737–53. Doi:10.1016/j.bpg.2012.12.003.
- Miller WH, Griffin CE, Campbell KL. Muller and Kirk's Small Animal Dermatology, 7th ed. 2013; 540-2.
- Mizuno T, Hiraoka H, Yoshioka C, Takeda Y, Matsukane Y, Shimoyama N, Morimoto M, Hayashi T, Okuda M. Superficial necrolytic dermatitis associated with extrapancreatic glucagonoma in a dog. *Veterinary Dermatology*. 2009 20 (1): 72-9. Doi:10.1111/j.1365-3164.2008.00729.x.
- Gross TL, Song, MD, Havel PJ, Ihrke PJ. Superficial necrolytic dermatitis (necrolytic migratory erythema) in dogs. *Veterinary Pathology*. 1993; 30, 75-81. Doi:10.1177/030098589303000110.
- Borad MJ, Saadati H, Lakshmi A, Campbell E, Hopper P, Jameson G, Von Hoff DD, Saifc MW. Skeletal metastases in pancreatic cancer: A retrospective study and review of the literature. *Yale Journal of Biology and Medicine*. 2009; 82: 1–6.
- Cruz Cardona JA, Wamsley HL, Farina LL, Kiupel M. Metastatic pancreatic polypeptide-secreting islet cell tumor in a dog. *Veterinary Clinical Pathology*. 2010; 39(3): 371-6. Doi:10.1111/j.1939-165X.2010.00243.x.
- Bennett PF, Hahn KA, Toal RL, Legendre AM. Ultrasonographic and cytopathological diagnosis of exocrine pancreatic carcinoma in the dog and cat. *Journal of the American Animal Hospital Association*. 2001; 37: 466-73. Doi:10.5326/15473317-37-5-466.
- Gkolfinopoulos S, Tsapakidis K, Papadimitriou K, Papamichael D, Kountourakis P. Chromogranin A as a valid marker in oncology: Clinical application or false hopes? *World Journal of Methodology*. 2017; 7(1): 9–15. Doi:10.5662/wjm.v7.i1.9.

### COPYRIGHTS

©2024 The author(s). This is an open access article distributed under the terms of the Creative Commons Attribution (CC BY 4.0), which permits unrestricted use, distribution, and reproduction in any medium, as long as the original authors and source are cited. No permission is required from the authors or the publishers.



### How to cite this article

Khoshnegah J, Nourani H, Mirshahi A. Histopathologic aspects of pancreatic islet cell tumor in a dog. *Iran J Vet Sci Technol*. 2024; 16(2): 57-61.

DOI: <https://doi.org/10.22067/ijvst.2024.85261.1323>

URL: [https://ijvst.um.ac.ir/article\\_45188.html](https://ijvst.um.ac.ir/article_45188.html)