



Recovery effects of pomegranate seed powder on the testes following cadmium poisoning in Japanese quail (*Coturnix japonica*); a stereological and lipid peroxidation study

Rahmat Allah Fatahian Dehkordi,^a Shahab Bahadoran,^b Mohammadreza Alijani,^c
Abdollahnaser Mohebi,^b Hanie Mohammadi^c

^a Department of Basic Sciences, Faculty of Veterinary Medicine, University of Shahrekord, Shahrekord, Iran.

^b Department of Clinical Sciences, Faculty of Veterinary Medicine, University of Shahrekord, Shahrekord, Iran.

^c DVM Student, Faculty of Veterinary Medicine, Shahrekord University, Shahrekord, Iran.

ABSTRACT

This study aimed to investigate the effects of pomegranate seed powder on cadmium-poisoned testicular tissue in Japanese quail. A total of 270 day-old Japanese quail chicks were assigned to six treatment groups, control group, cadmium 50 ppm (group II), pomegranate seed powder (1 and 0.5 %; groups III and IV, respectively), pomegranate seed powder 1% + Cd 50 ppm (group V), pomegranate seed powder 0.5% + Cd 50 ppm (group VI). Stereological parameters in testes and TBARS, cholesterol, and triglyceride levels were determined. Testicular components showed a significant reduction in area surface and volume density in the cadmium-exposed groups compared with controls ($p < 0.05$). It was found that in the cadmium induction group, TBARS, cholesterol, and triglyceride levels were significantly higher compared to the normal level ($p < 0.05$). The results showed that pomegranate seed powder could increase the area surface and volume density of testicular germinal ingredients and decrease the content of TBARS, cholesterol, and triglyceride ($p > 0.05$) in cadmium poisoning testis. These results show that cadmium has destructive effects and pomegranate seed powder has prevented the development of these effects on stereological and lipid parameters.

Keywords

Japanese quail, Pomegranate seed powder, Stereology, TBARS, Histology

Number of Figures: 2
Number of Tables: 1
Number of References: 29
Number of Pages: 6

Abbreviations

TBARS: Thiobarbituric acid reactive substances
Cd: Cadmium
H&E: Hematoxylin and eosin
ANOVA: Analysis of variance
Spem: Spermatogonia

Spem-1: Primary spermatocyte
Spet: Spermatid

Cadmium is a natural heavy metal that in its industrial form, depending on its dosage, causes poisoning in humans and animals [1]. It has been reported that cadmium inflicts damage on the reproductive system of birds that can occur either experimentally [2] or by being environmentally exposed to this heavy metal [3]. Given that 1 to 2% of the acute dose of cadmium is taken up by the testes [4], however, the damage to the process of spermatogenesis is very severe [5]. Low doses of cadmium alter the immunological microenvironment in the testicles, which results in increased testicular autoimmunity [6]. Testicular poisoning with cadmium is caused by complex intra-network reactions, including the destruction of the blood testicular barrier or inhibition of oxidative stress leading to germ cell apoptosis, edema, and intra-testicular bleeding [7-9].

Pomegranate (*Punica granatum*) fruit, juice, seed, and peel due to a high content of polyphenols, especially ellagitannins, tannins, and anthocyanins have high antioxidant capacities [10]. Consumption of pomegranate extract significantly increases the sperm quality, density of the spermatogenic cell, antioxidant activity, and testosterone levels in male rats [11]. It has also been shown that pomegranate contains hydrolyzed and concentrated tannins that exhibit anti-cancer properties in vitro and in vivo [12, 13].

Qualitative patterns, including atrophy, hypoplasia, hyperplasia, and or hypertrophy can be stated by stereological methods through measurable and comparative data [14]. However, the impact of various situations on the process of spermatogenesis and or survival of the germ cell line requires simple methods and quantification. This study aimed to determine the protective effects of pomegranate seed powder against the toxic effects of Cd in quail using biochemical and histo-stereological methods. All the chemicals and reagents used in this study were of molecular biology grade and were purchased from Sigma-Aldrich Co. Ripe pomegranates are purchased from the local market and after separating the skin, seeds (protein, 13.6; fat, 29.6, fiber, 39.3) were washed with water and after drying, seeds were powdered using a hammer mill and sieved through a 40-mesh sieve [15]. All protocols used in this experiment were approved by the Institutional Animal Care and Use Committee of Shahrekord University. Two hundred and seventy-one-day-old unsexed quail (Japanese) chicks were used in this study. The birds were fed by the standard basic diet until the 7th day of age (one week, habituation) before starting the experiment. All diets were formulated to meet the nutrient requirements of the Japanese quails. On day 7, the birds were randomly assigned to six treatments, with three replicates (cages) of fifteen quails each.

Group I: received basic diet and ordinary water. Group II: received a basic diet and 50 ppm cadmium orally. Group III: birds were fed with a basic diet + 1% pomegranate seed powder. Group IV: birds were fed with a basic diet + 0.5% pomegranate seed powder. Group V: received a basic diet along with 1% pomegranate seed powder and 50 ppm cadmium. Group VI: received basic diet along with 0.5% pomegranate seed powder and 50 ppm cadmium.

Blood samples were centrifuged at 1500 rpm for 15 minutes and TBARS, cholesterol, and triglyceride in serum samples were measured. Testes specimens fixed in Merck formalin and processed through paraffin embedding, cut into 5 μ m sections, stained with hematoxylin and eosin (H&E) techniques for stereological evaluation.

Stereology

By the count of all point, the total area determined (Figure 1), and finally the volume was estimated by:

$$V = k \times t \times a(p) \times \sum^p(\text{testis})$$

In which \sum^p is total area, k is kth section is mounted on a glass slide, $a(p)$ is the area of each point.

The volume of the seminiferous tubules, the inter-tubular tissues, and the germinal epithelium was estimated [16] by:

$$V_{\text{V(structur/ref)}} = P_{\text{(structure)}} / P_{\text{(total)}}$$

In which $P_{\text{(structure)}}$ and $P_{\text{(total)}}$ represent respectively, the total numbers of points hitting the structures of interest, and the reference space $V_{\text{(ref)}}$ and summed over all sections and fields from one testis.

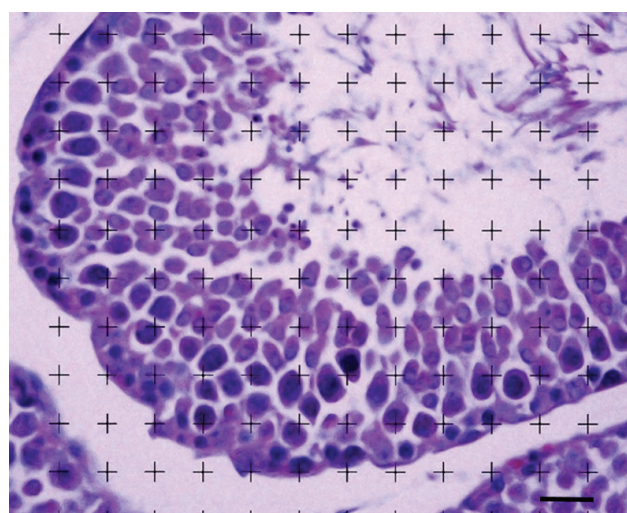


Figure 1. Photomicrograph of testis in quail. Point-counting method was used to evaluate stereological parameters. The area surface and volume density of the spermatogonia, primary spermatocyte, and spermatid were determined by calculation of the points hitting with the micrograph; (scale bar=20 μ m).

$$V_{(structure)} = V_{V(structure/testis)} \times V_{final}(\text{mm}^3)$$

The total volume was obtained by multiplying the density by the final testis volume [16].

Biochemical analysis

TBARS was determined calorimetrically using the method of Buege and Aust (1978), briefly, 0.1 mL of serum was treated with 2 mL of TBA-TCA-HCl reagent, and absorbance of the supernatant was measured against reference blank at 535 nm. Concentrations were calculated using an extinction coefficient of $1.569 \times 10^5 \text{ mol}^{-1} \text{ L cm}^{-1}$ and expressed as nmol mL^{-1} [17]. Blood biochemical parameters including triglyceride and cholesterol were measured by commercial kits of Pars Azmoun Company and according to the protocols of this company. Data were analyzed by one-way analysis of variance (ANOVA) using the SPSS V. 23/0 software (SPSS Inc., Chicago, IL). The means were considered significantly different at $p < 0.05$.

The Vv (spem/tes) (Table 1) was significantly decreased in the cadmium-exposed group compared to the control group ($p < 0.05$). In addition, the Vv (spem-1/tes) showed a significant decrease in groups that received cadmium compare to the control group ($p < 0.05$). The Vv (spet/tes) also were significantly decreased in the group exposed to the cadmium compared to the control groups ($p < 0.05$). Nevertheless, the administration of pomegranate seed powder (1 and 0.5%) along with cadmium (50ppm, V and VI groups) inverted the mean of all stereological volumetric parameters to near normal. But these differences between V and VI groups with the control group were not statistically significant ($p > 0.05$).

The area surface (Table 1) in all stereological parameters of spermatogonia, primary spermatocytes, and spermatids was decreased in the cadmium groups

compared to the control birds ($p < 0.05$). Following a similar pattern of volume density, pomegranate seed powder (1 and 0.5%) reversed the area surface of the measured parameters mentioned non-significantly toward normal in cadmium-exposed quails (V and VI groups; $p > 0.05$).

The mean TBARS level (Figure 2 and Table 2) of the control group (group I) compared with those of the other groups had no significant difference in this study except for the cadmium group (group II). Nevertheless, a significant increase had happened in the cadmium group (32.27 ± 4.32) in comparison with the TBARS level of the control group (20.3 ± 3.21 ; $p < 0.05$). On the other hand, pomegranate seed powder (1 and 0.5%) was able to bring the level of TBARS in cadmium poisoned quail closer to the control group, although this reduction was not significant ($p > 0.05$).

It should be noted that there was a significant increase in the cholesterol and triglyceride values (Table 2) of the cadmium group (181.41 ± 7.28 and 277.08 ± 86.16 respectively) compared with those of the control group (148.99 ± 25.07 and 194.78 ± 7.49 respectively; $p < 0.05$). Pomegranate seed powder (1 and 0.5%) groups (groups V and VI) showed a decrease in cholesterol and triglyceride values in cadmium-poisoned birds' groups, although this decrease was non-significant ($p > 0.05$). Therefore, the administration of pomegranate seed powder in two different doses ($p > 0.05$) reversed the levels of cholesterol and triglyceride to near normal in cadmium-exposed birds.

This study showed that the volume density of spermatogonia, primary spermatocyte, and spermatid affected by cadmium administration in a dose of 50 ppm. Meanwhile, similar changes were observed regarding the area surface of structural components mentioned in the face of cadmium. As the results showed, a significant decrease was seen in area sur-

Table 1.

Effect of pomegranate on stereological parameters in the testes of cadmium-exposed birds

		Area surface			Volume density		
		spem	spem-1	spet	spem	spem-1	spet
I	Control	0.16 ± .07 ^a	0.21 ± 0.10 ^a	0.17 ± .04 ^a	0.25±0.13 ^a	0.43 ±.17 ^a	0.25 ± 0.13 ^a
II	Cd	0.07 ± .04 ^b	0.12 ± .05 ^b	0.10 ±.06 ^b	0.10±.04 ^b	0.23 ±.19 ^b	0.10 ±.04 ^b
III	Pome. 1%	0.13 ± .03	0.23 ± .06	0.17 ±.06	0.28±.13	0.50 ±.26	0.28 ±.13
IV	Pome. 0.5%	0.13 ± .06	0.23 ± .07	0.20 ±.07	0.24±.19	0.50 ±.25	0.24 ±.19
V	Pome. 1% + Cd	0.12 ± .03	0.21 ± .08	0.14 ±.04	0.22±.13	0.41 ±.17	0.22 ±.13
VI	Pome. 0.5% + Cd	0.12 ±.02	0.20 ± .07	0.14 ±.07	0.21±.12	0.41 ±.18	0.21 ±.12

^{a, b} Significant difference compared with controls in each column at $p < 0.05$; Spem: spermatogonia, Spem-1: primary spermatocytes, Spet: spermatid.

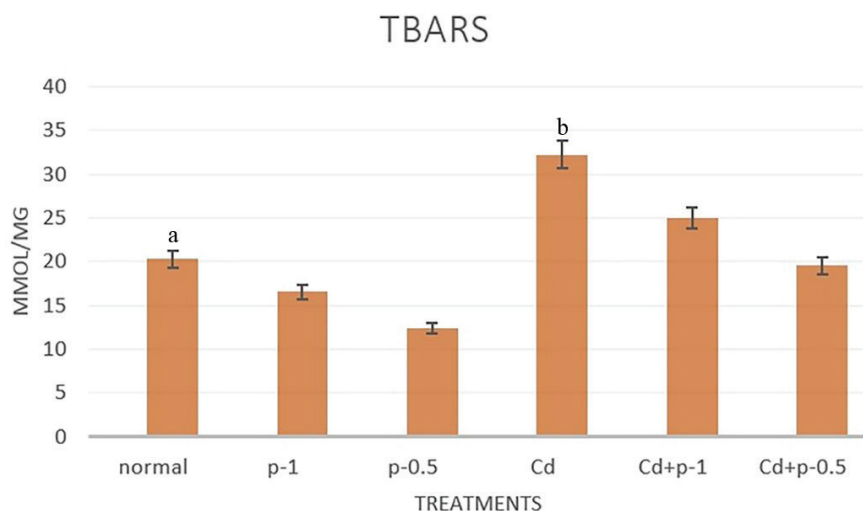


Figure 2. Effect of pomegranate on TBARS levels of testes of cadmium-exposed birds. Groups: normal (control), p-1 (pomegranate 1%), p-0.5 (pomegranate 0.5%), Cd (cadmium), Cd+p-1 (cadmium+ pomegranate 1%), Cd+p-0.5 (cadmium+ pomegranate 0.5%); Dissimilar letters indicate significant differences.

face and volume density in the cadmium-treated birds in comparison with those of the control group. In agreement with our findings, Blanco et al. displayed a significant decreasing in the volume density of the testicular structure and decreasing tubular densities and epithelial percentages in the animals that were exposed to cadmium [18]. Adamkovicova et al. showed that the decrease in the epithelial layer volume of the seminiferous tubules in the face of cadmium can be due to the penetration of cells into the lumen leading to lumen shrinkage and a significant decrease in the percentage of epithelial volume fraction [19]. Therefore, we infer that a decrease in the volume density of measured parameters in our study could be another reason for the reduction of the epithelium layer volume in Adamkovicova's research. Numerous studies have shown that alteration in quantitative parameters, similar to measured parameters of this study, is related to toxic effects of cadmium which can result in the miss of germination epithelium [20, 21].

The results of this study show that no significant

differences were observed between the control group and the pomegranate seed powder group in all the evaluated parameters. The results of this study also revealed that the area surface and the volume density of spermatogonia, primary spermatocyte, and spermatid were increased in groups V and VI compared to the cadmium group.

Cadmium exposure for 35 days caused higher TBARS, cholesterol, and triglyceride values in the serum of exposed birds to cadmium in the comparison control group. These are according to other findings that cadmium produces exceeding amounts of reactive oxygen species (ROS), which leads to oxidative stress damage and causes of injury and disease expansion [9, 22-26]. An increment in TBARS capacity was considered as a sign of oxidative damage [27, 28]. The present study showed that TBARS value in group II increases than control, but in groups V and VI, the TBARS value was at a low level compared with group II. Therefore, oral administration of pomegranate seed powder (both 1 and 0.5%) to cadmium treated

quails non-significantly ($p > 0.05$) decreased the altitude of TBARS when compared to the group treated with cadmium alone. Administration of pomegranate seed powder reversed the concentration of TBARS in cadmium exposed birds; such that, this shift caused the amount of TBARS value to deviate to the normal level, although these changes were not significant. Like TBARS, similar results were obtained in the cholesterol and triglyceride levels. It was observed that the levels of cholesterol and

Table 2. Effect of pomegranate on biochemical parameters in the serum of cadmium-exposed birds

Groups		parameters		
		TBARS mmol/mg	Cholesterol mg/d	Triglyceride mg/d
I	Control	20.30 ± 3.21 ^a	148.99 ± 25.07 ^a	194.78 ± 7.49 ^a
II	Cd	32.27 ± 4.32 ^b	181.41 ± 7.28 ^b	277.08 ± 86.16 ^b
III	Pome. 1%	16.57 ± 2.17	139.36 ± 17.45	152.37 ± 21.16
IV	Pome. 0.5%	12.35 ± 2.01	123.32 ± 15.37	142.10 ± 15.42
V	Pome. 1% + Cd	25.00 ± 2.64	153.78 ± 24.26	224.34 ± 24.61
VI	Pome. 0.5% + Cd	19.58 ± 2.85	168.95 ± 16.56	208.27 ± 28.14

^{a,b} Significant difference compared with controls in each column; Each value represents the mean ± SEM

triglyceride in the serum exposed to cadmium had an incremental distribution pattern than to controls; vice versa, the amount of these parameters in groups V and VI showed a declining process when compared with the cadmium-induced group (II).

Saleh et al. (2018) have reported that the phenolic compounds present in the pomegranate peel powder and extract may have the same antioxidant activity as α -tocopherol acetate in the meat of broiler chickens and decreased the oxidation rate and TBARS index, although their mechanism of action may be different [29]. The results of the present study indicated that the TBARS content in samples treated with the pomegranate powder was non significantly lower than that of the Cd group. In conclusion, these results indicate that Cd induces destructive effects on the stereological indices and lipid peroxidation markers and pomegranate seed powder has prevented the development of these effects in the testis of Japanese quails.

Authors' Contributions

RG, RA and HM performed the experiments. RF, IK, and BK designed the research project and drafted the manuscript.

Acknowledgements

The authors would like to thank the Shahrekord University for financial support.

Conflict of interest

The authors declare that they have no conflicts of interest.

References

- Järup L, Akesson A. Current status of cadmium as an environmental health problem. *Toxicol Appl Pharmacol*. 2009;238(3):201-8.
- Toman R, Massanyi P, Lukáč N, Ducsay L, Golian J. Fertility and content of cadmium in pheasant (*Phasianus colchicus*) following cadmium intake in drinking water. *Ecotoxicol Environ Saf*. 2005;62(1):112-7.
- Dauwe T, Janssens E, Kempnaers B, Eens M. The effect of heavy metal exposure on egg size, eggshell thickness and the number of spermatozoa in blue tit *Parus caeruleus* eggs. *Environ Pollut*. 2004;129(1):125-9.
- Sarkar A, Ravindran G, Krishnamurthy V. A brief review on the effect of cadmium toxicity: from cellular to organ level. *Int J Adv Biotechnol Res*. 2013;3(1):17-36.
- Marettová E, Mareta M, Legáth J. Toxic effects of cadmium on testis of birds and mammals: a review. *Anim Reprod Sci*. 2015;155:1-10.
- Ogawa Y, Itoh M, Hirai S, Suna S, Naito M, Qu N, et al. Cadmium exposure increases susceptibility to testicular autoimmunity in mice. *J Appl Toxicol*. 2013;33(7):652-60.
- Tremellen K. Oxidative stress and male infertility—a clinical perspective. *Hum Reprod Update*. 2008;14(3):243-58.
- Turner TT, Lysiak JJ. Oxidative stress: a common factor in testicular dysfunction. *J Androl*. 2008;29(5):488-98.
- Chen YW, Yang CY, Huang CF, Hung DZ, Leung YM, Liu SH. Heavy metals, islet function and diabetes development. *Islets*. 2009;1(3):169-76.
- Seeram NP, Adams LS, Henning SM, Niu Y, Zhang Y, Nair MG, et al. In vitro antiproliferative, apoptotic and antioxidant activities of punicalagin, ellagic acid and a total pomegranate tannin extract are enhanced in combination with other polyphenols as found in pomegranate juice. *J Nutr Biochem*. 2005;16(6):360-7.
- Türk G, Sönmez M, Aydin M, Yüce A, Gür S, Yüksel M, et al. Effects of pomegranate juice consumption on sperm quality, spermatogenic cell density, antioxidant activity and testosterone level in male rats. *Clin Nutr*. 2008;27(2):289-96.
- Gali-Muhtasib HU, Younes IH, Karchesy JJ, el-Sabban ME. Plant tannins inhibit the induction of aberrant crypt foci and colonic tumors by 1,2-dimethylhydrazine in mice. *Nutr Cancer*. 2001;39(1):108-16.
- Castonguay A, Gali H, Perchellet E, Gao X, Boukharta M, Jalbert G, et al. Antitumorigenic and antipromoting activities of ellagic acid, ellagitannins and oligomeric anthocyanin and procyanidin. *Int J Oncol*. 1997;10(2):367-73.
- Noorafshan A. Stereology as a valuable tool in the toolbox of testicular research. *Ann Anat*. 2014;196(1):57-66.
- Elgindy AAE, Elsarha ES. Biochemical and technological studies on the effect of pomegranate peel in addition to pan bread and its effect on the pollution of cadmium chloride in mice. *Adv Environ Biol*. 2015;9(27):33-43.
- Noorafshan A. Stereology as a valuable tool in the toolbox of testicular research. *Ann Anat*. 2014;196(1):57-66.
- Buege JA, Aust SD. [30] Microsomal lipid peroxidation. *Methods Enzymol*. 52: Elsevier; 1978. p. 302-10.

18. Blanco A, Moyano R, Vivo J, Flores-Acuna R, Molina A, Blanco C, et al. Quantitative changes in the testicular structure in mice exposed to low doses of cadmium. *Environ Toxicol Pharmacol*. 2007;23(1):96-101.
19. Adamkovicova M, Toman R, Cabaj M, Massanyi P, Martiniaikova M, Omelka R, et al. Effects of subchronic exposure to cadmium and diazinon on testis and epididymis in rats. *Sci World J*. 2014;2014:632581.
20. do Carmo Cupertino M, Novaes RD, Santos EC, Bastos DSS, dos Santos DCM, Fialho MdCQ, et al. Cadmium-induced testicular damage is associated with mineral imbalance, increased antioxidant enzymes activity and protein oxidation in rats. *Life Sci*. 2017;175:23-30.
21. Cupertino MC, Novaes RD, Santos EC, Neves AC, Silva E, Oliveira JA, et al. Differential Susceptibility of Germ and Leydig Cells to Cadmium-Mediated Toxicity: Impact on Testis Structure, Adiponectin Levels, and Steroidogenesis. *Oxid Med Cell Longev*. 2017;2017:3405089.
22. Ray PD, Huang BW, Tsuji Y. Reactive oxygen species (ROS) homeostasis and redox regulation in cellular signaling. *Cell Signal*. 2012;24(5):981-90.
23. Pillai A, Gupta S. Antioxidant enzyme activity and lipid peroxidation in liver of female rats co-exposed to lead and cadmium: effects of vitamin E and Mn²⁺. *Free Radic Res*. 2005;39(7):707-12.
24. Kara H, Cevik A, Konar V, Dayangac A, Yilmaz M. Protective effects of antioxidants against cadmium-induced oxidative damage in rat testes. *Biol Trace Elem Res*. 2007;120(1-3):205-11.
25. Samarghandian S, Azimi-Nezhad M, Shabestari MM, Azad FJ, Farkhondeh T, Bafandeh F. Effect of chronic exposure to cadmium on serum lipid, lipoprotein and oxidative stress indices in male rats. *Interdiscip Toxicol*. 2015;8(3):151-4.
26. Manca D, Ricard A, Trottier B, Chevalier G. In vitro susceptibilities of rat tissues to cadmium-induced lipid peroxidation: comparison of evolved hydrocarbons and thiobarbituric acid reactive substances. *In Vitro Toxicol*. 1990;3(3):255-67.
27. Chakraborty S, Singh OP, Dasgupta A, Mandal N, Das HN. Correlation between lipid peroxidation-induced TBARS level and disease severity in obsessive-compulsive disorder. *Prog Neuropsychopharmacol Biol Psychiatry*. 2009;33(2):363-6.
28. Jakovljevic B, Novakov-Mikic A, Brkic S, Bogavac MA, Tomic S, Miler V. Lipid peroxidation in the first trimester of pregnancy. *J Matern Fetal Neonatal Med*. 2012;25(8):1316-8.
29. Saleh H, Golian A, Kermanshahi H, Mirakzehi M. Antioxidant status and thigh meat quality of broiler chickens fed diet supplemented with α -tocopherolacetate, pomegranate pomace and pomegranate pomace extract. *Ital J Anim Sci*. 2018;17(2):386-95.

COPYRIGHTS

©2021 The author(s). This is an open access article distributed under the terms of the Creative Commons Attribution (CC BY 4.0), which permits unrestricted use, distribution, and reproduction in any medium, as long as the original authors and source are cited. No permission is required from the authors or the publishers.

**How to cite this article**

Fatahian Dehkordi RA, Bahadoran S, Alijani M, Mohebi A, Mohammadi H. Recovery effects of pomegranate seed powder on the testes following cadmium poisoning in Japanese quail (*Coturnix japonica*); A stereological and lipid peroxidation study. *Iran J Vet Sci Technol*. 2021; 13(2):100- 105.

DOI: <https://doi.org/10.22067/ijvst.2021.68564.1013>

URL: https://ijvst.um.ac.ir/article_41503.html