

Successful treatment of a subcutaneous axillary abscess due to *Staphylococcus lentus* in a rabbit

Javad Khoshnegah^{1*}, Hossein Kazemi Mehrjerdi¹, Mehrnaz Rad²

¹ Department of Clinical Sciences, School of Veterinary Medicine, Ferdowsi University of Mashhad, Mashhad, Iran.

² Department of Pathobiology, School of Veterinary Medicine, Ferdowsi University of Mashhad, Mashhad, Iran.

Received: March 14, 2009

Accepted: June 15, 2009

Abstract

A 2-year-old, female, crossbred pet rabbit was found to have a subcutaneous axillary abscess from which *Staphylococcus lentus* was the sole isolate. The *S. lentus* - an indigenous bacterium in rabbit saliva - probably was introduced into the axillary region during licking of a small wound. Due to severe neutropenia, the rabbit had developed a serious infection within a few weeks. Marked clinical improvement was observed following abscess excision and treatment with sulfamethoxazole-trimethoprim. *S. lentus* should be added to the growing list of bacteria causing infection especially subcutaneous abscesses in rabbits.

Key Words: *Staphylococcus lentus*, abscess, rabbit.

*Corresponding author: Javad Khoshnegah.

Email: khoshnegah@um.ac.ir

Tel: +98 511 8788944

Fax: +98 511 8763852

Introduction

Sub-cutaneous abscesses in rabbits due to surgery, insect bites, scratches or skin wounds, trauma or foreign bodies, are serious clinical problems (Praag, 2006). Bacterial leakage from an abscess can result in a sudden entry of a huge number of microorganisms into the host's circulation. This bacteremia may progress to sepsis, multi system organ failure and septic shock. The mortality of these complications is very high (Otto et al., 2002). Infected patients often need surgery to remove loculated pus, stop the advancing spread of the infection, and reestablish sufficient blood flow to deliver appropriate antimicrobial agents to the infected site. In some cases, abscesses can be drained in combination with antibiotic treatment. In rabbits, despite the complexity of microflora, only a limited number of different bacterial species are recovered from an abscess. In particular, *Staphylococcus aureus* (Hermans et al., 2003) and *Streptococcus* spp., *Pseudomonas* spp. or *Fusiformis* spp. (Praag, 2006) are often isolated from abscesses in rabbits. This case report describes the first isolation of *Staphylococcus lentus* from an abscess in a rabbit.

Case presentation

A 2-year-old, female, crossbred pet rabbit of 1.5 kg weight was referred to Ferdowsi University of Mashhad Teaching Hospital with a history of inappetence, chronic weight loss and pale mucous membrane. Further examination revealed a hard lump swelling in axillary region which was painless and extended about one-third along the right forelimb (Fig.1). The animal was treated with amoxicillin (Farabi Pharmaceutical Co., Isfahan, Iran), but no improvement was observed. Abnormalities noted in the complete

blood count included moderate normocytic hypochromic and marked neutropenia (1393 cells/ μ l) (Table 1). Swabs were taken from the abscess for bacteriological investigation. Direct examination of pus smear from the abscesses revealed irregular clusters Gram positive cocci. Blood agar and MacConkey agar plates were used for primary isolation from the abscess. All plates were incubated at 37°C for 24 hours. Pure cultures of gram-positive cocci were isolated on blood agar. There was no growth on MacConkey agar. Colonies on blood agar were medium-sized, opaque, rounded, non-mucoid and non haemolytic. Pigment production was positive after incubation at 37°C for 24 hours. Based on the morphology, cultures and biochemical reactions (Table2), the isolate was identified as *S. lentus*, as described by Quinn et al., (2004). The isolate was fully sensitive to gentamicin, kanamycin, ampicillin, and sulphamethoxazole/trimethoprim and moderately sensitive to oxytetracycline and resistant to novobiocin. The patient received a single high loading dose of 8 mg/kg of Sulfamethoxazole-Trimethoprim (Tehran Chemie Pharmaceutical Co., Tehran, Iran) intravenously, followed by 8 mg/kg trimethoprim and 40 mg/kg sulfamethoxazole, orally, twice a day for 7 days. With owner's permission of surgery, resection of the mass was attempted. On gross examination, the oval mass sized in 8.0 \times 7.5 cm was presented. Cross-section examination revealed a grayish-white solid tissue with a central necrosis and hemorrhage (Fig 1). The patient improved quickly after resection and recovered uneventfully. After 3 months of follow-up, the patient remained in good health.

Table 1: Complete blood count data

Parameter	Patient	Reference range *
Haematocrit (%)	30	37-50
Haemoglobin (g/ dl)	12	9.8-17.4
Total red cell count ($\times 10^6/\mu\text{l}$)	6	5.11-7.94
Mean corpuscule volume (fl)	61	60
Mean corpuscular haemoglobin concentration (%)	30	35-37
White blood cells (/ μl)	7293	5200-12,500
Neutrophils (/ μl)	1393	2600-6750
Lymphocytes (/ μl)	5002	3500-6500
Monocytes (/ μl)	698	500-1675
Eosinophils (/ μl)	200	62-437

* From (Feldman et al., 2000)

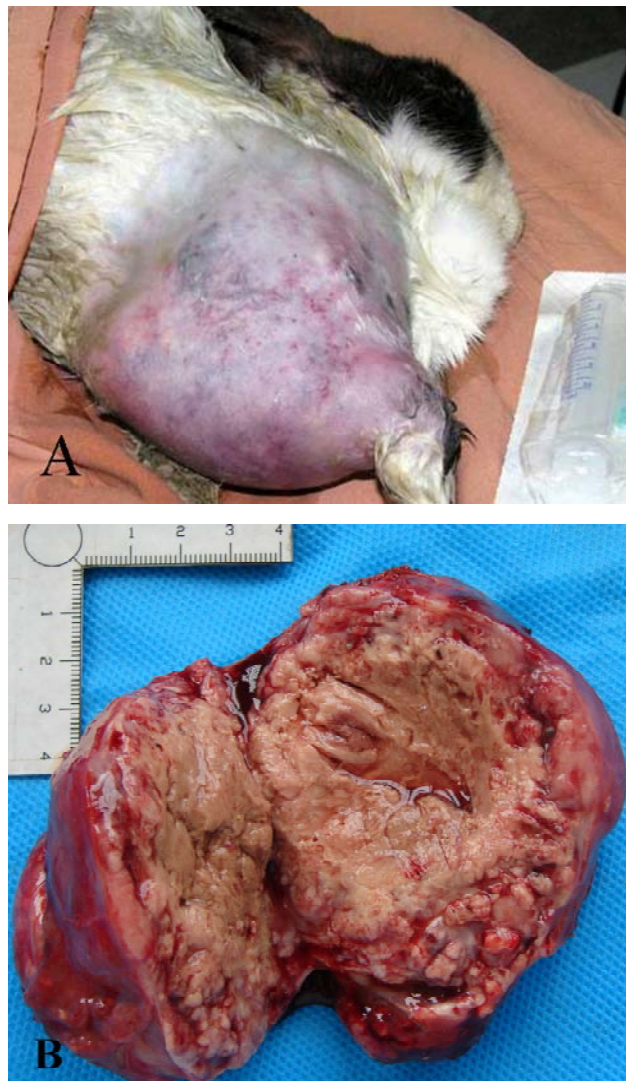


Figure 1: Subcutaneous abscess in a rabbit caused by *S. lentus*. Hard lump swelling in axillary region extended about one-third along the right forelimb (A). The typical appearance is that of a well-defined, solid, heterogeneous mass with a grayish-white solid tissue and hemorrhage (B).

Table 2: Cultural and biochemical characteristics of the isolated *S. lentus*. Tests 11-14 specifically were used for classifying *S. lentus* form other staphylococcus spp.

No	Test*	Results
1	Oxidation Fermentation	F
2	Colony diameter after 24 hours of incubation > 5mm	-
3	Aerobic growth	+
4	Oxidase	+
5	Catalase	+
6	Coagulase	-
7	Resistance to bacitracin disc(0.04 unit)	+
8	Novobiocin resistance (1.6µg/ml)	+
9	DNase	-
10	Urease	-
11	Aesculin hydrolysis	+
12	Manitol fermentation (Manitol salt agar)	+
13	Alkaline phosphatase	-
14	production of acid from xylose	-

* From (Quinn *et al.*, 2004)

Discussion

S. lentus can be isolated from a variety of farm animals, pets, and wild animals, as well as from various food products of animal origin (Hauschild, and Schwartz, 2003; Svec et al., 2004). In rabbits, *S. lentus* is one of the major bacteria in saliva and a minor bacterium in jejunum fluids, nasal wash (Kanda et al., 2001) and colon (Canganella et al., 1992). This report highlights the possible role of *S. lentus* in abscess formation in rabbit. The isolation of *S. lentus* in pure culture indicates that the bacterium was present in abscess. It can be estimated that the organism initially inoculated into the small wound on axillary region during licking which led to subcutaneous abscess formation.

There may be several reasons for failure to respond to initial treatment (inadequacy of the initial antibiotic therapy, poor absorption, deficit in local or systemic immunity), but this may be due to the organism (*S. lentus*) which is not susceptible to the initial antimicrobial regimen. However, the possibility that the rabbit was immunosuppressed could not be excluded. In conclusion, isolation of *S. lentus* from clinical specimens should be interpreted carefully to pinpoint the role of this organism in subcutaneous infection.

Acknowledgment

The authors wish to thank Mr. Barati and Mrs. Moghadam for their skilled technical assistance.

References

- Canganella, F., Zirletta, G., Gualterio, L., Massa, S., and Trovatelli, L. D. (1992): Anaerobic facultative bacteria isolated from the gut of rabbits fed different diets. *Zentralbl Mikrobiol* 147(8), 537-540.
- Feldman, B.F., Zinkl, J.G., Jain, N.C., Gasper, P.E., Giger U., Gopegui, R.R., et al. (2000): *Schalm's Veterinary Hematology*, Lippincott Williams & Wilkins, p:1104.
- Hauschild, T. and Schwarz, S. (2003): Differentiation of *Staphylococcus sciuri* strains isolated from free-living rodents and insectivores. *J Vet Med B* 50,241-246.
- Hermans, K., Devriese, L. A., and Haesebrouck, F. (2003): Rabbit staphylococcosis: difficult solutions for serious problems. *Vet Microbiol* 91(1), 57-64.
- Kanda, M., Inoue, H., Fukuizumi, T., Tsujisawa, T., Tominaga, K., and Fukuda, J. (2001): Detection and rapid increase of salivary antibodies to *Staphylococcus lentus*, an indigenous bacterium in rabbit saliva, through a single tonsillar application of bacterial cells. *Oral Microbiol Immunol* 16(5), 257-64.
- Otto, B. R., Van Dooren, S. J., Dozois, C. M., Luirink, J., and Oudega, B. (2002): *Escherichia coli* hemoglobin protease autotransporter contributes to synergistic abscess formation and heme-dependent growth of *Bacteroides fragilis*. *Infect Immun* 70(1), 5-10.
- Praag, E. V. (2006): Skin abscess, In *Skin diseases*. http://www.medirabbit.com/EN/Skin_diseases/Bacterial/skin_abscess. pp. 1-4.
- Quinn, P. J., Markey B.K., Carter, M.E., Donnelly, W.J., Leonard, F. C. (2004): *Veterinary Microbiology and Microbial Diseases*. Blackwell Publishing Company. pp: 43-48.
- Svec, P., Vancanneyt, M., Sedlacek, I., Engelbeen, K., Stetina, V., Swings, J., and etras, P. (2004): Reclassification of *Staphylococcus pulvereri* Zakrzewska-Czerwinska et al. 1995 as a later synonym of *Staphylococcus vitulinus* Webster et al. 1994, *Int. J. Syst. Evol. Microbiol.* 54 (2004), pp. 2213–2215.

درمان آبسه زیر جلدی ناحیه آگزیلاری ناشی از استافیلوکوکوس لنتوس در خرگوش

جواد خوش نگاه^۱، حسین کاظمی^۱، مهرناز راد^۲

^۱ گروه علوم در مانگامی، دانشکده دامپزشکی دانشگاه فردوسی مشهد، مشهد، ایران

^۲ گروه پاتوبیولوژی، دانشکده دامپزشکی دانشگاه فردوسی مشهد، مشهد، ایران

دریافت مقاله: ۸۷/۱۲/۲۵ پذیرش نهایی: ۸۸/۳/۲۵

چکیده

از یک خرگوش خانگی ماده‌ی ۲ ساله نژاد مخلوط، مبتلا به آبسه‌ی ناحیه‌ی زیر بغل، باکتری استافیلوکوکوس لنتوس به طور خالص جدا شد. به احتمال زیاد این ارگانیزم از طریق بزاق به هنگام لیس زدن زخمی کوچک در ناحیه‌ی زیر بغل به زیر جلد منتقل شده، ایجاد آبسه کرده و به دلیل نوتروپنی شدید، طی چند هفته بیماری شدیدی را سبب شده است. به دنبال برش و خارج سازی جراحی توده‌ی آبسه و تجویز داروی سولفامتوکسازول-تری متوپریم، بهبود چشمگیری در وضعیت بالینی خرگوش رؤیت شد. با توجه به جداسازی خالص باکتری استافیلوکوکوس لنتوس، این باکتری باید به فهرست رو به افزایش علل باکتریایی ایجاد عفونت در خرگوش‌ها به ویژه خرگوش‌های دچار نقص ایمنی، افزوده شود.

واژه‌های کلیدی: خرگوش، استافیلوکوکوس لنتوس، آبسه