



Helicobacter Detection in the Stomach of Apparently Normal Donkeys: Sampling, Diagnostic Methods, and Implications for Equine Glandular Gastric Disease and Serum Antioxidant Status

Masoud Ahmadnejad^a, Ghader Jalilzadeh-Amin^b, Monireh Khordadmehr^c

^a Department of Clinical Science, Faculty of Veterinary Medicine, Razi University, Kermanshah, Iran.

^b Department of Internal Medicine, Faculty of Veterinary Medicine, Urmia University, Urmia, Iran.

^c Department of Pathobiology, Faculty of Veterinary Medicine, University of Tabriz, Tabriz, Iran.

ABSTRACT

The involvement of *Helicobacter*-like agents in EGGD is not clear. Much evidence supports the presence of *Helicobacter* in the horse's stomach, but it is not so clear about the donkey. The present study was conducted to evaluate the presence of *Helicobacter* in the stomach of donkeys and assess the best method for its identification and its possible participation in EGGD and serum antioxidant status. Gastric juice sampling and biopsy from NMP and PA were performed by gastroscopic method from 12 donkeys. Histopathology and RUT were used to identify *Helicobacter*. TAC, THIOL, NO, and DPPH were measured to assess the antioxidant status of serum. *Helicobacter* was detected only by the RUT method in one donkey (8.33%), but it is unlikely that this infection was effective in causing EGGD. The RUT results for the three samples of gastric juice, NMP, and PA were not different. Histopathology of NMP and PA did not show *Helicobacter* infection. *Helicobacter* is present in the stomach of a donkey but does not change the antioxidant status of serum. The RUT is more efficient than H&E histopathology for the assessment of *H. pylori* in the equine stomach, and the RUT of gastric juice is preferable to tissue samples because it is easy, fast, and non-invasive. In conclusion, further studies using more accurate methods are recommended to evaluate the effect of *Helicobacter* in the gastric diseases of donkeys and other equine.

Keywords

Equine Gastric Ulcer Syndrome, Donkey, Microbiome, Antioxidant

Number of Figures: 2
Number of Tables: 1
Number of References: 41
Number of Pages: 7

Abbreviations

EGGD: Equine glandular gastric disease

NMP: Near the margo plicatus

PA: Pyloric antrum

RUT: Rapid urease test

H&E: Hematoxylin and eosin

TAC: Total antioxidant capacity

Introduction

The EGGD is one of the most important gastrointestinal diseases in horses [1]. Gastric microbiota changes in EGGD, but the cause is not completely clear [2, 3]. However, there is no conclusive evidence that bacteria are always involved in the development of EGGD [4], and there is a possibility that microbiota changes are secondary and related to opportunistic bacteria. Opportunistic bacterial colonization has been observed in chronic EGGD [4, 5]. Bacteria, such as *Escherichia fergusonii*, *Enterococcus faecium*, *Streptococcus bovis*, and *Sarcina* can be associated with EGGD lesions [2, 6]. *H. pylori* is a suspected etiology in the pathogenesis of gastric ulcers in humans, dogs, and cats [7, 8]. However, the involvement of *Helicobacter* in EGGD is uncertain [9].

Helicobacter spp. belongs to the Campylobacter genus and is often believed not to be effective in the etiopathology of EGGD [4]. However, *Helicobacter* has been identified by different methods in the equine stomach [10–13] and feces [14]. Some studies did not find any evidence of the involvement of *Helicobacter* species in the pathogenesis of EGGD [2, 6, 15]. Although *Helicobacter* was found in the stomach of horses, it had no significant relationship with EGGD [3]. In some reports, the presence of *Helicobacter* has been associated with EGGD [16–18].

The RUT method has been used in some studies to identify *Helicobacter* in horses [10, 18]. Evaluation with RUT is based on the presence of bacterial urease enzyme and urea absorption from the culture medium. The sensitivity of RUT in horses was 40% compared to PCR [10] and 100% compared to histopathology [18]. Histopathological and immunohistochemical evaluation of the glandular and non-glandular gastric samples of horses showed 81% *Helicobacter* infection [12].

Hyperlipidemia, kidney disease, and grain overload increase the risk of EGUS in donkeys and can cause colic [19], but the importance of bacteria in the pathogenesis of EGUS in donkeys is unknown. However, some researchers consider *Helicobacter* to be a possible cause of EGUSs in donkeys [20, 21]. Moreover, people infected with *Helicobacter* have lower antioxidant levels than healthy people [22]. The present study gives a perspective on the presence of *Helicobacter* in the stomach of donkeys using RUT for the

mucosal samples of gastric gland and gastric juice, as well as the HPE of biopsied tissue samples. It also explores the presence of EGGD and serum antioxidant levels in donkeys to evaluate the possibility of their relationship with the presence of *Helicobacter* in the stomachs of donkeys.

Results

Vital signs of animals, including body temperature, respiration rate, and heart rate were normal in clinical examination. The subjects had no clinical signs of diseases, such as alimentary disorders and colic. The results of the gastroscopy showed that the EGGD grade was zero in all donkeys and only one of the animals had a grade 1 EGGD.

Evaluation of RUT for gastric juice and glandular gastric tissue samples showed infection with urease = positive *Helicobacter*-like infections in only one of 12 animals (Figure 1). Both gastric juice RUT and glandular gastric (NMP and PA) mucosa RUT were positive in the same animal. In the gastroscopic evaluation of the animal with a positive RUT, there was no sign of even the mildest degree of EGGD.

Histopathological examination of NMP and PA gastric specimens did not confirm *Helicobacter*-like infection in any of the donkeys. No pathological changes were found in the histopathological samples of NMP and PA. There was no obvious difference between the antioxidant status of the animal that had positive RUT and the mean of other animals that had negative RUT (Table 1). The values obtained for the animal with a positive RUT were within the range of the changes of the values obtained for other animals with a negative RUT. Therefore, it may be concluded that the presence of bacteria and a positive test did not cause obvious differences between the two groups of animals (Table 1).

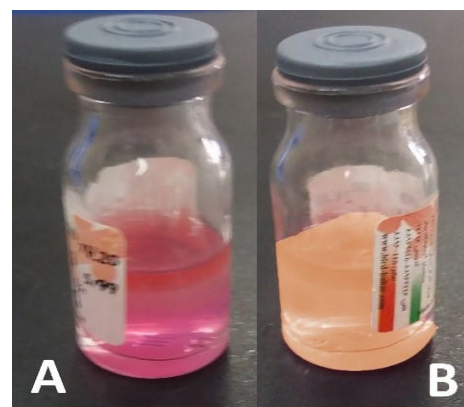


Figure 1. Positive (A) and negative (B) RUT samples.

Abbreviations Cont'd

THIOL: Total thiol

NO: Nitric oxide

DPPH: Diphenyl-1-picrylhydrazyl

EGUS: Equine gastric ulcer disease

H. pylori: *Helicobacter pylori*

HPE: Histopathological evaluation

Table 1.

Comparison of serum antioxidant status in donkey with positive RUT and donkeys with negative RUT

| Antioxidant test | RUT (mean) | Negative RUT | Positive RUT | CI |
|------------------|------------|--------------|--------------|--------------|
| TAC (nmol/mg) | 26.45 | | 22.35 | (1.21-6.98) |
| DPPH (nmol/mg) | 46.89 | | 48.67 | (-6.56-3.01) |
| NO (nmol/mg) | 28.80 | | 26.37 | (8.05-4.05) |
| THIOL (nmol/mg) | 17.50 | | 16.74 | (-1.98-3.51) |

total antioxidant capacity (TAC), total thiol (THIOL), nitric oxide (NO), diphenyl-1-picrylhydrazyl (DPPH)

Discussion

We evaluated the presence of *Helicobacter*-like bacteria in the donkey stomach by RUT and histopathology. The findings of the present study confirm the presence of *Helicobacter* in the donkey's stomach, but similar to the horse [4], the presence of *Helicobacter* is not related to the development of EGGD in the donkey.

Some studies emphasize the presence of *Helicobacter* in the equine stomach. In the genetic analysis conducted on the gastric mucosa of slaughtered Colombian horses, it was found that 23.3% of the samples were positive for *Helicobacter* species. A gene similar to *H. heilmannii* was identified. There was no significant relationship between the presence of *Helicobacter* and gastric ulcer [23]. Some species of *Helicobacter*, such as *H. equorum*, were able to multiply in the hindgut of horses in the experiments, but they did not cause any microscopic or clinical pathological complications [11]. The PCR evaluation of gastric mucosa biopsies of horses (93% with gastric lesions) showed that only 14% were positive for *H. pylori* and all the samples were negative for *H. equorum*. *H. equorum* was found in the fecal samples of only 8% of horses [24].

In some studies, no signs of *Helicobacter*-like agents have been found in the equine gastric. Fluorescence in situ hybridization and RUT were performed on healthy and unhealthy gastric mucosa of slaughtered Danish horses. There was no evidence of *Helicobacter* in the stomachs of healthy and unhealthy horses [6]. In a study on the cytology brush samples of horse glandular mucosa, the microbiota was analyzed by DNA sequencing method and no evidence of *Helicobacter* presence was found [2]. Moreover, *Helicobacter* was not reported in the microbiota of stable horses' feces [25]. *Helicobacter* was not found in the gastric mucosa of healthy American horses [26]. *Helicobacter* was not found in the gastric biopsies of Korean racing horses with gastric ulcer by PCR and

culture, and only in two cases *H. pylori* and *H. ganmani* were isolated by next-generation sequencing techniques [15].

Studies have been conducted on the digestive microbiota of donkeys, but there were no clear signs of *Helicobacter* presence in the digestive system. Investigation of the digestive tract microbiota of slaughtered donkeys showed that diversity in the stomach pylorus is less than in the cecum and large intestines [27]. Growing evidence has shown that the diversity of the fecal microbiota of donkeys depends on age [28] and gender-dependent [29], and the microbial community composition in wild asses is more complex than in domestic donkeys [30].

In the present study, RUT of all the specimens of gastric juice and glandular gastric mucosa of NMP and PA revealed *Helicobacter* infection in the infected stomach. According to the results obtained in the present study, it is possible to use gastric mucosal RUT and gastric juice RUT to evaluate *Helicobacter*-like infections. However, the use of gastric juice is the preferred method because it is less invasive and can be completed with simpler equipment and less skill. As the results of the present study showed in equine, RUT is more sensitive than HPE for detecting *H. pylori* in humans [31]. A comparison of RUT and HPE in humans with gastritis showed that both tests have the same accuracy in detecting *H. pylori* infection. Since RUT is a cheap and fast technique, it can be a good alternative to HPE [32]. In humans, a new method for RUT has been used in which the mucosa is swept using a sweeping motion with an absorbent swab held with forceps. Compared to the conventional method of tissue sample collection, the sweeping RUT method had higher sensitivity and accuracy along with faster detection time for *H. pylori* diagnosis [33]. The findings of the current research showed no difference between the RUT of gastric juice, NMP, and PA gastric tissue samples.

In the previous study, the sensitivity of RUT in horses was 40% compared to detection by PCR as the gold standard [10]. Some *Helicobacter* isolates from horses were urease-negative [14] and had no pathological effect [11]. The use of RUT will not be suitable for detecting urease-negative *Helicobacter*. Therefore, RUT will not detect urease-negative *H. pylori*.

In the present study, H&E staining could not show *Helicobacter* infection in RUT-positive samples. Warthin-Starry special stain, Giemsa, and Blue Toluidine staining methods identify *Helicobacter* as well as RUT in horses [18]. Therefore, special staining techniques can be used to detect *Helicobacter* in equine. However, in one study, no *Helicobacter* con-

tamination was found in the histopathology of the postmortem horses' stomachs despite using special stains, including Gram, PAS, and Warthin Starry [34].

Histopathological and immunohistochemical evaluation of samples collected from the mucosa and submucosa of slaughter horses was performed in Araguari, Brazil. In this evaluation, 81% of the horses had *Helicobacter* species in both the glandular and non-glandular regions, and the highest contamination was observed in the margo plicatus region [12]. The results of the present study showed no difference between the histopathological results of NMP and PA.

The results of the present research showed that serum antioxidant levels in *Helicobacter*-positive donkeys do not differ from *Helicobacter*-negative donkeys. On the other hand, the serum antioxidant level in humans with *H. pylori* infection is different from healthy people and *H. pylori*-positive patients have lower total thiol, native thiol, and disulphide levels than negative cases [22].

Previously, it was believed that antibiotics should be used to treat EGUS because *Helicobacter* was considered to be involved in the development of this syndrome [35]. In some studies, the microbiota of horses with EGGD was not different from the microbiota of healthy horses. For example, *Lactobacillus salivarius* and *Sarcina ventriculi* have been found in the healthy and lesioned gastric mucosa of horses [6]. However, in one study, *Sarcina* was more in the mucosa involved with EGGD showing that it may play a role in its pathogenesis. Proteobacteria were more abundant in healthy mucosa than in EGGD [2].

The limitations of the present study were the small number of animals and the lack of more accurate *Helicobacter* diagnosis methods, such as PCR or specific staining for histopathology samples. In addition to the valuable findings of the present study on miniature donkeys, perhaps these results can be extended to horses as well. This study was not repeated in horses due to financial limitations for buying horses.

It was concluded that donkeys, similar to horses, may be positive for *Helicobacter*-like, but it is unlikely that this infection will be effective in the development of EGGD. Glandular gastric infection with *Helicobacter*-like did not change the antioxidant status of the serum. The results obtained from the RUT methods for all three gastric juice, NMP, and PA tissue samples were not different from each other. Histopathology with the H&E staining of glandular gastric tissue of NMP and PA could not show *Helicobacter*-like infection and the sampling sites did not make any difference to each other in this respect.

Materials and Methods

Animals

Miniature donkeys (n=12), including six females and six uncastrated males, were randomly obtained from West Azerbaijan province, Iran. The animals aged 3-7 years, weighed 150-200 kg, and had a body condition score of 3-4 out of 9 [36]. These animals received oral ivermectin (0.2 mg/kg, IVERGEN®, Laluk, Tehran, Iran) six weeks before the start of the study. The animals were housed in stables, were fed daily with alfalfa hay, and had constant access to water. Physical examination of the animals was performed and their clinical health was confirmed.

Experimental Design

In the present study, donkeys were subjected to gastroscopy and gastric juice samples were taken for RUT, and tissue samples of gastric glandular mucosa were taken for histological evaluations with H&E staining and RUT. Tissue samples were evaluated for the presence of *Helicobacter* spp. infection under a light microscope. The commercial RUT kit (Bahar Afshan, Tehran) was used to evaluate the presence of urease-positive bacteria.

Blood samples were collected from donkeys and a complete blood cell count was performed immediately after sampling. Serum was obtained after clotting and centrifugation at 5000 rpm for 10 min. The sera were kept at -20°C until measurements. To evaluate the oxidant-antioxidant status of serum, TAC, THIOL, NO, and DPPH were evaluated [37]. The researchers and technicians involved in the trial, including those who performed sampling and laboratory and histological analyses, were blinded to the previously obtained results.

Endoscopy

Food (12 hours) and water (4 hours) withholding were applied before gastroscopy [38]. Sedation was performed using intravenous acepromazine at a dose of 0.05 mg/kg and xylazine at a dose of 0.5 mg/kg (NEUROTRANQ®, Alfasan, Woerden, Holland) [39]. Before the gastroscopic examination, gastric fluid was sucked using an endoscope catheter tube (7 ft, 3.5 m, STORZ, Tuttlingen, Germany) for RUT (Figure 2). Gastroscopy (STORZ®, RP100, Tuttlingen, Germany) was performed by blowing air and washing food residues on the gastric mucosa. The entire stomach and the upper duodenum were examined, except for the part that was covered with a little water and food at the bottom of the stomach [40]. EGGD was evaluated with a grade of 0-4 by two expert investigators [41]. Glandular gastric mucosal biopsy of NMP and PA was performed using grasping forceps (3.5 m, STORZ, Tuttlingen, Germany). Prior to the biopsy, the sampling site was flushed with distilled water. Histopathological specimens were fixed in 10% formalin immediately after sampling.

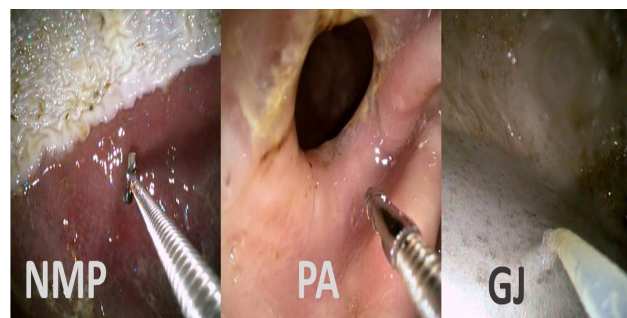


Figure 2. Sampling of glandular gastric mucosa from near margo plicatus (NMP) and pyloric antrum (PA) for histopathology and RUT. Gastric juice (GJ) sampling for RUT.

Statistical analysis

Statistical analysis could not be performed due to the presence of only one animal with a positive rapid urease test, and only the descriptive statistics and range of parameters of other animals with a negative test were presented. The parameter values were calculated by the Excel software.

Authors' Contributions

MA contributed to concept design. MA and GJ collected all data. GJ performed the statistical analysis. MK performed the histopathological examinations. MA preparation of the manuscript. All authors contributed to manuscript revision and read and approved the submitted version

Acknowledgements

We would like to thank Mr. Mohammad Nezhad for his technical assistant. This study was funded by the Research Council of the Ferdowsi University of Mashhad, Iran (No. 3/58310).

Competing Interests

The authors declare that there is no conflict of interest.

References

- Sykes BWW, Hewetson M, Hepburn RJJ, Luthersson N, Tamzali Y. European College of Equine Internal Medicine Consensus Statement-Equine Gastric Ulcer Syndrome in Adult Horses. *J Vet Intern Med.* 2015;29:1288–99. Doi:10.1111/jvim.13578.
- Voss SJ, McGuinness DH, Weir W, Sutton DGM. A study comparing the healthy and diseased equine glandular gastric microbiota sampled with sheathed transendoscopic cytology brushes. *J Equine Vet Sci.* 2022;116:104002. Doi:10.1016/J.JEVS.2022.104002.
- Paul LJ, Ericsson AC, Andrews FM, Keowen ML, Morales Yniiguez F, Garza F, Banse HE. Gastric microbiome in horses with and without equine glandular gastric disease. *J Vet Intern Med.* 2021;35:2458–64. Doi:10.1111/JVIM.16241.
- Rendle D, Bowen M, Brazil T, Conwell R, Hallowell G, Hepburn R, Hewetson M, Sykes B. Recommendations for the management of equine glandular gastric disease. *UK-Vet Equine.* 2018;2:2–11. Doi:10.12968/ukve.2018.2.s1.3.
- Hewetson M. Managing glandular gastric disease in horses. *In Pract.* 2021;43:217–28. Doi:10.1002/INPR.40.
- Husted L, Jensen TK, Olsen SN, Mølbak L. Examination of equine glandular stomach lesions for bacteria, including *Helicobacter* spp by fluorescence in situ hybridisation. *BMC Microbiol.* 2010;10:1–8. Doi:10.1186/1471-2180-10-84/FIGURES/6.
- Graham DY. History of *Helicobacter pylori*, duodenal ulcer, gastric ulcer and gastric cancer. *World J Gastroenterol.* 2014;20:5191. Doi:10.3748/WJG.V20.I18.5191.
- Simpson K, Neiger R, DeNovo R, Sherding R. The relationship of *Helicobacter* spp. infection to gastric disease in dogs and cats. *J Vet Intern Med.* 2000;14:223–7. Doi:10.1111/j.1939-1676.2000.tb02243.x.
- Sykes B, Jokisalo JM. Rethinking equine gastric ulcer syndrome: Part 3 – Equine glandular gastric ulcer syndrome (EGGUS). *Equine Vet Educ.* 2015;27:372–5. Doi:10.1111/EVE.12287.
- Hepburn RJ, Mrcvs B, Furr Dvm MO. Investigation into the Presence of *Helicobacter* in the Equine Stomach by Urease Testing and Polymerase Chain Reaction and Further Investigation into the Application of the 13C-Urea Blood Test to the Horse. 2004.
- Moyaert H, Decostere A, Pasmans F, Baele M, Ceelen L, Smits K, Ducatelle R, Haesebrouck F. Acute in vivo interactions of *Helicobacter equorum* with its equine host. *Equine Vet J.* 2007;39:370–2. Doi:10.2746/042516407X206391.
- Fonseca CB, Braga L, Silva Costa Ferreira C, Emerin Pinna A, Silva Leite J, Ferreira AM. Immunohistochemical Identification of *Helicobacter* Spp and Evaluation of the Degree of Inflammation in the Region of the Margo Plicatus of the Equine Stomach. *SSRN Electron J.* 2022. Doi:10.2139/ssrn.3983892.
- Rezazadeh F, Pourebrahimi N, Ghotaslou R, Nasab MG, Memar MY. Frequency of endoscopic findings of equine squamous gastric disease (ESGD) in rural horses and its association with *Helicobacter pylori* virulence genes. *Vet Med (Praha).* 2022;67:61–9. Doi:10.17221/154/2020-VETMED.
- Moyaert H, Decostere A, Vandamme P, Debruyne L, Mast J, Baele M, Ceelen L, Ducatelle R, Haesebrouck F. *Helicobacter equorum* sp. nov., a urease-negative *Helicobacter* species isolated from horse faeces. *Int J Syst Evol Microbiol.* 2007;57:213–8. Doi:10.1099/IJS.0.64279-0/CITE/REFERENCES.
- Dong HJ, Ho H, Hwang H, Kim Y, Han J, Lee I, Cho S. Diversity of the Gastric Microbiota in Thoroughbred Racehorses Having Gastric Ulcer. *J Microbiol Biotechnol.* 2016;26:763–74. Doi:10.4014/JMB.1507.07054.
- Contreras M, Morales A, García-Amado MA, De Vera M, Bermúdez V, Gueneau P. Detection of *Helicobacter*-like DNA in the gastric mucosa of Thoroughbred horses. *Lett Appl Microbiol.* 2007;45:553–7. Doi:10.1111/j.1472-765X.2007.02227.x.
- Fox JG. The non-*H. pylori* helicobacters: Their expanding role in gastrointestinal and systemic diseases. *Gut.* 2002;50:273–83. Doi:10.1136/gut.50.2.273.
- Abelardo MB, Garcia F, Bermudez V. Detection of *Helicobacter*-like organisms in Thoroughbred horses from Venezuela. *Brazilian J Vet Pathol.* 2010;3:52–5.

19. Sprayberry KA, Robinson NE. Robinson's Current Therapy in Equine Medicine: Seventh Edition. 2014. Doi:10.1016/C2011-0-05761-7.
20. Morales A, Lamprea Garrido A, Méndez Sánchez A. Gastric Ulcers Syndrome in Donkeys. *Rev Med Vet (Bogota)*. 2015;31-5.
21. Rezazadeh F, Gharehaghajlou Y. Endoscopic Finding of Gastric Ulcer in Rural Horse and Relation with *Gasterophilus* spp. *Iran J Vet Med*. 2020;14:45-52. Doi:10.22059/ijvm.2019.277457.1004975.
22. Baykan AR, Biçer C, Gerçekler E, Erel Ö, Cerrah S, Albayrak B, Utlü M, Kargılı A. Thiol/disulphide homeostasis in *Helicobacter pylori* infected patients. *Eur Res J*. 2019. Doi:10.18621/eurj.443557.
23. Zuluaga-Cabrera AM, Jaramillo-Morales C, Martínez-Aranzales JR, Zuluaga Cabrera AM, Jaramillo Morales C, Martínez Aranzaes JR. Presence of *Helicobacter* spp. in dental tartar and gastric mucosa, and its relationship with EGUS in horses from a public slaughterhouse. *Rev Colomb Ciencias Pecu*. 2022;35:109-17. Doi:10.17533/udea.rccp.v35n1a06.
24. Bezdekova B, Futas J. *Helicobacter* species and gastric ulceration in horses: a clinical study. *Vet Med (Praha)*. 2009;54:577-82.
25. Fernandes KA, Rogers CW, Gee EK, Kittelmann S, Bolwell CF, Bermingham EN, Biggs PJ, Thomas DG. Resilience of Faecal Microbiota in Stabled Thoroughbred Horses Following Abrupt Dietary Transition between Freshly Cut Pasture and Three Forage-Based Diets. *Anim an Open Access J*. from MDPI 2021;11. Doi:10.3390/ANI11092611.
26. Perkins GA, den Bakker HC, Burton AJ, Erb HN, McDonough SP, McDonough PL, Parker J, Rosenthal RL, Wiedmann M, Dowd SE, Simpson KW. Equine stomachs harbor an abundant and diverse mucosal microbiota. *Appl Environ Microbiol*. 2012;78:2522-32. Doi:10.1128/AEM.06252-11.
27. Liu G, Bou G, Su S, Xing J, Qu H, Zhang X, Wang X, Zhao Y, Dugarjaviin M. Microbial diversity within the digestive tract contents of Dezhou donkeys. *PLoS One*. 2019;14:e0226186. Doi:10.1371/journal.pone.0226186.
28. Xing J, Liu G, Zhang X, Bai D, Yu J, Li L, Wang X, Su S, Zhao Y, Bou G, Dugarjaviin M. The Composition and Predictive Function of the Fecal Microbiota Differ Between Young and Adult Donkeys. *Front Microbiol*. 2020;11:3016. Doi:10.3389/FMICB.2020.596394/BIBTEX.
29. Liu X, Fan H, Ding X, Hong Z, Nei Y, Liu Z, Li G, Guo H. Analysis of the gut microbiota by high-throughput sequencing of the v5-v6 regions of the 16S rRNA gene in donkey. *Curr Microbiol*. 2014;68:657-62. Doi:10.1007/s00284-014-0528-5.
30. Liu H, Zhao X, Han X, Xu S, Zhao L, Hu L, Xu T, Zhao N, Zhang X, Chen D, He F, Chen X. Comparative study of gut microbiota in Tibetan wild asses (*Equus kiang*) and domestic donkeys (*Equus asinus*) on the Qinghai-Tibet plateau. *PeerJ*. 2020;2020:e9032. Doi:10.7717/PEERJ.9032/SUPP-18.
31. Dechant FX, Dechant R, Kandulski A, Selgrad M, Weber F, Reischl U, Wilczek W, Mueller M, Weigand K. Accuracy of Different Rapid Urease Tests in Comparison with Histopathology in Patients with Endoscopic Signs of Gastritis. *Digestion*. 2020;101:184-90. Doi:10.1159/000497810.
32. Karthikeyan R, Sundaravadanan BS. Rapid Urease Test vs Histopathological Examination: A Prospective Study to Compare the Accuracy of Both Tests in the Diagnosis of *Helicobacter pylori*. *J Pharm Res Int*. 2021:320-5. Doi:10.9734/jpri/2021/v33i49b33369.
33. Noh CK, Lee GH, Park JW, Roh J, Han JH, Lee E, Park B, Lim SG, Shin SJ, Cheong JY, Kim JH, Lee KM. Diagnostic accuracy of "sweeping" method compared to conventional sampling in rapid urease test for *Helicobacter pylori* detection in atrophic mucosa. *Sci Rep*. 2020;10:1-10. Doi:10.1038/s41598-020-75528-1.
34. Martineau H, Thompson H, Taylor D. Pathology of gastritis and gastric ulceration in the horse. Part 1: Range of lesions present in 21 mature individuals. *Equine Vet J*. 2009;41:638-44. Doi:10.2746/042516409X464816.
35. Andrews F, Bernard W, Byars N, Cohen T, Divers C, MacAllister A, McGladdery A, Merritt M, Murray, Orsini J, Snyder J, Vatistas N. Recommendations for the diagnosis and treatment of equine gastric ulcer syndrome (EGUS): The Equine Gastric Ulcer Council. *Equine Vet Educ*. 1999;11:262-72. Doi:10.1111/j.2042-3292.1999.tb00961.x.
36. Pearson RA, Ouassat M. A guide to live weight estimation and body condition scoring of donkeys. University of Edinburgh, Centre for Tropical Veterinary Medicine; 2000.
37. Cecchini S, Fazio F. Assessment of total antioxidant capacity in serum of heathy and stressed hens. *Animals*. 2020;10:1-8. Doi:10.3390/ani10112019.
38. Lopez-Sanroman F. Endoscopy of the upper airways and the proximal digestive tract in the donkey (*Equus asinus*). *J Equine Vet Sci*. 2001;21:17-20. Doi:10.1016/S0737-0806(01)70233-X.
39. Lucas Castillo JA, Gozalo-Marcilla M, Werneck Fonseca M, Possebon FS, da Rosa AC, de Araujo Aguiar AJ. Sedative and cardiorespiratory effects of low doses of xylazine with and without acepromazine in Nordestino donkeys. *Equine Vet J*. 2018;50:831-5. Doi:10.1111/evj.12835.
40. Ahmadnejad M, Jalilzadeh-amin G, Sykes BW. Prophylactic effects of *Glycyrrhiza glabra* root extract on phenylbutazone-induced Equine Glandular Gastric Disease (EGGD). *J Equine Vet Sci*. 2022:104088. Doi:10.1016/J.JEVS.2022.104088.
41. Sykes BW, Jokisalo JM. Rethinking equine gastric ulcer syndrome: Part 1 - Terminology, clinical signs and diagnosis. *Equine Vet Educ* 2014;26:543-7. Doi:10.1111/EVE.12236.

COPYRIGHTS

©2024 The author(s). This is an open access article distributed under the terms of the Creative Commons Attribution (CC BY 4.0), which permits unrestricted use, distribution, and reproduction in any medium, as long as the original authors and source are cited. No permission is required from the authors or the publishers.

**How to cite this article**

Ahmadnejad M, Jalilzadeh-Amin Gh, Khordadmehr M. Helicobacter Detection in the Stomach of Apparently Normal Donkeys: Sampling, Diagnostic Methods, and Implications for Equine Glandular Gastric Disease and Serum Antioxidant Status. Iran J Vet Sci Technol. 2024; 16(2): 50-56.

DOI: <https://doi.org/10.22067/ijvst.2024.87403.1366>

URL: https://ijvst.um.ac.ir/article_45251.html