



Histopathological, ultrastructural and molecular examination of *Sarcocystis* spp. in sheep of Mashhad area, Khorasan Razavi province, Iran

Hamed Rad, Hossein Nourani, Gholam Reza Razmi

Department of Pathobiology, Faculty of Veterinary Medicine, Ferdowsi University of Mashhad, Mashhad, Iran.

ABSTRACT

This study aimed to determine and identify *Sarcocystis* spp. infection in sheep of Mashhad city, Iran. From October 2018 to May 2019, the entire esophagus and diaphragm from 100 slaughtered sheep were collected from the Mashhad abattoir. Initially, samples were inspected by the naked eye for the presence of macrocysts. Also, all samples were examined for *Sarcocystis* spp. by tissue impression smear, histopathology, and PCR tests. Additionally, eight samples were inspected by transmission electron microscopy (TEM) and gene sequencing to confirm species identification. The infection rate of sarcocystosis by impression smear, histopathology, and PCR methods were 69%, 96%, and 100%, respectively. Histopathological examination revealed the existence of *S. gigantea* macrocyst with PAS-positive secondary cyst wall in 26% of sheep. Also based on cyst wall morphology, two types of microcysts including *S. tenella* with striated thick cyst wall and *S. arieticanis* with smooth thin cyst wall were identified in 47% and 11% of sheep, respectively. By TEM, the cyst wall of *S. gigantea* had cauliflower-like, *S. tenella* had finger-like and *S. arieticanis* had hair-like villar protrusions. Comparative analyses of the sequencing of the 18S rRNA gene revealed *S. gigantea*, *S. tenella*, and *S. arieticanis* in PCR samples. The results showed that the infection rate of *Sarcocystis* spp. was very high by the PCR method. Also, the existence of *S. gigantea*, *S. tenella*, and *S. arieticanis* species was confirmed by histopathology, TEM, and DNA sequencing methods in sheep of this area.

Keywords

sheep, sarcocystis, morphology, ultrastructure, 18S rRNA, Mashhad

Abbreviations

CNS: central nervous system
TEM: transmission electron microscopy
PCR: polymerase chain reaction
spp.: species
HE: hematoxylin eosin

PAS: periodic acid schiff
µm: micrometer
nm: nanometer
M: molar
h: hour

Number of Figures: 6
Number of Tables: 2
Number of References: 39
Pages: 1-9

Introduction

Sarcocystis spp. are cyst-forming tissue parasites that can infect the striated muscle of humans and numerous domestic and wild herbivores. This protozoan is a heterogeneous and two-host prey-predator life cycle. The carnivores as predator animals are definitive hosts and herbivores as prey animals are intermediate hosts. Sheep (*Ovis aries*) can act as intermediate hosts for four *Sarcocystis* spp. Among *Sarcocystis* species, *S. tenella* and *S. arieticanis* are pathogenic and create microscopic cyst, and transmitted by canids whereas *S. gigantea* and *S. medusiformis* are non-pathogenic and create macroscopic cysts and transmitted by felids [1,2].

Although sarcocystosis is asymptomatic and sporadic in infected sheep with clinical signs, the presence of macroscopic cysts in sheep has a major economic impact due to condemnation of part or the whole infected carcasses in slaughterhouses [3]. The Khorasan Razavi province with more than 6 million sheep has the largest population of sheep in Iran [4]. In Iran, many studies have been reported the high prevalence of *Sarcocystis* spp. infection in sheep by conventional methods such as parasitological, pathological, and molecular methods [5–14]. However, to the best of our knowledge the infection rate of *Sarcocystis* spp. and identify species that infect sheep in Khorasan Razavi Province is unknown. Therefore, the major aims of the current study were to determine the frequency of infection and identify *Sarcocystis* species in sheep of Mashhad city, Khorasan Razavi province, Iran.

Results

Macroscopic study

At the gross inspection, macrocysts were found in 26 of 100 sheep (26%). The highest frequency of macrocysts was detected in the esophagus (26%) (Table 1). Macroscopic sarcocysts were milky white, elongated, and spindle-shaped in the diaphragm and round to oval-shaped in the esophagus (Figure 1). *Sarcocystis*

gigantea was identified by histological evaluation of *Sarcocystis* macrocysts in 26 sheep (26%).

Microscopic examination

Out of 100 sheep with or without macrocysts that were examined with tissue impression smear technique and routine histopathology technique (HE), the bradyzoites of *Sarcocystis* were detected in 69% and 96% of examined sheep, respectively (Table 1). The morphological features of *S. gigantea* had a thin cyst wall as primary cyst wall surrounded by a thick PAS positive secondary cyst wall. The cyst was separated by septa to different compartments and contained ovoid-shaped merozoites and numerous bradyzoites (Figure 2).

Histopathological examination of esophagus and diaphragm sections showed slender or oval-shaped *Sarcocystis* microcysts with numerous bradyzoites that were separated by septa and had variable sizes. These variations were dependent on the angle of tissue sections. A higher rate of positive sheep with microcyst was found using histopathology compared to the tissue impression smear ($p < 0.05$). Two types of microcysts were identified according to the thickness of the cyst wall. One of them had radially-striated thick walls that were identified as *S. tenella* and the other had smooth thin-wall microcysts that were identified as *S. arieticanis* (Figures 3 and 4). The morphological wall details could not be accurately visualized by light microscopy. Microcysts of *S. tenella* and *S. arieticanis* were found in 47 sheep (47%) and 11 sheep (11%), respectively. In addition, 38 sheep (38%) were infected with both types of microscopic sarcocyst.

Transmission electron microscopy

Identification of *Sarcocystis* spp. in tissues was mainly based on ultrastructural features of villar protrusions in cysts walls according to the classification by Dubey et al. [2]. Tissue cysts collected from eight animals were tested by Transmission electron microscopy (TEM). Three different types of villar protrusions were observed for cyst walls which were

Table 1.

The frequencies of *Sarcocystis* spp. infection in the esophagus and diaphragm of one hundred slaughtered sheep.

The examined organ muscles	No. of infected animals (%)				
	Macroscopic examination	Impression smear	Histopathology	PCR	Total
Esophagus	26 (26)	69 (69)	96 (96)	100(100)	100
Diaphragm	21 (21)	60 (60)	92 (92)	100(100)	100

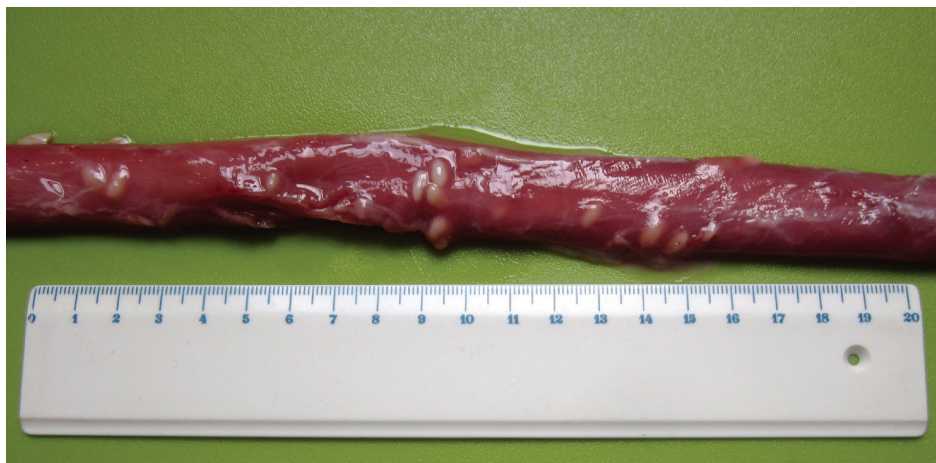

Figure 1.
Esophagus of a sheep showing several macroscopic sarcocysts. The scale is in cm.

identified as *S. gigantea*, *S. tenella*, and *S. arieticanis*. The ultrastructural features of *S. gigantea* macrocysts showed cauliflower-like villar protrusions containing numerous microtubules and the ground substance inside the cyst wall with homogeneous in appearance and 2-3 μm in thickness. The cysts were filled with bradyzoites that were internally separated in different chambers by septa (Figure 5, A and B). The cyst walls of *S. tenella* had finger-like villar protrusions with average lengths up to 1 μm . Finger-like protrusions were positioned closely side by side and distinguished by the electron dense plaques in their apex. Microtubules were absent in the protrusions. A layer of ground substances measuring 0.3-0.6 μm in thickness was located underneath the wall. Bradyzoites were present in the cysts and their amylopectin granules were evident (Figure 5C). The cysts of *S. arieticanis* were identified as having invaginations of cyst wall with hair-like villar protrusions. The cyst wall was thin and measured 0.2-

0.3 μm in thickness and the protrusions were parallel to the direction of the cyst wall surface. The ground substance ranged from 0.4 to 0.6 μm in thickness and was located immediately under the primary cyst wall. The villar protrusions appeared bone-like structures in some locations of the cyst wall (Figure 5D).

Molecular analysis

In this study, all muscle samples were positive for the *Sarcocystis* spp. by PCR. DNA amplified of eight PCR positive samples were purified from the agarose gel and sequenced (Figure 6). The sequences were blasted and submitted to GenBank. PCR alignment of the nucleotide sequences showed 100% similarity with *S. gigantea* accession number MT026574, 99% similarity with *S. tenella* accession number MT026575, and 97% similarity with *S. arieticanis* accession number MT729808 in 18S rRNA sequences in the GenBank database.

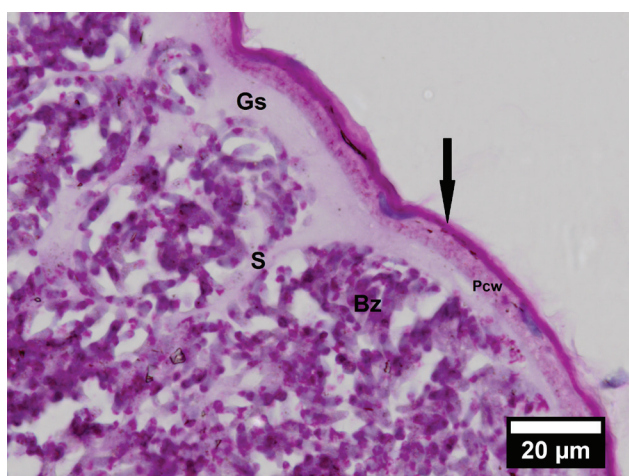

Figure 2.
Sarcocystis gigantea macrocyst in esophagus muscle. Histological section stained with periodic acid Schiff. Magnification: 100 \times . Note secondary thick cyst wall (arrow) that surrounds Primary cyst wall (Pcw). Ground substance (Gc), Septa (S), Bradyzoites (Bz).

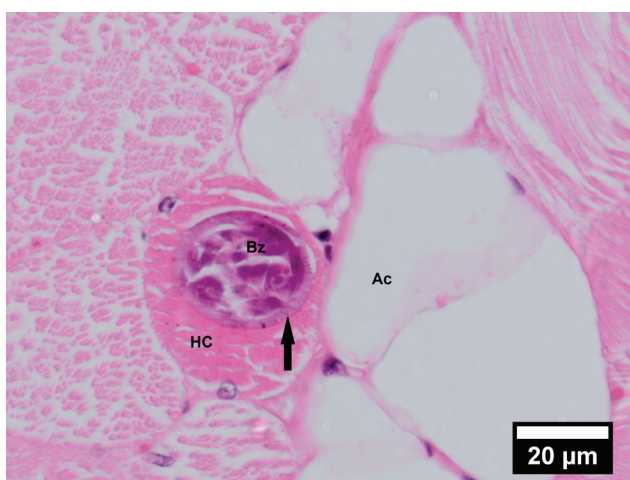

Figure 3.
Histological section of esophagus muscle showing thick-walled microcyst of *S. tenella* with prominent radial striations (arrow) stained with hematoxylin and eosin (HE). Magnification: 100 \times . Note Bradyzoites (Bz), Host cell (Hc), Adipose cell (Ac).

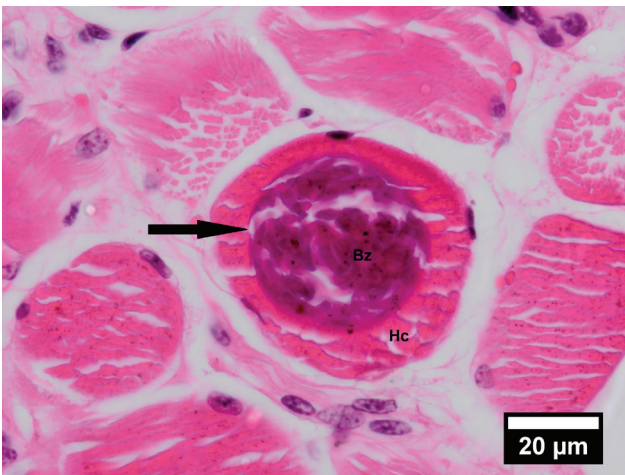


Figure 4. Histological section of diaphragm muscle showing smooth thin-walled microcyst of *S. arieticanis* (arrow) stained with hematoxylin and eosin (HE). Magnification: 100×. Bradyzoites (Bz), Host cell (Hc).

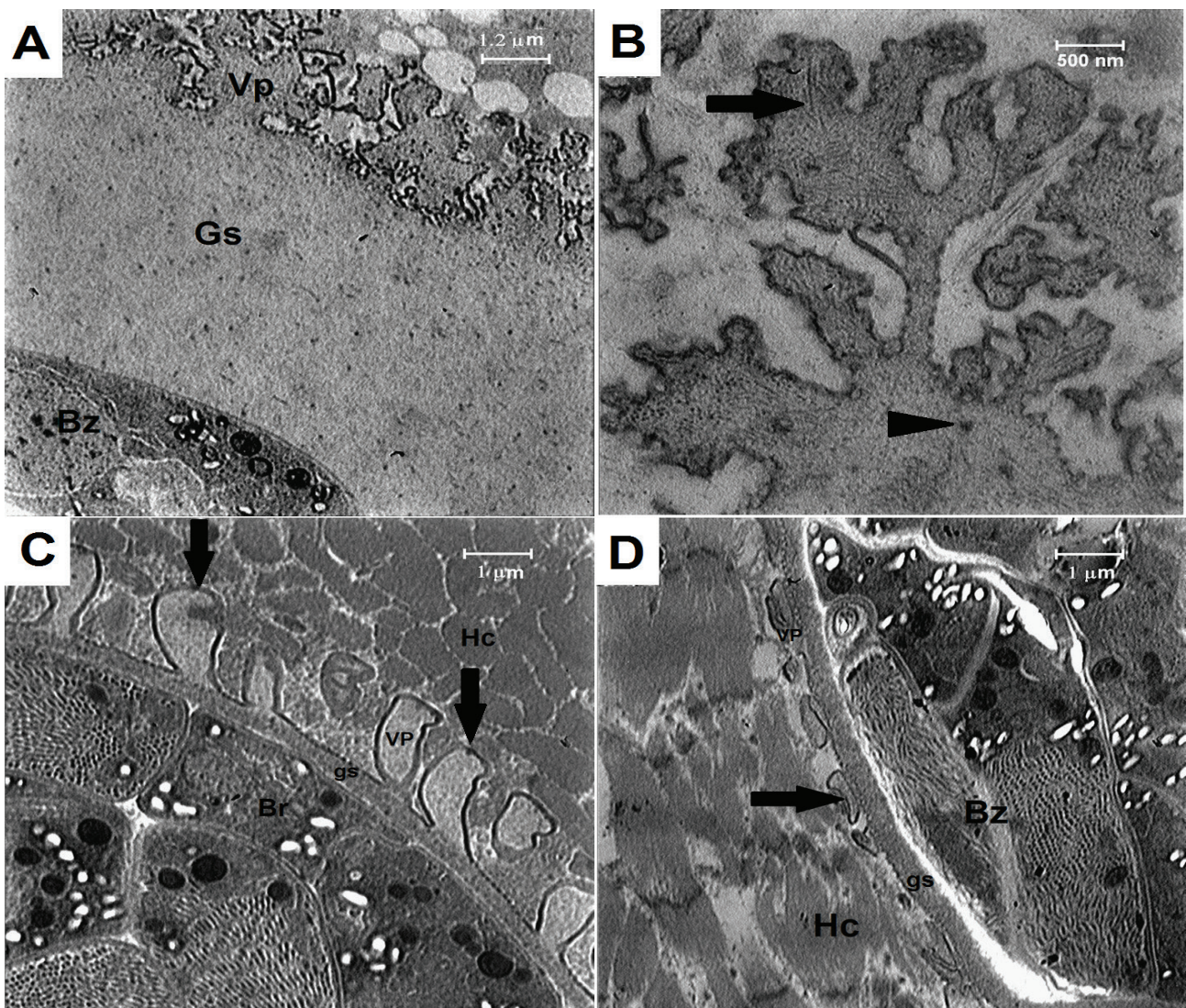


Figure 5. Transmission electron micrographs showing a comparison of villar protrusions on the sarcocyst wall of three species of *Sarcocystis* in sheep. Uranyl acetate and lead citrate stain. A) *S. gigantea* with cauliflower-like villar protrusion. B) Cauliflower-like villar protrusion of *S. gigantea* containing microtubules (arrow) and fine or coarse granules (arrowhead) inside the protrusion. C) *S. tenella* with finger-like villar protrusion. electron-dense plaques are visible (arrows) at the apex of villar protrusions. D) *S. arieticanis* with short hair-like villar protrusions. The villar protrusions appeared bone-like structures in some locations of the cyst wall (arrow). Note Villar protrusion (VP), Ground substance (Gs), Bradyzoites (Bz), Host cell (Hc).

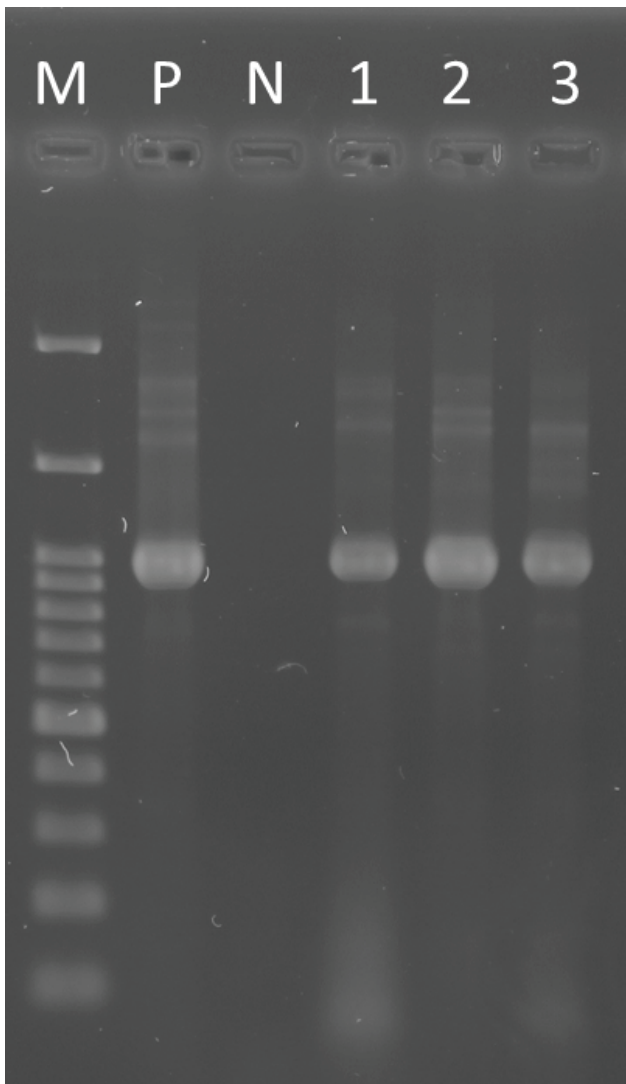


Figure 6. PCR amplification products of *Sarcocystis* spp. in muscle samples. M= Molecular weight marker (100bp ladder); P= Positive control; N= negative control; 1,2,3 positive samples.

Discussion

In this study, *Sarcocystis* spp. cysts were microscopically found via tissue impression smear and routine histopathology techniques. The tissue impression smear as a fast, simple, and applied technique was compared with routine histopathology technique; the latter technique found 27% more infected sheep than the tissue impression smear technique. Although the routine histopathology method is more sensitive than the tissue impression smear and tissue squash methods, it has been shown that the digestive method is more sensitive than the pathology method [15,16]. In addition, the PCR technique has been used to determine the frequency and identify of *Sarcocystis* spp. in tissue samples. All sheep were found infected with *Sarcocystis* spp. by PCR. This finding revealed that PCR is the most accurate and sensitive method for de-

termining the frequency of infection. A regional survey from the Americas in retail beef samples showed that PCR assays may increase the detection sensitivity of *Sarcocystis* spp. and contribute to diagnostic precision [17].

In the present study, macroscopic cysts were found in both esophageal and diaphragmatic muscles. In Iran, the prevalence rates of macrocysts in sheep have ranged from 3.58 % to 36.83 % in abattoir studies carried out in different provinces [8,11,12,18,19]. The highest prevalence of macroscopic cysts incorporated in the esophagus was similar to the studies of other researchers [8,20–22]. In contrast, Farhang-Pajuh et al. [11] found the highest prevalence of macrocysts in the diaphragm samples of slaughtered sheep of Urmia city, Iran. In this study, similar results about infection rate of microcysts were reported in other studies as follows: 97% in Iraq [20], 96.9% in Mongolia [23], 95.8% in Brazil [24], 93% in Ethiopia [25] and 91.9% in China [26]. Ovine microscopic sarcocysts have been reported to be more prevalent than macroscopic *Sarcocystis* species in Iran [8,12,19] and other countries [21,22,27,28].

The histopathologic examinations of macroscopic cysts by light microscopy allowed the identification of *S. gigantea* with PAS-positive secondary cyst wall. This finding is following the results of other studies [22,29,30]. Many studies have shown that *S. gigantea* was the predominant macroscopic species in sheep [28,31]. The use of light microscopy in histological examination permitted the recognition of two types of microcysts based on the thickness of the cyst wall, as described by Dubey et al. [31] and Beyazit et al. [22]. Thick radially striated walled microcysts were identified as *S. tenella* and thin-walled microcysts were identified as *S. arieticanis*. Similar results have been reported by O'Donoghue and Ford [32]. In the present study, the frequency of *S. tenella* microcysts was more than *S. arieticanis*. Some researchers have found that *S. tenella* was the predominant species in sheep [1,15,28,31]. A study showed that 80% of slaughtered sheep were infected with *S. tenella* in the southwest of Iran [14].

The use of TEM to study the ultrastructure of sarcocyst walls is a crucial taxonomic criterion for the identification and differentiation of species of *Sarcocystis* in infected animals [24,33]. The ultrastructural features of sarcocyst wall in our samples were consistent with the cyst wall ultrastructure *S. gigantea*, *S. tenella*, and *S. arieticanis* that classified by Dubey et al. [2]. The observation of cauliflower-like villar protrusions in macroscopic cyst samples permitted the identification of *S. gigantea* cysts and was similar to that described previously for this species in sheep [30,34,35]. The villar protrusions in microcyst with

finger-like or palisade-like protrusions allowed the identification of *S. tenella* and the villar protrusions in other microcyst with hair-like morphology were confirmed as *S. arieticanis*. These findings were similar to those described by Odening et al. [34] and El-Morsey et al. [1].

In the present study, nucleotide sequencing of the 18s rRNA genetic marker of PCR products was done in eight samples. The DNA acquired from individual cysts allowed the identification of *S. gigantea*, *S. tenella*, *S. arieticanis* in selected samples.

In conclusion, the current investigation showed a high frequency of infection by *Sarcocystis* spp. that form macroscopic and microscopic cysts in sheep slaughtered for human consumption in the Mashhad area. We report *S. tenella* and *S. arieticanis* by TEM for the first time in Iran. The high frequency of *Sarcocystis* spp. indicates the importance of infection in sheep as intermediate hosts. On the other hand, the frequency of microscopic sarcocysts was determined more than macroscopic sarcocysts infection. The result showed the important role of sentinel dogs to induce sarcocystis infection in sheep.

Materials & Methods

Samples collection

From October 2018 to May 2019, tissue samples of the esophagus and diaphragm were collected from sheep (> 2 years) in a slaughterhouse in Mashhad city, the capital of Khorasan Razavi Province where is located at 36.18° north latitude and 59.36° east longitude, Iran. The collected samples of each sheep were separately kept in sealed plastic bags and transported in boxes containing ice packs to the laboratory of pathobiology, Faculty of Veterinary Medicine, Ferdowsi University of Mashhad, Iran. For calculating sample size with an expected infection frequency of 90% and confidence interval of 95 % and desired absolute accuracy of 5 %, one hundred sheep were randomly selected [36]. All specimens were obtained from the sheep carcasses after they were slain in the slaughterhouse under instructions of the Iran Veterinary Organization and its regular commercial routine for meat production for human use in the internal Iranian market. So, there was not required specific ethics approval.

Macroscopic examinations

In the laboratory, all tissue samples were grossly examined by the naked eye for the existence of macroscopic cysts. For better visualization of the macroscopic cysts in muscle depth, in diaphragm samples at least 15 transversal sections were made with a scalpel and in esophagus samples longitudinally cuts were done with the scissor.

Tissue impression smears

The cut surface of each fresh tissue sample was pressed on a glass slide, then fixed with absolute methanol, and finally stained with Giemsa and examined for the existence of free bradyzoites by a light microscope at × 40 and × 100 magnification [37].

Histopathologic examination

First, two pieces from each esophagus and diaphragm samples, with or without macrocysts were fixed in 10 % neutral buffered formalin, then dehydrated in graded ethanol alcohol series, finally embedded in paraffin and made the paraffin wax blocks. The tissue sections were prepared from the paraffin wax blocks by tissue processor and stained conventionally with hematoxylin and eosin (HE). Selected tissue sections with macrocysts were also stained with periodic acid Schiff (PAS). Histological slides were examined for sarcocysts and their wall features by light microscopy.

Transmission electron microscopy

Samples from eight sheep included two esophagus samples that contained macrocyst, two esophagus samples contained microcyst, two diaphragm samples contained macrocyst and two diaphragm samples contained microcyst were prepared for TEM. The Specimens were fixed with 2.5 % glutaraldehyde solution in 0.1 M sodium cacodylate buffer (pH 7.4) at least for 2 h at room temperature and stored refrigerated overnight. After fixation, the samples were washed three times in sodium cacodylate buffer 0.1 M (pH 7.4), then post-fixed in 1 % osmium tetroxide for 2 h at room temperature, dehydrated in graded ethanol [30, 40, 50, 70, 90, and 100 %], transferred to propylene oxide for 1 h and finally embedded in Epoxy Resin then polymerization at 60 °C for 72 h in an oven. After polymerization, semithin sections (1 μm) were cut with an ultramicrotome (Ultracut R, Leica, Austria) and stained with toluidine blue to determine the area of *Sarcocystis* spp. cysts. Also, the ultrathin sections (80 nm) from the cyst area were stained with uranyl acetate and lead citrate and examined using a Zeiss Leo 912 AB transmission electron microscope at 120 kV[24,38].

DNA extraction and PCR method

Genomic DNA of each sheep sample was extracted via commercial MBST Blood and Tissue Genomic DNA isolation kit (Molecular Biological System Transfer, Iran) followed according to manufacturer's instructions. The extracted DNA was stored at -20°C until use. Each reaction was carried out in a total volume of 25μL, containing 1 μL of the sample DNA, 0.5 μL of each primer, and 12.5 μL of PCR Master Mix. The conventional PCR was performed to amplify a fragment of the subunit 18S ribosomal RNA (18S rRNA) gene of *Sarcocystis* spp. with the forward (1L) and reverse (3H) primer pair (Table 2). The PCR was performed in a thermal cycler (Bio-Rad, USA) as follows: 95°C for 2 min, followed by 40 cycles of 94°C for 40 s, 50-57°C for 1 min, 72°C for 1 min, followed by 72°C for 6 min [39]. The PCR products were electrophoresed in 1.5 % agarose gels, then stained with ethidium bromide and observed under ultraviolet light. DNA was extracted from macrocyst of *Sarcocystis* spp. from an infected sheep as positive control and ultrapure water as negative control were included in each experiment.

Gene sequencing

The amplicons were purified from the gel bands using the Gel extraction kit (Dena Zist Asia, Iran) as per manufacturers' instructions. Concentrations of the PCR products were evaluated by spectrophotometry (Nanodrop ND1000). The purified PCR products were submitted for sequencing (Faza Pajooch Co. Tehran, Iran). The 18S rRNA gene nucleotide sequences were assembled and edited using CLC bio software (CLC Main Workbench, Qiagen, Aarhus). The nucleotide sequences in the present study were aligned with previously described sequences of *Sarcocystis* spp. in GeneBank (NCBI) using the Clustal W method (Mega software version 6). The nucleotide sequences obtained in this study were deposited in GenBank (NCBI).

Table 2.
PCR primers used for amplification of 18S rRNA genes in *Sarcocystis* spp.

Primer name	Orientation	Sequence (5'→3')	Length (bp)	Product size (bp)	Annealing temperature (°C)	Reference
Primer 1L	Forward	CCATGCATGTCTAAGTATAAGC	22	900	55	39
Primer 3H	Reverse	GGCAAATGCTTTCGCAGTAG	20			

Statistical analysis

To compare two microscopic methods the tissue impression smear technique and routine histopathology technique, the McNemar test was used. The SPSS version 25.0 (IBM Corp., USA) was used for statistical analysis. Values of $p < 0.05$ was considered

Authors' Contributions

Conceived and designed the experiments and revised the manuscript draft: H.N., G.R.R. performed the experiments, analysed the data and drafted the manuscript: H.R. All authors approved the final version of the manuscript.

Acknowledgments

This work was financially supported by a research grant (project code: VPRTFM-3/44040) from the Ferdowsi University of Mashhad, Mashhad, Iran.

Competing Interests

The authors declare that there is no conflict of interest.

References

- El-Morsey A, Abdo W, Sultan K, Elhawary NM, AbouZaid AA. Ultrastructural and Molecular Identification of the sarcocysts of *Sarcocystis tenella* and *Sarcocystis arieticanis* Infecting Domestic Sheep (*Ovis aries*) from Egypt. *Acta Parasitol.* 2019;64(3):501–13.
- Dubey JP, Calero-Bernal R, Rosenthal BM, Speer CA, Fayer R. *Sarcocystosis of animals and humans*, second edition. CRC Press; 2015:1-234.
- Martínez-Navalón B, Anastasio-Giner B, Cano-Fructuoso M, Sanchez-Martínez P, Llopis-Morant A, Perez-Castarlenas B, et al. Sarcocystis infection: a major cause of carcass condemnation in adult sheep in Spain. *Spanish J Agric Res.* 2012;10(2):388.
- Annual agricultural statistics [Internet]. Ministry of Jihad-e-Agriculture of Iran; 2019. Available from: <http://www.maj.ir>
- Oryan A, Ahmadi N, Mousavi SMM. Prevalence, biology, and distribution pattern of *Sarcocystis* infection in water buffalo (*Bubalus bubalis*) in Iran. *Trop Anim Health Prod.* 2010;42(7):1513–8.
- Daryani A, Alaei R, Dehghan MH, Arab R, Sharif M, Ziaei H. Survey of *Sarcocystis* infection in slaughtered sheep and buffaloes in Ardabil, Iran. *Journal of Animal and Veterinary Advances.* 2006; 5(1):60-62.
- Rassouli M, Ahmadpanahi J, Alvandi A. Prevalence of *Sarcocystis* spp. and *Hammondia* spp. microcysts in esophagus tissue of sheep and cattle, emphasized on their morphological differences. *Parasitol Res.* 2014;113(10):3801–5.
- Mirzaei M, Rezaei H. The role of sheep in the epidemiology of *Sarcocystis* spp. in Tabriz area northwest of Iran. *J Parasit Dis.* 2016;40(2):285–8.
- Parandin F, Feizi F, Maghsood A, Matini M, Roshan A, Fallah M. A survey on *Sarcocystis* infection rate in slaughtered cattle and sheep by macroscopic inspection and pepsin digestion methods in Hamadan abattoir, Iran, 2014. *Avicenna J Clin Med.* 2015;22(3):210–6.
- Bahari P, Salehi M, Seyedabadi M, Mohammadi A. Molecular identification of macroscopic and microscopic cysts of *Sarcocystis* in sheep in North Khorasan province, Iran. *Int J Mol Cell Med.* 2014;3(1):51–6.
- Farhang-Pajuh F, Yakhchali M, Mardani K. Molecular determination of abundance of infection with *Sarcocystis* species in slaughtered sheep of Urmia, Iran. *Vet Res Forum.* 2014;5(3):181–6.
- Kalantari N, Khaksar M, Ghaffari S, Hamidekis SM. Molecular analysis of *Sarcocystis* spp. isolated from sheep (*Ovis aries*) in Babol area, Mazandaran province, Northern Iran. *Iran J Parasitol.* 2016;11(1):73–80.
- Dalimi AAH, Paikari HA, Esmaeilzadeh M, Valizadeh M, Karimi GHR, Motamedi GHR, et al. Identification of *Sarcocystis* species of slaughtered sheep in Qazvin Ziaran slaughterhouse using PCR-RFLP. *Modares J Med Sci.* 2008;11(1–2):65–72.
- Rahdar M, Kardooni T. Molecular identification of *Sarcocystis* spp. in sheep and cattle by PCR-RFLP from southwest of Iran. *Jundishapur J Microbiol.* 2017;10(8). Available from: <http://10.5812/jjm.12798>

15. Dong H, Su R, Wang Y, Tong Z, Zhang L, Yang Y, et al. *Sarcocystis* species in wild and domestic sheep (*Ovis ammon* and *Ovis aries*) from China. *BMC Vet Res*. 2018;14(1):1–7.
16. Calero-Bernal R, Verma SK, Oliveira S, Yang Y, Rosenthal BM DJ. In the United States, negligible rates of zoonotic sarcocystosis occur in feral swine that, by contrast, frequently harbour infections with *Sarcocystis miescheriana*, a related parasite contracted from canids. *Parasitology*. 2015;142:549–56.
17. Pritt B, Trainer T, Simmons-Arnold L, Evans M, Dunams D, Rosenthal BM. Detection of *Sarcocystis* parasites in retail beef: A regional survey combining histological and genetic detection methods. *J Food Prot*. 2008;71(10):2144–7.
18. Oryan A, Moghaddar N, Gaur SNS. The distribution pattern of *Sarcocystis* species, their transmission and pathogenesis in sheep in Fars province of Iran. *Vet Res Commun*. 1996;20(3):243–53.
19. Mirzaei Dehaghi M, Fallahi M, Sami M, Radfar MH. Survey of *Sarcocystis* infection in slaughtered sheep in Kerman Abattoir, Kerman, Iran. *Comp Clin Path*. 2013;22(3):343–6.
20. Latif BMA, Al-Delemi JK, Mohammed BS, Al-Bayati SM, Al-Amiry AM. Prevalence of *Sarcocystis* spp. in meat-producing animals in Iraq. *Vet Parasitol*. 1999;84(1–2):85–90.
21. Pipia AP, Varcasia A, Zidda A, Dessi G, Panzalis R, Tamponi C, et al. Cross-sectional investigation on sheep sarcosporidiosis in Sardinia, Italy. *Vet Parasitol Reg Stud Reports*. 2016;3–4:13–7.
22. Beyazit A, Yazıcıoğlu Ö KZ. The prevalence of ovine *Sarcocystis* species in Izmir province. *Ankara Üniversitesi Vet Fakültesi Derg*. 2007;50(1):1–1.
23. Fukuyo M, Battsetseg G, Byambaa B. Prevalence of *Sarcocystis* infection in meat-producing animals in Mongolia. *South-east Asian J Trop Med Public Health*. 2002;33(3):490–5.
24. Bittencourt MV, Meneses IDS, Ribeiro-Andrade M, de Jesus RF, de Araújo FR, Gondim LFP. *Sarcocystis* spp. in sheep and goats: frequency of infection and species identification by morphological, ultrastructural, and molecular tests in Bahia, Brazil. *Parasitol Res*. 2016;115(4):1683–9.
25. Woldemeskel M, Gebreab F. Prevalence of *Sarcocysts* in livestock of northwest Ethiopia. *J Vet Med Ser B*. 1996;43(1-10):55–8.
26. Hu JJ, Huang S, Wen T, Esch GW, Liang Y, Li HL. *Sarcocystis* spp. in domestic sheep in Kunming City, China: Prevalence, morphology, and molecular characteristics. *Parasite*. 2017;24:30.
27. Mahran OM. *Sarcocystis* infection in sheep and goats slaughtered in Shalatin Abattoir, Red Sea Governorate, Egypt. *Asiut Vet Med J*. 2009;55(121):341–55.
28. Minuzzi CE, Cezar AS, Bräunig P, Portella LP, Rodrigues F de S, Sangioni LA, et al. Occurrence of *Sarcocystis gigantea* macrocysts and high frequency of *S. tenella* microcysts in sheep from southern Brazil. *Vet Parasitol Reg Stud Reports* [Internet]. 2019;15(November 2018):100256. Available from: <https://doi.org/10.1016/j.vprsr.2018.12.002>
29. Moore S. Two types of ovine sarcocystis macrocysts distinguished by periodic acid-schiff staining of the cyst walls. *N Z Vet J*. 1980;28(5):101–2.
30. Munday BL, Obendorf DL. Morphology of *Sarcocystis gigantea* In Experimentally-Infected Sheep. *Vet Parasitol*. 1984;16:193–9.
31. Dubey JP, Lindsay DS, Speer CA, Fayer R, Livingston CW. *Sarcocystis arieticanis* and other *Sarcocystis* species in sheep in the United States. *J Parasitol*. 1988;74(6):1033.
32. O'Donoghue PJ, Ford GE. The prevalence and intensity of *Sarcocystis* spp infections in sheep. *Aust Vet J*. 1986;63(9):273–8.
33. Cerqueira-Cézar CK, Thompson PC, Murata FHA, Mowery J, Brown JD, Banfield J, et al. Histopathological, morphological, and molecular characterization of *Sarcocystis* species in elk (*Cervus elaphus*) from Pennsylvania, USA. *Parasitol Res*. 2018;117(10):3245–55.
34. Odening AK, Stolte M, Walter G, Bockhardt I. Cyst Wall Ultrastructure of Two *Sarcocystis* spp. from European Mouflon (*Ovis ammon musimon*) in Germany Compared with Domestic Sheep. *J Wildl Dis*. 1995;31(4):550–4.
35. Collins GH, Atkinson E, Charleston WAG. Studies on *Sarcocystis* species III: The macrocystic species of sheep. *N Z Vet J*. 1979 Oct 1;27(10):204–6.
36. Thrusfield M. *Veterinary Epidemiology*, Iowa State. Iowa State: University Press; 1997:228-246.
37. Urquhart GM, Armour J, Duncan JL, Dunn AM JF. *Veterinary parasitology*. Blackwell Science Ltd; 2nd Revised edition; 1996:238-240.
38. Kuo J. *Electron microscopy: methods and protocols*, Second Edition. Tatowa: Humana press; 2007:19-33.
39. Yang ZQ, Zuo YX, Yao YG, Chen XW, Yang GC, Zhang YP. Analysis of the 18S rRNA genes of *Sarcocystis* species suggests that the morphologically similar organisms from cattle and water buffalo should be considered the same species. *Mol Biochem Parasitol*. 2001;115(2):283–8.

COPYRIGHTS

©2021 The author(s). This is an open access article distributed under the terms of the Creative Commons Attribution (CC BY 4.0), which permits unrestricted use, distribution, and reproduction in any medium, as long as the original authors and source are cited. No permission is required from the authors or the publishers.

**How to cite this article**

Rad H, Nourani H, Razmi GR (2020). Histopathological, ultrastructural and molecular examination of *Sarcocystis* spp. in sheep of Mashhad area, Khorasan Razavi Province, Iran. Iran J Vet Sci Technol. 12(2):1-9
DOI: <https://doi.org/10.22067/veterinary.v12i2.88245>.
URL: https://ijvst.um.ac.ir/article_30768.html

بررسی هیستوپاتولوژی، فراساختاری و مولکولی گونه های سارکوسیستیس در گوسفندان شهر مشهد، استان خراسان رضوی، ایران

حامد راد، حسین نورانی، غلامرضا رزمی

گروه پاتوبیولوژی، دانشکده دامپزشکی، دانشگاه فردوسی مشهد، مشهد، ایران.

چکیده

هدف این مطالعه تعیین و شناسایی آلودگی به گونه های سارکوسیستیس در گوسفندان شهر مشهد، ایران بود. از مهر سال ۱۳۹۷ تا اردیبهشت ۱۳۹۸، مری و دیافراگم ۱۰۰ گوسفند از کشتارگاه مشهد جمع آوری گردید. ابتدا نمونه ها از نظر حضور کیست های ماکروسکوپی توسط چشم غیرمسلح بررسی شد. همچنین تمامی نمونه ها از نظر وجود گونه های سارکوسیستیس توسط تست های اسمیر فشاری بافت، هیستوپاتولوژی و PCR ارزیابی شدند. به منظور تأیید گونه های یافته شده، تعداد هشت نمونه بوسیله میکروسکوپ الکترونی عبوری و روش تعیین توالی ژن مطالعه گردید. میزان آلودگی به سارکوسیستوزیس در روش های اسمیر فشاری، هیستوپاتولوژی و PCR به ترتیب ۶۹٪، ۹۶٪ و ۱۰۰٪ بود. بررسی هیستوپاتولوژی وجود ماکروکیست های *S. gigantea* با دیواره ثانویه PAS مثبت را در ۲۶٪ از گوسفندان نشان داد. همچنین طبق مورفولوژی دیواره کیست، دو نوع میکروکیست شامل *S. tenella* با دیواره ضخیم مخطط و *S. arietcanis* با دیواره نازک صاف به ترتیب در ۴۷٪ و ۱۱٪ گوسفندان شناسایی شد. در مطالعه TEM، زوائد دیواره کیست های *S. gigantea* گل کلمی، *S. tenella* انگشتی و *S. arietcanis* مویی شکل بودند. بررسی مقایسه ای توالی ژن *SrRNA*، گونه های *S. tenella*، *S. gigantea* و *S. arietcanis* را توسط PCR تایید نمود. نتایج مطالعه حاضر نشان داد که میزان آلودگی به گونه های سارکوسیستیس در روش PCR بسیار بالا بود. همچنین وجود گونه های *S. tenella*، *S. gigantea* و *S. arietcanis* توسط روش های هیستوپاتولوژی، TEM و تعیین توالی DNA در گوسفندان این منطقه تایید گردید.

واژگان کلیدی

گوسفند، سارکوسیستیس، مورفولوژی، فراساختار، 18SrRNA، مشهد