



## Uterine Horn Intussusception in a Chihuahua Bitch

Samaneh Ghasemi , Mohammad Reza Emami , Ali Mirshahi, Pouria Khanzadeh, Sina Yal Beyranvand, Mohammad Mahdi Zarezadeh

Department of Clinical Sciences, Faculty of Veterinary Medicine, Ferdowsi University of Mashhad, Mashhad, Iran.

### ABSTRACT

Uterine horn intussusception has rarely been reported in bitches. However, the pathogenesis is not entirely clear and the incidence of uterine intussusception in bitches is unknown. This disorder occurs during the postpartum period and is a challenging clinical condition in terms of presentation, diagnosis, and management. In this report, a case of uterine horn intussusception is described in a four-year-old female Chihuahua bitch, which presented with abdominal pain, lethargy, anorexia, tremors, recumbency, and ongoing reddish vaginal discharge 20 days after whelping two pups. All the hematological and biochemical test results were within normal ranges except for a decreased calcium level. Ultrasonographic examination revealed the multilayered appearance of the uterine wall. The midline laparotomy confirmed the invagination of a proximal segment of the uterine horn into its distal segment near the uterine body. Ovariohysterectomy was performed as the recommended treatment. This case highlights the importance of assessing abdominal pain to avoid delay in diagnosis and management. Moreover, uterine intussusception should be considered as a differential diagnosis in bitches with the symptoms of abdominal pain during the postpartum period.

### Keywords

*Bitch, Intussusception, Postpartum period, Uterine horn*

Number of Figures: 2  
Number of Tables: 0  
Number of References: 20  
Number of Pages: 5

### Abbreviations

## Introduction

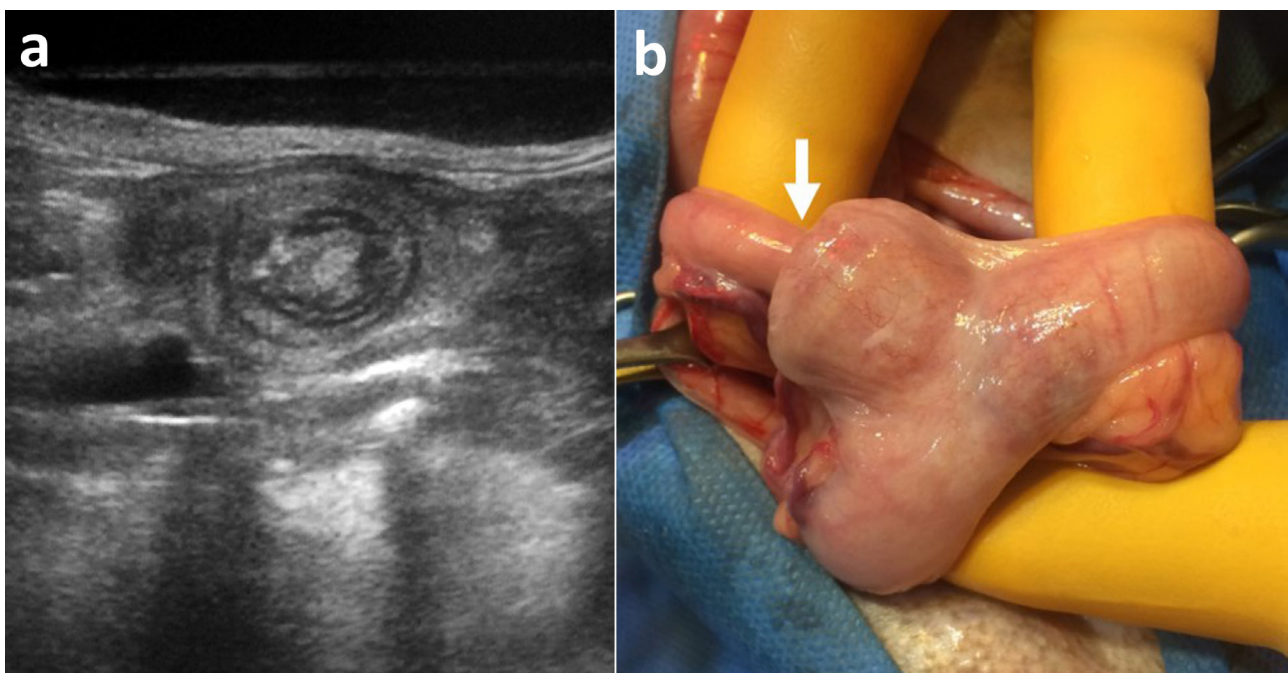
Different acquired disorders can affect the canine uterus during the postpartum period. Some of them include hemorrhage, retained placenta, sub-involution of placental sites, metritis, uterine prolapse, and rupture [1, 2]. Uterine intussusception is a rare acquired disorder in bitches [3]. Therefore, its incidence cannot be estimated exactly. The pathogenesis of uterine intussusception is not very clear. Physiological changes of the uterus during the postpartum period, such as uterus involution and hormonal changes or some pathological conditions, namely dystocia and retention of fetal membranes, may lead to uterine intussusception [3-7]. Diagnosis of this problem is a challenge because of the nonspecific clinical signs and symptoms. This report describes a case of uterine horn intussusception in a Chihuahua Bitch.

## Case Presentation

A four-year-old female Chihuahua was referred with a 24-hour history of lethargy, anorexia, tremors, and recumbency. The patient had a delivery 20 days before with an ongoing reddish vaginal discharge post-parturition. Her two previous pregnancies had been uncomplicated. She had no known trauma history. The bitch was nursing her puppies. On the physical examinations, although panting was initially observed, heart rate and rectal temperature were

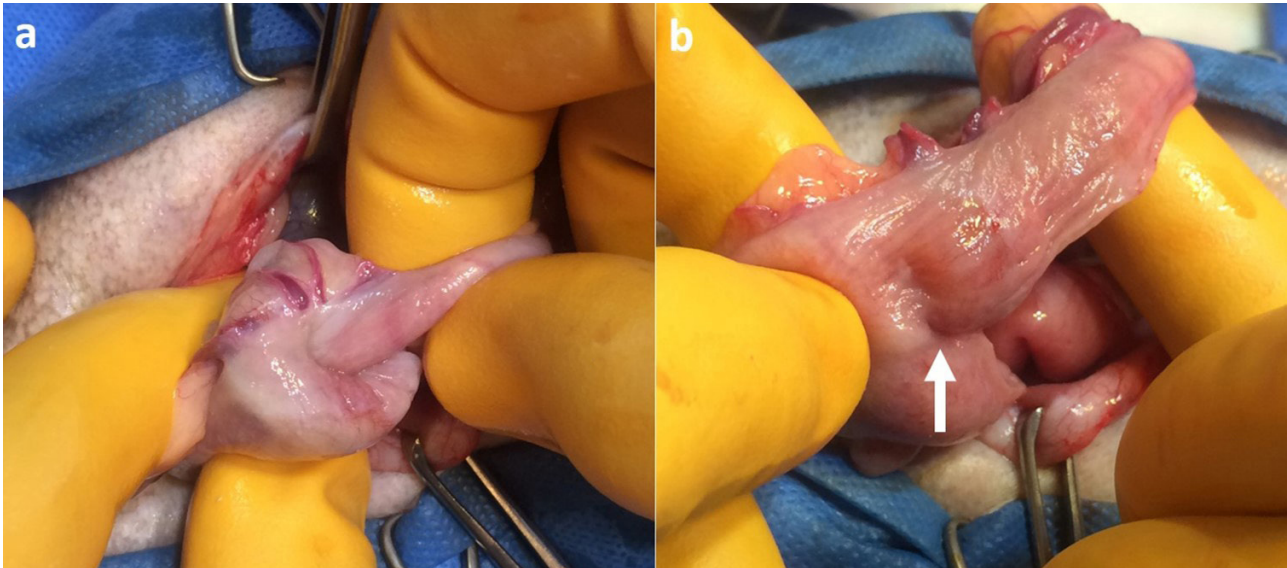
normal. In addition, some stiffness in her limbs and inability to stand was observed, and the palpation of the abdominal region was painful.

For hematological and biochemical assessment, blood samples were collected by venipuncture of the cephalic vein. The results of routine hematological and biochemical tests were within the normal range, except for a decreased calcium level (5.99 mg/dl, reference value: 9-10.8). In caudal abdominal ultrasonography, the multilayered appearance of the uterine wall (concentric rings) was obvious which represented the superimposed wall layers of intussusceptum and intussusciens. Furthermore, echogenic mesenteric fat was noticed in this view. The ultrasonographic findings were suggestive of uterine intussusception (Figure 1a). The surgeons advised a laparotomy, and the dog underwent surgery after her condition was stabilized by fluid therapy, perioperative pain management, oxygen therapy, and intravenous antibiotics. Confirmed surgical findings revealed the invagination of a proximal segment of the right uterine horn into its distal segment near the uterine body which confirmed uterine horn intussusception (Figure 1b). The manual reduction of intussusception was successfully performed by gentle pulling and the retrograde milking of the intussusceptum out of the intussusciens (Figure 2a). The intussusciens segment was distended without any significant abnormalities in the appearance of the affected uterine horn, and no adherence areas were observed (Figure 2b). An ovariohysterec-



**Figure 1.**

a) Transverse ultrasonographic image of uterine intussusception, the inner uterine wall is identified within the outer uterine wall surrounded by echogenic mesenteric fat; b) Right uterine horn intussusception (arrow) near the uterine body



**Figure 2.** a) Manual reduction of the invaginated uterine horn segment by a combination of milking and pulling; b) Uterine horn after the manual reduction of intussusception presenting a slight distention (arrow)

tomy was performed following obtaining the owner's consent.

## Discussion

Uterine intussusception is a rare condition in small animals, which has only been described in a few cases. To date, only less than ten case reports of bitches with this condition were published in the literature. Among these cases, only three were described in the English literature [3, 8, 9], while Brazilian veterinarians have reported three cases in Portuguese [3, 4, 8, 10, 11] and one case in Spanish [12]. The female dogs affected by uterine intussusception have been of various breeds, including Chow Chow [8], Golden Cocker [12], Yorkshire Terrier [10], crossbred [11], American Bully [3], Shih Tzu [4], German Shepherd [9], and Chihuahua. Uterine intussusception has also been previously reported in a nulliparous sheep [13] and a Thoroughbred broodmare [14].

The possible pathogenesis and complete clinical manifestations are not very clear due to the rarity of this condition. The tubular anatomical structure of the uterus and its ability for contraction and expansion may predispose it to intussusception [3]. In the cases of Chow Chow [8] and Yorkshire Terrier [10], the bitches were in the proestrus phase and imminent delivery, respectively. In other case reports [3, 4, 12], uterine intussusception was described in the postpartum period, as for a Chihuahua described in this paper. Therefore, it seems that uterine intussusception predominantly occurs during the postpartum period. This period is characterized by uterine involution which is completed when the uterus diameter re-

turns to the original non-pregnant size. Furthermore, it was suggested that the normal involution process of the uterus is slow in the bitches and can last about 3 months [15]. During the postpartum period, physiological changes, involving the regeneration of the uterine tract [5], distention of uterine ligaments [3], and hormonal changes, including decreased or increased estrogen concentration [4], may be associated with uterine intussusception in this period. Moreover, uncoordinated peristalsis along the uterine tube may contribute to this condition [13, 16]. Uterine horn intussusception may be associated with prolonged dystocia because of the more atonic condition of the uterus [11]. Retained fetal membranes combined with prolonged straining and injudicious traction on a retained fetal membrane are other predisposing factors in this regard. The traction of a retained fetal membrane can invert the tip of the uterine horn, thereby leading to the progression of prolapse [3, 7]. However, in the reported case, parturition was normal.

In the Chihuahua Bitch presented in this paper, abnormally low levels of calcium were observed. Calcium is an essential element for the proper contractions of muscles, including the uterine muscles [17]. Low blood calcium is the leading cause of the poor contraction of the uterus, also known as uterine atony or inertia [2, 18]. Therefore, it seems that hypocalcemia may be implicated in the development of uterine intussusception via uterine inertia. Other hematological and biochemical values were normal in the case presented here. In a previous case of uterine intussusception, decreased hematocrit, the total number of red blood cells, and hemoglobin levels were found [3]. In contrast, in another case report, blood laboratory

analysis showed no changes in the parameters [9].

Uterine intussusception associated with non-specific symptoms makes it challenging to diagnose. The most commonly observed symptoms in previous cases [3, 4, 8-12] and the present case report are weakness, muscle tremors, dyspnea, abdominal pain, and vaginal discharge. Uterine prolapse was another concurrent clinical sign in a bitch [3]. Abdominal discomfort related to uterine intussusception may be caused by compromised circulation and pressure on nerve endings [7]. The uterine intussusception was detected in the right horn of the current case. This condition may develop either on the right horn or the left horn of the uterus. Uterine intussusception was previously reported three times in the right [3, 10, 11] and left [4, 8, 12] uterine horn.

In some previous case reports, the ultrasonography of the abdominal cavity was not performed or was not possible, and a definitive diagnosis was obtained by laparotomy [4, 10]. No signs of uterine intussusception were observed in one case of uterine intussusception in ultrasonography examination [3]. Therefore, it seems that pre-operative diagnosis is rather difficult in such cases. In contrast, the abnormal view of the uterus was visible in our case as the telescoping of concentric rings in ultrasonography was confirmed at surgery. A similar appearance in the abdominal cavity was reported in a case of uterine body intussusception in a bitch [9].

In large animals, such as horses, the manual reduction is often recommended for resolving uterine horn intussusception in affected mares. If the cases become nonresponsive, surgical intervention, including partial or total hysterectomy, is required [7, 19]. There is no defined non-surgical treatment for this condition in bitches. Ovariohysterectomy is the treatment of choice in small animals [20].

In conclusion, uterine intussusception must be considered as a differential diagnosis for abdominal pain in bitches during the postpartum period. This condition is quite rare, which limits the overall knowledge and understanding of this problem. Research on uterine intussusception epidemiology, pathophysiology, and diagnosis is required for effective management.

### **Ethical Approval**

This case reports details the management of a clinical case that was a part of clinical caseload. The owner understood procedure and agrees that results related to investigation or treatment and the high veterinary care has been performed with the consent of the animal owner.

### **Authors' Contributions**

All authors have been involved in writing the article, and accept responsibility for its content.

### **Acknowledgments**

The authors gratefully acknowledge the support and facility provided by the Veterinary Teaching Hospital of Ferdowsi University of Mashhad, Iran.

### **Conflict of Interests**

The authors declare that there is no conflict of interest.

### **References**

1. Purohit GN, Bihani DK, Gauri AA. Management of post-partum genital complications in the bitch. 9-11. In, Proceeding of Indian Society for the advancement of canine practice, International Canine Conference. 9-11 February, Bikaner, Rajasthan, India, 2012.
2. Singh GY, Dutt RA, Kumar SA, et al. Gynaecological problems in she dogs. *Haryana Veterinarian*. 2019;58(S.I.):8-15.
3. da Silva MF, Ilkiu AM, Rossi ES, et al. Uterine intussusception in immediate postpartum in bitches: case report. *Braz J Vet Res Anim Sci*. 2020;57(1):e158398-e158398. Doi:10.11606/issn.1678-4456.bjvras.2020.158398.
4. de Oliveira Néia R, de Mello SS, Gonçalves LPR, et al. Intussuscepção uterina em fêmea canina Shih tzu: Relato de caso (Uterine intussusception in canine female Shih Tzu: Case Report). *Pubvet*. 2021;15(6):181. Doi:10.31533/pubvet.v15n03a767.1-5.
5. Braga Paiano R, Becker Birgel D, Harry Birgel Junior E. Uterine involution and reproductive performance in dairy cows with metabolic diseases. *Animals*. 2019;9(3):93. Doi: 10.3390/ani9030093.
6. Turner RM. Post-partum problems: the top ten list. 306-319. In, Proceedings of the 53rd Annual Convention of the American Association of Equine Practitioners. 1-5 December, Orlando, Florida, USA, 2007.
7. Frazer GS: Post-partum complications in the mare. Part 1: Conditions affecting the uterus. *Equine Vet Educ*. 2003;15(1):36-44. Doi: 10.1111/j.2042-3292.2002.tb01793.x.
8. Gorham MF, Spink RR. Uterine intussusception in a chow chow. *Mod Vet Pract*. 1975;56(1):35.
9. Antonov A. A rare case of uterine body intussusception in a bitch. *EJ-VETMED*. 2022;2(4):1-3. Doi: 10.24018/ejvetmed.2022.2.4.41.
10. Pinto Filho STL, Carus DS, Dalmolin F, et al. Intussuscepção uterina em uma cadela Yorkshire Terrier (Uterine intussus-

Uterine horn intussusception in a bitch

- ception in a Yorkshire terrier bitch). *Arq Bras Med Vet Zootec.* 2015;67(1):37-40. Doi: 10.1590/1678-6590.
11. Silva DF, Carmo LM, Sousa AG, et al. Intussuscepção uterina em uma cadela sem raça definida-relato de caso (Uterine intussusception in a crossbred female dog - case report). *Arq Bras Med Vet Zootec.* 2019;71(05):1531-1534. Doi: 10.1590/1678-4162-10938.
  12. Izquierdo D, Cueto E. Intususcepción uterina. Relato de un caso clínico. *Selecciones Veterinarias.* 2013;21.
  13. Smith C, Parkinson TJ, Long SE. Abattoir survey of acquired reproductive abnormalities in ewes. *Vet Rec.* 1999;144(18):491-146. Doi 10.1136/vr.144.18.491.:
  14. Yang JH, Yang YJ, Kim HS. Intussusception of the uterine horn associated with dystocia in a Thoroughbred broodmare. *Korean J Vet Res.* 2004;44(1):121-124.
  15. Orfanou DC, Ververidis HN, Pourlis A, et al. Post-partum involution of the canine uterus—gross anatomical and histological features. *Reprod Domestic Anim.* 2009;44(2):152-155. Doi: 10.1111/j.1439-0531.2009.01388.x.
  16. Palmieri C, Schiavi E, Della Salda L. Congenital and acquired pathology of ovary and tubular genital organs in ewes: A review. *Theriogenology.* 2010;75(3):393-410. Doi: 10.1016/j.theriogenology.2010.09.020.
  17. Pehlivanoglu B, Bayrak S, Doğan M. A close look at the contraction and relaxation of the myometrium; the role of calcium. *J Turk Ger Gynecol Assoc.* 2013; 14(4): 230. Doi: 10.5152/jtgga.2013.67763.
  18. Frehner BL, Reichler IM, Keller S, et al. Blood calcium, glucose and haematology profiles of parturient bitches diagnosed with uterine inertia or obstructive dystocia. *Reprod Domestic Anim.* 2018;53(3):680-687. Doi: 10.1111/rda.13157.
  19. Tibary A, Pearson LK: Medical problems in the immediate postpartum period. 362-369. In, *Proceedings of the 58th Annual Convention of the American Association of Equine Practitioners*, 1-5 December, Anaheim, California, USA, 2012.
  20. Slatter DH: *Textbook of Small Animal Surgery.* Vol. 2, 3rd ed., 1495, Elsevier Health Sciences, London, 2007.

**COPYRIGHTS**

©2023 The author(s). This is an open access article distributed under the terms of the Creative Commons Attribution (CC BY 4.0), which permits unrestricted use, distribution, and reproduction in any medium, as long as the original authors and source are cited. No permission is required from the authors or the publishers.

**How to cite this article**

Ghasemi S, Emami MR, Mirshahi A, Khanzadeh P, Yal Beyranvand S, Zarezadeh MM. Uterine Horn Intussusception in a Chihuahua Bitch. *Iran J Vet Sci Technol.*2023; 15(1): 1-5.

DOI: <https://doi.org/10.22067/ijvst.2023.80548.1224>

URL: [https://ijvst.um.ac.ir/article\\_42057.html](https://ijvst.um.ac.ir/article_42057.html)