

# Histomorphometric and ultrasonographic evaluations of the rumen in sheep

Mohammad Movahedi Zade<sup>a</sup>, Ahmad Reza Raji<sup>a</sup>, Ali Mirshahi<sup>b</sup>

<sup>a</sup> Department of Basic sciences, Faculty of Veterinary Medicine, Ferdowsi University of Mashhad, Mashhad, Iran  
<sup>b</sup> Department of Clinical Sciences, Faculty of Veterinary Medicine, Ferdowsi University of Mashhad, Mashhad, Iran

## Keywords

ultrasonography, histomorphometry, rumen, sheep

## Abstract

Rumen lesion can lower the performance of the animal and sometimes cause its death. Ultrasonography as a diagnostic method for the detection of lesions in the gastrointestinal tract is considered safe. In this study, three regions of rumen including the dorsal blind sac, ventral blind sac, and pillar [0.5 × 0.5 cm] from 10 healthy sheep rumen were sampled. Histomorphometric study of all samples were performed in the mucosal, submucosal, muscular and serosal layers. For ultrasonographic evaluation, samples from wall of rumen in 6 × 6 cm dimensions were used probe. The results showed that identification of all layers of rumen wall is feasible in sheep by histomorphometry and ultrasonography techniques. Statistical analysis of the data showed no significant correlation between the

parameters of the rumen wall in ultrasonography and histological study. The lack of correlation between ultrasonography and histological data may be due to the tissue changes which would occur during the process of preparing the tissue samples including tissue fixation, dehydration and clearing.

## Abbreviations

L : Lumen  
E : Epithelium  
Vi : Villi  
LP : Lamina properia  
ML-SM: Mucosal and submucosal  
MT : Muscular Tunica  
H&E : Hematoxylin and Eosin

IRANIAN JOURNAL OF VETERINARY SCIENCE AND TECHNOLOGY

Tel: +98 51 3880 3742 Fax: +98 51 3876 3852  
Web: ijvst.um.ac.ir Email: ijvst@um.ac.ir

### Corresponding author:

Ahmad Reza Raji  
Department of Basic Sciences, Faculty of Veterinary Medicine,  
Ferdowsi University of Mashhad, Mashhad, Iran

Email: rajireza@um.ac.ir

## Introduction

---

Ruminant stomach has developed four separate compartments, each with its own morphologic particularities. The first three parts are rumen, reticulum and omasum; commonly known as forestomach [1]. There has been considerable research into the organization of the stomach in cattle [2], sheep and deer [3], and goat [4, 5]. The rumen is itself sacculated by muscular pillars into what are called the dorsal, ventral, caudodorsal, and caudoventral blind sacs. The rumen has a keratinized stratified squamous epithelium. It is non-glandular and has no lamina muscularis. There are two thick layers of tunica muscularis, the inner circular and the outer longitudinal [6]. The anterior surface of rumen forms numerous papillae. The papilla can be long and foliated and pointed. They are up to 6 mm in length. Animal fed on rough grass or in the dry season have longer papillae, whereas animals fed on digestible feed or in wet season have shorter papillae.

Ultrasonography is a diagnostic imaging technique based on the application of ultrasound. Compared to other prominent methods of medical imaging, ultrasound has several advantages. It provides images in real-time, it is substantially lower in cost, and it does not use harmful ionizing radiation. Ultrasonography has been successfully employed in commercial livestock for the past 30 years to determine fetal number and gestation length, permitting more precise feeding and management during late gestation [7]. Ultrasonography examination can also yield important clinical information of lesion in the chest [8], reticulum [9], forestomach [10], liver [11], bladder and kidney. [12]. Ultrasonography is an ideal diagnostic tool for the investigation of bovine gastrointestinal disorders, the most common of which are traumatic reticuloperitonitis, left and right displacement of the abomasum, ileus of the small intestine, and dilatation and displacement of the cecum [13].

In ultrasonographic images, rumen was seen in the vicinity of the wall of abdomen and its wall is seen as an echogenic thick and smooth line. The structures between its wall and skin body is clearly specified using this technique, however, identification of rumen layers have not been reported [14].

Ultrasonographic examination of abomasum in 50 normal healthy cows showed that ultrasonography is a valuable technique for determining the size, location and content of the abomasum. In

most cases, the wall of abomasum was seen as a thin line and also some of its folds were seen like echogenic line structures [15]. Ultrasonographic study of the abomasum in Holstein calves fed before and after the ingestion of milk showed milk clots with clear margin. [16].

The morphological changes in the reticulum were examined by ultrasonography and radiography in 26 cows with traumatic reticuloperitonitis. Radiography revealed foreign bodies penetrating the reticulum of 12 cows and magnets in the reticulum of seven cows. None of these foreign bodies or magnets could be visualized by ultrasonography. Ultrasonographic examination to confirm the diagnosis in animals with unclear and abomasum displacement have also been useful [17].

Ultrasonographic examination of digestive system in 21 normal healthy camels provided highly useful information of ultrasonographic appearance of the digestive system which can be as a reference in suspected cases with malformation of the gastrointestinal tract. In this report, the differentiation between the renal cortex and medulla was also clearly visible in the ultrasonograms [18].

Regarding the lack of ultrasonographic data about rumen layers, this study was aimed to associate histomorphometry and ultrasonography findings in the rumen.

## Results

---

In the histological images of the rumen, the different layers were determined such as, epithelium, lamina propria, tunica mucosa and submucosa, tunica muscularis and serosa (Figures 1, 2, and 3). We concluded that highest average diameter of the mucosa and submucosa was seen in the ventral blind sac of rumen, the highest average diameter of muscle and serous in pillar, and maximum diameter of the walls in pillar (Table 1).

In the ultrasonography, the mucosal and submucosal layers of the rumen were hyperechoic than muscular layer; the serosal layer was isochoic to mucosal and submucosal layer. Muscular layer was observed hypoechoic in the wall of the rumen (Figures 4, 5, 6). According to the ultrasonographic measurements of the rumen wall in its different areas, the diameter of rumen had the highest average in pillars, dorsal blind sac and ventral blind sac. The average diameter of the mucosa and submucosa layers was the highest in the ventral blind sac, dorsal blind sac and pillars and the average di-

ameter of the muscular and serous layers was highest in the pillar, dorsal blind sac and ventral blind sac (Table 2).

All measured data were normally distributed; however, there was no significant correlation between the histomorphometric and ultrasonographic data.

## Discussion

In this study, for the first time it was possible to correspond and match the layers of the rumen wall in ultrasonographic images with histological images. In ultrasonography, the mucosa and submucosal layers were appeared more hyperechoic than the muscular layer which was hypoechoic. In ultrasonographic images, distinguishing mucosal layer from submucosal layer was not possible. In this study, for the first time, thickness of the various layers has been reported in the histological and ultrasonographic images.

Statistical analysis of the data showed no significant correlation between the parameters of the rumen wall in ultrasonography and histological study. This could be due to changes in tissue parameters during preparation (dehydration, clearing and infiltration).

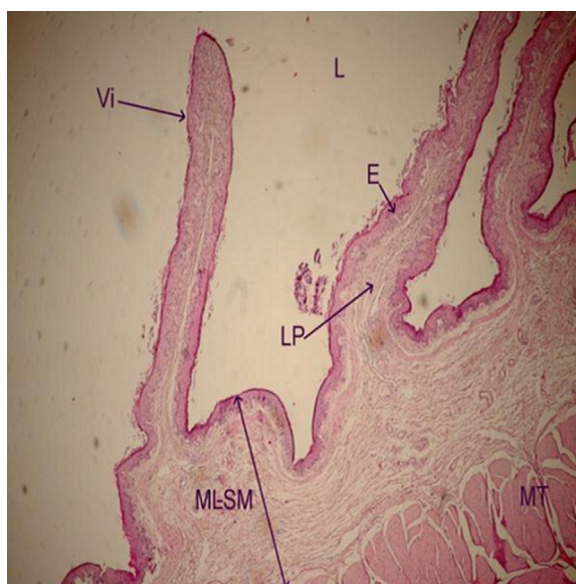
The average thickness of the rumen wall in histological images was higher in the ventral blind sac, dorsal blind sac and pillar. The average thickness

of these layers in ultrasonography was also high. The average thickness of mucosa and submucosal layers in histological images were higher in ventral blind sac, dorsal blind sac and pillar. Also, the average thickness of muscularis and serosal layers tissue in histological images were higher in pillar, dorsal blind sac and ventral blind sac.

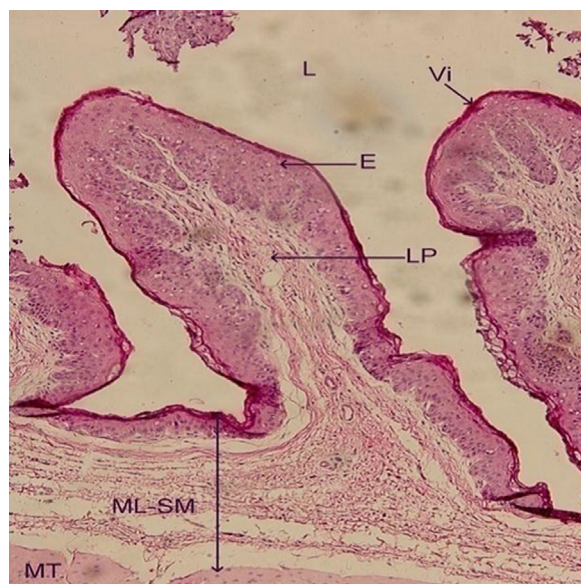
The most striking result of this study is the determination of all layers of rumen wall in sheep by histological and ultrasonography techniques. It is worth noting that this procedure has been performed for the first time and can be helpful as the first step for future studies and research.

## Materials and Methods

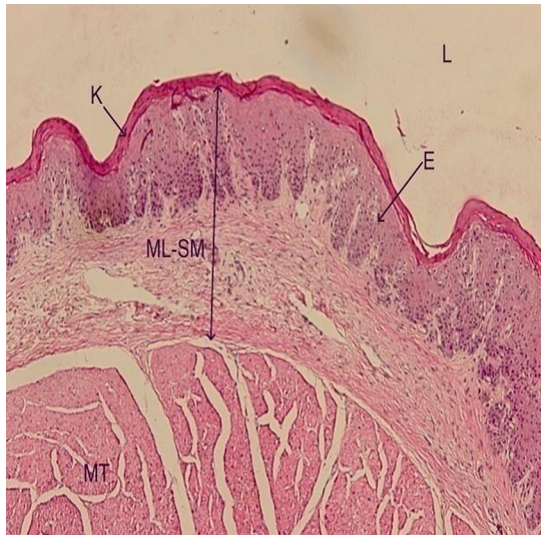
In this study, 10 rumen from healthy sheep rumen were obtained used for histomorphometric and ultrasonographic examination. For histomorphometric evaluation of the rumen, the samples were taken from the three areas of the rumen wall including the dorsal blind sac, ventral blind sac, and pillar (0.5 × 0.5 cm). They were flushed with normal saline, fixed in 10% buffer formalin, dehydrated, cleared with xylene and embedded in paraffin. All samples were blocked by paraffin. Then, sections were cut at 6 μm thickness by a rotary microtome (Leica®) and mounted on a glass slide and stained with Hematoxylin and Eosin (H&E). For ultrasonographic evaluation, samples were cut in 6 × 6 cm pieces and they immersed in normal saline. Then ultrasonography was performed using an 8 MHz probe. The external layer of rumen was near to foot print of probe and by moving the probe near and far to these segments, ultrasonography at the highest resolution possible in the focal zone was obtained. The procedure was recorded



**Figure 1**  
Histological structure of dorsal blind sac. Lumen (L), Epithelium (E), Villi (Vi), Lamina propria (LP), mucosal and submucosal layer (ML- SM), Muscular Tunica (MT), H&E, ×40.

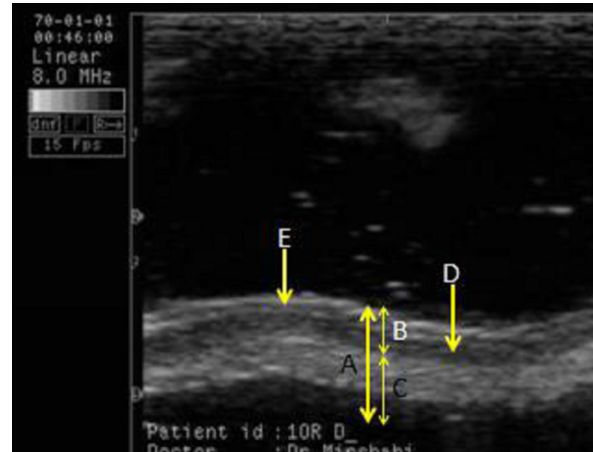


**Figure 2**  
Histological structure of ventral blind. Lumen (L), Epithelium (E), Villi (Vi), Lamina propria (LP), mucosal and submucosal layer (ML- SM), Muscular Tunica (MT), H&E, ×100.



**Figure 3**  
Histological structure of pillar. Lumen (L), Epithelium (E), Kerapreparationtine (K), mucosal and sub mucosal layers (ML- SM), Muscular Tunica (MT), H&E,  $\times 40$ .

through all of the stages, digitally. Then, evaluation and implementations of ultrasound and histological images of each specified area in rumen were confirmed. Mucosal and submucosal layers, and muscular and serosa layers were measured in all samples in 5 parts of each slide by using the software of Image-J 1.47. In ultrasonogram, mucosal, submucosal, muscular, and serosa layers were evaluated in three points. Average, standard deviation, minimum and maximum for each of the measured parameters were reported. The normality of data with the help of Kolmogorov- Smirnov, Shapiro-Wilk and QQ plat charts were reviewed and approved. Histomorphometric correlation and ultrasonographic data based on the Pearson correlation coefficient with a significant level of  $p < 0.05$  were evaluated.



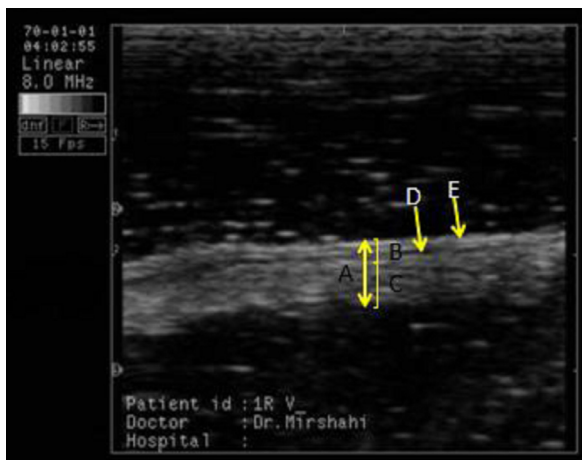**Figure 4**  
Ultrasonogram of dorsal blind sac. Wall thickness (A), thickness of muscularis and serosal layers (B), thickness of mucosal and submucosal layers (C), muscularis layer (D), serosal layer (E).

## Acknowledgements

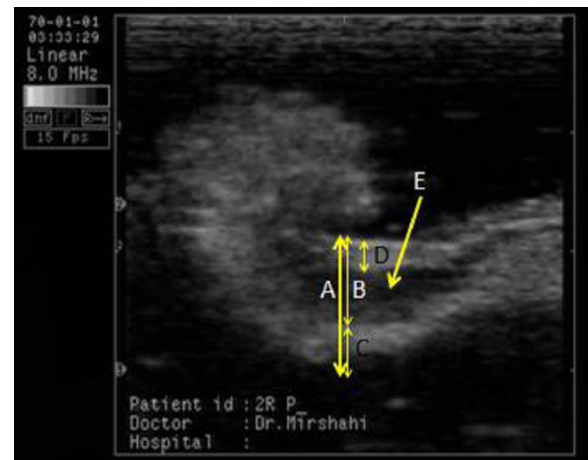
The authors would like to thank Ferdowsi University of Mashhad for financial support, and Mr. Pouradibi for his technical assistance.

## Author contributions

Conceived and designed the experiments: A. M. Performend the experiments: M.M. Contributed reagents/materials/analysis tools and wrote the



**Figure 5**  
Ultrasonogram of ventral blind sac. Wall thickness (A), thickness of muscularis and serosal layers (B), thickness of mucosal and submucosal layers (C), muscularis layer (D), serosal layer (E).



**Figure 6**  
Ultrasonogram of pillar. Wall thickness (A), thickness of muscularis and serosal layers (B), thickness of mucosal and sub mucosal layers (C), muscularis layer (E), serosal layer (D).

**Table 1**  
Histomorphometric measurements of rumen wall.

| Region            | Layer              | Mean (mm) | Minimum (mm) | Maximum (mm) | SD   |
|-------------------|--------------------|-----------|--------------|--------------|------|
| Dorsal blind sac  | Mucosal/submucosal | 1.32      | 0.61         | 3.01         | 0.5  |
|                   | Muscular/serosal   | 1.17      | 0.71         | 1.8          | 0.25 |
|                   | wall               | 2.49      | 1.74         | 3.77         | 0.46 |
| Ventral blind sac | Mucosal/submucosal | 1.71      | 0.49         | 3.23         | 0.58 |
|                   | Muscular/serosal   | 1         | 0.56         | 1.91         | 0.25 |
|                   | wall               | 2.71      | 1.2          | 4.46         | 1.67 |
| Pillar            | Mucosal/submucosal | 0.39      | 0.27         | 0.5          | 0.08 |
|                   | Muscular/serosal   | 5.52      | 4.68         | 6.23         | 0.68 |
|                   | wall               | 5.91      | 5.14         | 6.57         | 0.64 |

paper: A.R.R.

### Conflict of Interest

The authors declare that they have no competing interests.

### References

1. Jerbi H, Perez W. Gross Anatomy of the Stomach of the Cervus Elaphus barbarus. *Int. j. morphol.* 2013; 31(2):388-91
2. Braun U. Ultrasonography of the gastrointestinal tract in cattle. *Veterinary Clinics of North America: Food Animal Practice.* 2009 Nov 30; 25(3):567-90.
3. Franco A, Masot J, Redondo E. Ontogenesis of the rumen: a comparative analysis of the Merino sheep and Iberian red deer. *Animal science journal.* 2011 Feb 1; 82(1):107-16.
4. El-Gendy SA, Derbalah A. Macroscopic and microscopic anatomy of the Omasum of the Baladi goat. *Journal of Applied Biological Sciences.* 2010; 4(3):37-45.
5. García A, Masot J, Franco A, Gázquez A, Redondo E. Histomorphometric and immunohistochemical study of the goat rumen during prenatal development. *The Anatomical Record.* 2012 May 1; 295(5):776-85.
6. Dellmann HD. *Textbook of veterinary histology.* Lea &Febiger. Philadelphia.1993.
7. White IR, Russel AJ, Fowler DG. Real-time ultrasonic scanning in the diagnosis of pregnancy and the determination of fetal numbers in sheep. *The veterinary record.* 1984 Aug; 115(7):140-3.
8. Scoot PR, Gessen ME. Ultrasonography examination of the ovine thorax. *Veterinary Journal.* 1998; 155: 305-310.
9. Braun U, Steininger K, Tschuor A, Hassing M. Ultrasonography examination of the small intestine, large intestine and greater omentum in 30 Saanen goats.

**Table 2**  
Ultrasonographic measurements of rumen wall.

| Region            | Layer              | Mean(mm) | Minimum (mm) | Maximum (mm) | SD   |
|-------------------|--------------------|----------|--------------|--------------|------|
| Dorsal blind sac  | Mucosal/submucosal | 4.21     | 3.13         | 6.01         | 0.74 |
|                   | Muscular/serosal   | 2.34     | 1.01         | 4.25         | 0.71 |
|                   | wall               | 6.64     | 4.48         | 8.23         | 0.98 |
| Ventral blind sac | Mucosal/submucosal | 4.43     | 2.98         | 6.43         | 0.86 |
|                   | Muscular/serosal   | 1.80     | 1.08         | 3            | 0.45 |
|                   | wall               | 6.26     | 4.37         | 8.04         | 0.99 |
| Pillar            | Mucosal/submucosal | 2.60     | 1.46         | 4.06         | 0.69 |
|                   | Muscular/serosal   | 11.64    | 6.08         | 15.75        | 2.94 |
|                   | wall               | 14.33    | 9.94         | 17.84        | 2.55 |

- Veterinary Journal. 2011; 189: 330-335
10. Tschuor A, Clauss M. Investigations on the stratification of forestomach contents in ruminants: an ultrasonographic approach. *European Journal of Wildlife Research*. 2008 Oct 1; 54(4):627-33.
  11. Scott PR, Sargison ND, Macrae A, Rhind SR. An outbreak of subacute fasciolosis in Soay sheep: ultrasonographic biochemical and histological studies. *The Veterinary Journal*. 2005 Nov 30; 170(3):325-31.
  12. Scott PR. Ultrasonographic examination of the urinary tract of sheep. *Practice*. 2000; 22:329-34.
  13. Braun U, Götz M, Marmier O. Ultrasonographic findings in cows with traumatic reticuloperitonitis. *The Veterinary Record*. 1993 Oct; 133(17):416-22.
  14. Scott PR, Sargison ND. Ultrasonography as adjunct to clinical examination in sheep. *Small Ruminant Research*. 2010; 92: 108-119.
  15. Braun U, Pusterla N, Schönmann M. Ultrasonographic findings in cows with left displacement of the abomasum. *Veterinary record*. 1997 Sep 27; 141: 331-4.
  16. Miyazaki T, Miyazaki M, Yasuda J, Okada K. Real time evaluation of abomasal curd formation in preruminant calves by ultrasonography. *Japanese Journal of Large Animal Clinics*. 2010; 1(2):54-61.
  17. Braun U, Wild K, Guscetti F. Ultrasonographic examination of the abomasum of 50 cows. *The Veterinary Record*. 1997 Jan; 140(4):93-8.
  18. Tharwat M, Al-Sobayil F, Ali A, Buczinski S. Transabdominal ultrasonographic appearance of the gastrointestinal viscera of healthy camels (*Camelus dromedaries*). *Research in veterinary science*. 2012 Oct 31; 93(2):1015-20.