



## Rare case of hemangiopericytoma in a domestic short-haired cat

Farzad Hayati,<sup>a</sup> Ensiyeh Sajadian Jaghargh,<sup>a</sup> Mohsen Maleki,<sup>b</sup> Mahdi Hassankhani,<sup>c</sup>  
Hossein Khoribabalhakam,<sup>a</sup> Fatemeh Namazi<sup>d</sup>

<sup>a</sup> Department of Clinical Sciences, Faculty of Veterinary Medicine, Ferdowsi University of Mashhad, Mashhad, Iran.

<sup>b</sup> Department of Pathobiology, Faculty of Veterinary Medicine, Ferdowsi University of Mashhad, Mashhad, Iran.

<sup>c</sup> Department of Small Animal Clinical Sciences, Faculty of Veterinary Medicine, University of Tehran, Tehran, Iran.

<sup>d</sup> Department of Pathobiology, School of Veterinary Medicine, Shiraz University, Shiraz, Iran.

### ABSTRACT

A two-year-old queen was referred to the surgery section of veterinary hospital with lateral recumbency position and the primary diagnosis of dystocia. The queen was highly lethargic and dehydrated, with a pale mucous membrane, a rectal temperature of 37.3 °C, and no vaginal discharge during first inspection. The primary examination revealed a big mass in the abdominal cavity, which was followed by other diagnostic investigations. Due to a huge and encroaching tumor and the patient's owner's refusal to accept any further therapies, the queen was euthanized during an exploratory celiotomy. This report describes a large Hemangiopericytoma (HPCy) in a domestic short-haired queen diagnosed based on physical examination, radiography, ultrasonography, histomorphology, and immunohistochemical reactivity. The results of pathology revealed a whorls around blood vessels and the "fingerprint" pattern of tumor with negative S-100 immunohistochemistry staining. In dogs, HPCy is a common neoplasm, but it is a seldom finding in cats. There is no previous report of HPCy in the abdominal cavity as observed in the presented case to the authors' knowledge.

### Keywords

*hemangiopericytoma, cat, immunohistochemistry, abdominal cavity, histomorphology*

### Abbreviations

HPCy: Hemangiopericytoma  
DSH: Domestic short-haired  
CBC: Cell blood count

Number of Figures: 2  
Number of Tables: 2  
Number of References: 16  
Number of Pages: 6

## Introduction

**H**emangiopericytoma (HPCy) is a common Neoplasm in middle-aged or older dogs [1,2]. These tumors represent 7% of canine cutaneous tumors and are most often found in the lower extremities [3]. According to the literature, it is uncommon in cats [4]. It accounts for around 2.5 percent of all soft tissue sarcomas in humans and is classified as a malignant neoplasm [3]. HPCys [1,5] are a kind of soft tissue sarcoma that arises from vascular pericytes. HPCy is a locally infiltrative tumor that recurs following surgical excision on rare occasions, although it seldom metastasizes [4]. These tumors usually appear as solitary, well-circumscribed, lobulated, and pseudo-capsulated masses of gray-white to red-brown color, occasionally reaching considerable dimensions [3,4]. The hallmark of this tumor microscopically is whorls around blood vessels and the “fingerprint” pattern formed by the neoplastic cells [2,4,6]. It should be differentiated from endothelioma, angiosarcoma, fibrosarcomas, leiomyosarcomas, schwannoma, peripheral nerve sheath tumor, and seldom dermatofibrosarcoma (a variant of malignant fibrous histiocytoma) and, maybe, glomus tumor [5,6]. The definitive diagnosis of HPCy is immunohistochemical findings [4]. This study describes a case report of hemangiopericytoma in a domestic short-haired (DSH) cat referred to a veterinary clinic, Iran.

## Case Presentation

A two-year-old female DSH cat weighing 3.5 kg was presented to a veterinary hospital, Tehran, Iran, with clinical signs of lateral recumbency position, anorexia, and abdominal enlargement. The owner assumed she was pregnant because of her swollen abdomen. The queen was highly lethargic and dehydrated, with a pale mucous membrane, a rectal temperature of 37.3 °C, and no vaginal discharge during the first inspection. Cell blood counts (CBC) and biochemical profiles were determined using a blood sample (Table 1). An ultrasonographic examination showed a heterogeneous mass with a nearly distinct border. The mass was evaluated using Doppler, and power Doppler revealed significant vascularity in the mass (Figure 1). Medetomidine (0.02 mg/kg) was used to pre-anesthetize the patient. After injection of diazepam (0.2 mg/kg, IV) and ketamine hydrochloride (6 mg/kg, IV), the patient was intubated and positioned in a dorsal recumbency position. Anesthesia was maintained by isoflurane (1.5%) inhalation. After the aseptic preparation of the surgical region, the midline incised from the xiphoid to a midline point between the umbilicus and pubis. A large soft tissue mass was in the

abdominal cavity and around the lumbar vertebral column, and the uterus and other abdominal organs' appearance were grossly normal. Due to a huge and encroaching tumor and the patient's owner's refusal to accept any further therapies, the queen was euthanized during an exploratory celiotomy. The mass was removed and shown to be white, multilobulated, and enormous, weighing around 900 grams (Figure 2A, 2B). The specimens of mass were fixed in 10 percent formalin for histological analysis. The tissue specimens were placed in ethanol (70% for 24 h, 90% for 1 h, and 100% for 1 h) for graded dehydration, then cleaned in xylene and embedded in paraffin. Sections were made at 5 µm thickness, stained with hematoxylin and eosin for the histopathological evaluation. Immunohistochemical analysis was performed to differentiate the tumor from the peripheral nerve sheath tumor and confirm the histopathological diagnosis. On formalin-fixed, paraffin-embedded tissues, immunohistochemistry expression of S-100 protein was performed, and the sections were processed using the avidin-biotin-peroxidase complex method. Histopathologically, the tissue sections showed that the tumor contained multiple layers of spindle-shaped cells arranged around a central thin-wall vessel, a fingerprint pattern, with the collagenous stroma. The neoplastic cells had homogenous eosinophilic cytoplasm with prominent nuclei. The mitotic figures were rare (Figure 2C, 2D). By the immunohistochemical examination, the tumor cells stained negative for S-100 protein (Figure 2E). Based on histopathological and immunohistochemical findings, an HPCy was diagnosed.

## Results & Discussion

HPCy has been found in both dogs and men [5]. It is, however, infrequently documented in cats [3]. HPCy is most often observed in the legs and hindlimbs of both humans and dogs [6]. In cats, it is seen on the thoracic side and the left thigh, according to prior case reports [3,5]. In dogs, metastatic HPCy is unusual [6], with just 5 individuals having metastasized to the lungs, sublumbar lymph nodes, or chest [7-10], whereas in men, the metastatic rate ranges from 11.7 percent to 56.5 percent [6]. Dogs have a broad variety of recurrence rates (ranging from 26 to 60%) [6]. In a DSH cat, it was found in the belly cavity and surrounding the lumbar spinal column.

In our study, the preoperative findings were in terms of the physical examination, ultrasonography, CBC, and serum biochemical profile (Table 1). Mild normocytic normochromic- non-regenerative anemia (because of mild anemia: HCT 31, MCV normal, normochromic: MCHC normal) besides low serum iron

**Table 1.**  
Measurement of CBC and serum biochemicals in the patient.

Hematology	Value	Unit	Reference Range
HCT	31	%	37-55
Hb	102	g/l	120-180
RBC	4.77	$\times 10^{12}$ cell/l	5.5-8.5
MCV	65	fl	60-72
MCH	25	Pg	21-26
MCHC	330	g/l	310-360
NRBC	0	cell/100 wbc	0-1
RDW	13.8	%	10.6-14.3
			1: Non regenerative
			1-4: weak regenerative
			5-20: moderate regenerative
			21-50: strong regenerative
PLT	750	$\times 10^9$ cell/l	150-500
WBC	18.6	$\times 10^9$ cell/l	4.5-17
Neutrophil	12.7	$\times 10^9$ cell/l	3-11.5
Lymphocyte	3.35	$\times 10^9$ cell/l	1-4.8
Monocyte	1.8	$\times 10^9$ cell/l	0-1.3
Eosinophil	0.3	$\times 10^9$ cell/l	0.1-1.2
Basophil	0	$\times 10^9$ cell/l	0-0.1
Band Neutrophil	0.45	$\times 10^9$ cell/l	<0.3
Total Protein	94	g/l	54-74
Albumin	37	g/l	27-45
Globulin	57	g/l	19-37
BUN	310	mg/l	70-280
Creatinine	12	mg/l	3-13
ALP	267	IU/l	10-140
ALT	55	IU/l	17-95
AST	39	IU/l	5-65
GGT	2	IU/l	0-8
Total Bilirubin	1	mg/l	0-4
Glucose	1410	mg/l	750-1300
Triglyceride	830	mg/l	290-1200
Cholesterol	1970	mg/l	1300-3700
Na	151	mEq/l	145-150
K	4.1	mEq/l	3.9-5.5
Cl	109	mEq/l	106-127
Corrected Chloride	112	mEq/l	107-113
Total Ca	119	mg/l	90-115
Ionized Ca	62	mg/l	50-58
P	37	mg/l	28-61
Serum Iron	690	$\mu$ g/l	970-2630
TIBC	2970	$\mu$ g/l	2800-4890
Transferrin Saturation	23.23	%	27-66
ACTH Stimulation Test			
Basal cortisol	50	$\mu$ g/l	20-60
1 Hour after Injection	170	$\mu$ g/l	60-180

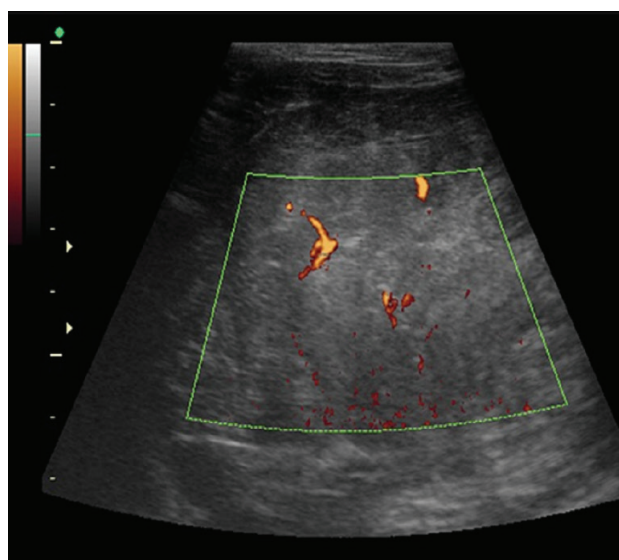
concentration and low TIBC indicates anemia due to chronic disease or acute inflammation. Neutrophilic leukocytosis with monocytosis and left shift indicates chronic active inflammatory response which is anticipated from the case presentation with inflammatory/neoplastic reaction. Hyperproteinemia regarding the hyperglobulinemia and normal serum albumin concentration is compatible with active antigenic stimulation by neoplastic tissue. Differential diagnoses of hypercalcemia and normophosphatemia (increased total and ionized serum Ca<sup>2+</sup> concentration alongside normal serum phosphorus concentration), regarding the case history, were hypoadrenocorticism and focal osteolytic lesions [11]. Hypoadrenocorticism was ruled out by an ACTH stimulation test and a normal Na/K concentration. As a result, hypercalcemia and normophosphatemia are thought to be associated with localized spinal bone osteolysis caused by tumor invasion. The liver and renal functions were found to be normal. The tumor's intra-abdominal or bone metastatic pathology may cause a moderate (less than 3 times) rise in serum ALP activity. Thrombocytosis may occur because of inflammation.

Based on these findings, the abdominal tumor's presumptive diagnosis was made, but we performed the histopathological and immunohistochemical studies for the definitive diagnosis. Microscopically, whorls around blood vessels and the "fingerprint" pattern have been identified as a feature of this tumor [2, 4, 6]. The tissue slices in this research had a hypercellular pattern that looked like a fingerprint, which is a common occurrence. In canines and men, HPCy histopathological categorization is a valuable diagnostic technique for predicting prognosis, recurrence, and metastatic rates. Based on tissue differentiation, mitotic count, and necrosis quantification, this categorization might range from grade I to III (poor diag-

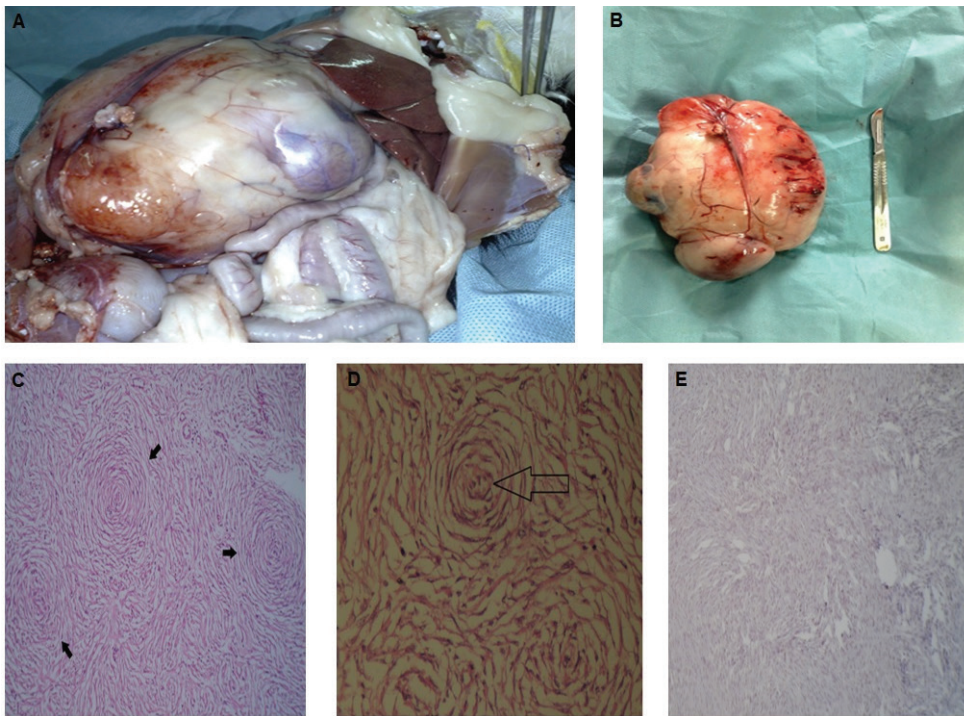
nostic) [1, 12]. The tumor showed features consistent with grade II in this case. As it is mentioned previously, immunohistochemistry is useful in ruling out other spindle cell tumors, which present the same whorl pattern [4, 6]. The neoplastic cells stained positively for vimentin, anti-muscle actin, and laminin and negative for S-100 protein, factor VIII-related antigen, lysozyme, and UEA I lectin [2, 4, 5, 6, 13]. S-100 is detected in 100% of schwannomas, 100% of neurofibromas (weaker than schwannomas), 50% of malignant peripheral nerve sheath tumors (may be weak and/or localized), paraganglioma stromal cells, histiocytoma, and clear-cell sarcomas [14]. The absence of immunoreactivity against S-100 helped rule out a diagnosis of other soft tissue sarcomas.

Treatment options for HPCy include surgery and radiation. Chemotherapy and other systemic therapies have had mixed results [15]. Without radiation, the canine HPCy recurrence rate was found to be 26 percent [9] and 38 percent [16]. Meantime to recurrence with or without radiotherapy after surgery 27 and 16 months, respectively. Maruo et al. suggested that conservative resection and intraoperative radiotherapy may control local tumors (e.g HPCy) without an adequate margin [1]. Baldi et al. used electrochemotherapy for the treatment of thoracic HPCy in a cat. Electrochemotherapy is a new treatment for tumors [5].

In conclusion, a hemangiopericytoma was diagnosed based on the physical examination, radiography, ultrasonography, histomorphology, and immunohistochemical reactivity in the cat. To the authors' knowledge, this is the third reported hemangiopericytoma and the largest among them in cats. This tumor is rare in cats; therefore, the diagnosis of HPCy in cats needs more information.



**Figure 1.**  
Ultrasonography of the mass.



**Figure 2.**

A) The large mass in the abdominal cavity close to kidney. B) The excised mass. C&D) Spindle shaped cells are arranged around a central capillary, "fingerprint pattern", in the collagenous stroma, H&E staining. E) Negative immunolabelling with S-100.

### Authors' Contributions

ESJ and HK performed review literature and manuscript writing. MM and FN performed the pathological analysis. MH examined the animal and performed review literature. FH performed surgery, review literature, and manuscript writing.

### Acknowledgements

We thank Dr. Saeed Ahrari for his diagnostic comments.

### Conflict of interest

The authors declare that there is no conflict of interest.

### References

1. Takuya M, Shida T, Fukuyama Y, Hino Y, Yamada T, Madarame H. Evaluation of intraoperative radiation therapy for incompletely resected or recurrent canine hemangiopericytoma: seventeen cases. *Int J Appl Res Vet M* 10. 2012; 132-136.
2. Handharyani E, Ochiai K, Kadosawa T, Kimura T, Umemura T. Canine hemangiopericytoma: an evaluation of metastatic potential. *J Vet Diagn Invest*. 1999;11(5):474-8.
3. Blutke A, Knebel J, Brühshwein A, Breuer W, Hermanns W. Hemangiopericytoma in a cat: a case report. *Vet Med-Czech*. 2012;57(5).
4. Silva EOD, Romero F, Green KT, Martins MIM, Bracarense APFRL. Hemangiopericytoma in a female dog with direct invasion of abdominal cavity and pulmonary metastasis. *Cienc Rural*. 2014;44(2):358-61.
5. Baldi A, Spugnini EP. Thoracic haemangiopericytoma in a cat. *Vet Rec*. 2006;159(18):598-600.
6. Perez J, Bautista MJ, Rollon E, Lara FCn-Md, Carrasco L, Mulas JMndI. Immunohistochemical characterization of hemangiopericytomas and other spindle cell tumors in the dog. *Vet Pathol*. 1996;33(4):391-7.
7. Richardson RC, Render JA, Rudd RG, Shupe RE, Carlton WW. Metastatic canine hemangiopericytoma. *Javma-J Am Vet Med A*. 1983;182(7):705-6.
8. Pantekoek J, Schiefer B. Metastasising canine fibrosarcoma originally diagnosed as haemangiopericytoma. *J Small Anim Pract*. 1975;16(12):259-65.
9. Postorino NC. Prognostic variables for canine hemangiopericytoma: 50 cases (1974-1984). *J Am Anim Hosp Assoc*. 1988;24:501-9.
10. Bostock DE, Dye MT. Prognosis after surgical excision of canine fibrous connective tissue sarcomas. *Vet Pathol*. 1980;17(5):581-8.
11. Schenck PA, Chew DJ, Nagode LA, Rosol TJ. Disorders of calcium: hypercalcemia and hypocalcemia. Fluid, electrolyte, and acid-base disorders in small animal practice. 2006;4:120-94.

12. Trojani M, Contesso G, Coindre JM, Rouesse J, Bui NB, De Mascarel A, et al. Soft tissue sarcomas of adults; study of pathological prognostic variables and definition of a histopathological grading system. *Int J Cancer*. 1984;33(1):37-42.
13. Gross TL, Ihrke PJ, Walder EJ, Affolter VK. Mesenchymal neoplasms and other tumors. *Skin diseases of the dog and cat Clinical and Histopathologic Diagnosis* 2nd ed, Blackwell Science, Oxford. 2005:722-7.
14. Nonaka D, Chiriboga L, Rubin BP. Differential expression of S100 protein subtypes in malignant melanoma, and benign and malignant peripheral nerve sheath tumors. *J Cutan Pathol*. 2008 Nov;35(11):1014-9.
15. Allen H. Hemangiopericytoma in the dog. 2003.
16. Graves GM, Bjorling DE, Mahaffey E. Canine hemangiopericytoma: 23 cases (1967-1984). *Javma-J Am Vet Med A*. 1988;192(1):99-102.

**COPYRIGHTS**

©2021 The author(s). This is an open access article distributed under the terms of the Creative Commons Attribution (CC BY 4.0), which permits unrestricted use, distribution, and reproduction in any medium, as long as the original authors and source are cited. No permission is required from the authors or the publishers.

**How to cite this article**

Hayati F, Sajadian Jaghargh E, Maleki M, Hassankhani M, Khoribabalhakam H, Namazi F. Rare case of hemangiopericytoma in a domestic short-haired cat. *Iran J Vet Sci Technol*. 2021;13(2):106- 111.  
URL: [https://ijvst.um.ac.ir/article\\_41469.html](https://ijvst.um.ac.ir/article_41469.html)