

## Evaluation of histopathological features of *Argas reflexus* bite in pigeon

Maryam Gholizadeh<sup>1</sup>, Mousa Tavassoli<sup>1\*</sup>, Farid Rezaei<sup>2</sup>, Zahra Nikousefat<sup>3</sup>

<sup>1</sup>Department of Patobiology, Faculty of Veterinary Medicine, Urmia University, Urmia, Iran

<sup>2</sup>Department of Patobiology, Faculty of Veterinary Medicine, Razi University, Kermanshah, Iran

<sup>3</sup>Department of Clinical Sciences, Faculty of Veterinary Medicine, Razi University, Kermanshah, Iran

Received: June 16, 2014      Accepted: March 03, 2015

### Abstract

*Argas reflexus* is considered obligate blood feeder that may cause skin redness and local swelling. For histopathological evaluation of biting site, pigeons were used as natural host species in this study. Adult ticks were collected from Urmia, North-west of Iran and kept in a desiccator before their use in the experiment. Sixteen Pigeons were infested experimentally and were divided into 4 groups, euthanized after 30 min, 4, 24 and 48h for evaluation of histopathological changes in biting sites. Early histopathologic lesions due to time of infestation included edema, hemorrhagic foci, vascular congestion, necrosis and mild to severe inflammatory reaction in dermis. In late lesions, presence of micro abscess foci in dermis was prominent. This study well documented the different pathological changes of skin of pigeons with *Argas reflexus*. However, further study should be performed to evaluate allergic immune responses and pathological changes in other animal species including human.

**Keywords:** *Argas reflexus*, tick, pigeon, histopathology

---

\*Corresponding author: Mousa Tavassoli  
Email: mtavassoli2000@yahoo.com  
Tel: +98 44 32770508  
Fax: +98 44 32771926

## Introduction

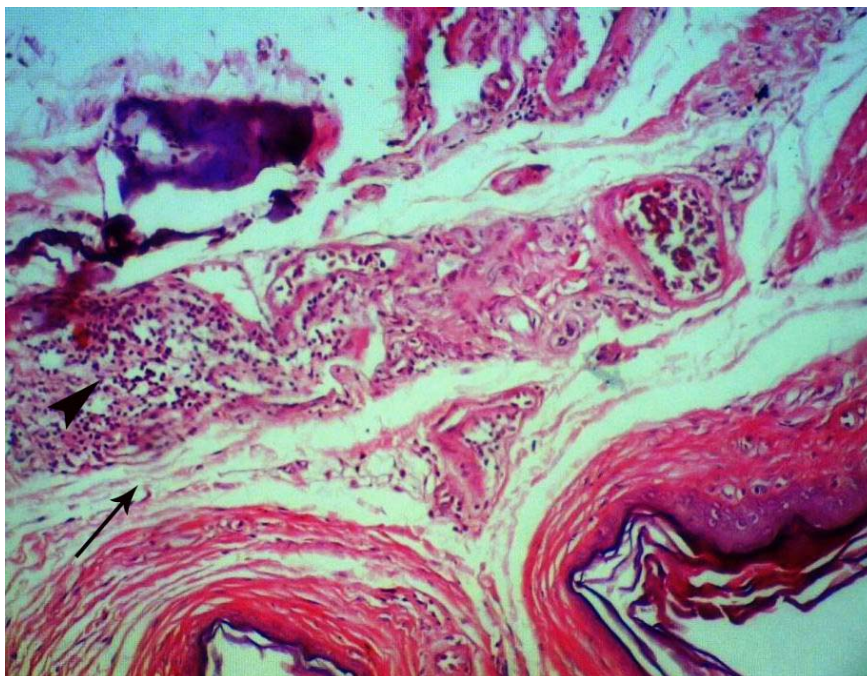
Ticks are obligate blood feeders that infest mammals, birds and reptiles (Balashov and Grigoreva, 2002; Tavassoli *et al.*, 2007). Several species of ticks are important in medical and veterinary science which are divided into two families: Argasidae (soft ticks) and Ixodidae (hard ticks) (Sonenshine, 1991, Uspensky, 2008). However, the infectious agents transfer to human and animals is the most important feature of tick infestation, but anemia and some histopathological disorders are usual in their hosts as well (Gonzalez-Acaa and Gugliemone, 2005). In addition, some species can inoculate toxins to their hosts (Uspensky, 2008).

European pigeon tick or *Argas reflexus* (the soft tick) is a temporary parasite of pigeons, in different parts of the world (Dautel and Nile, 1997). This parasite has an exceptional life expectancy of about 7-11 years and a variable generation time of 3-11

years that depend on the individual course of the adult tick (Dautel and Knulle, 1997).

It is a specific bloodsucking parasite of pigeon in various parts of Europe and the Middle East which under certain circumstances invades human habitations (Dautel *et al.*, 1994; Haag-Wackemagel and Bricher, 2010) and bites people as a substitute host when pigeons are not available (Hilger *et al.*, 2005) causing not only skin irritations and pathogen transmission (Haag-Wackemagel and Moch, 2004), but also a variety of symptoms corresponding to an IgE-mediated allergy with increasing severity resulting in death (Trautmann, *et al.*, 1995; Spiewak *et al.*, 2006; Weckesser *et al.*, 2010).

To our knowledge, there is no document describing the histopathological changes of skin in feeding places of *Argas reflexus*. The present experiment was therefore designed to study the histopathologic features of biting sites in pigeons experimentally infected by adult *Argas reflexus* bite.



**Figure 1.** Edema (arrow) and foci of inflammatory cells infiltration (arrow head) in the skin of pigeon in group 1(H&E staining, 100X).

## Materials and methods

The *Argas reflexus* ticks are active during the night and spend the daytime hidden in cracks and crevices of pigeon nests. Therefore, nestlings, adult pigeons and crevices of the walls of buildings with the gable roof where pigeons were living in the near vicinity of human beings in Urmia City, West Azarbaijan of Iran were examined for the presence of ticks. Different developmental stages of *Argas reflexus* were collected from each naturally infested site and sent to the parasitology laboratory of the Faculty of Veterinary Medicine in the Urmia University for identification of morphological characteristics (Wall and Shearer, 1997).

Some adult ticks were maintained in cotton-capped glass tubes containing filter paper moistened with sterile distilled water. The tubes were then placed in a desiccator at room temperature (22–25 °C) with 80% relative

humidity (RH). (Tavassoli *et al.*, 2011).

To induce infection, 16 male healthy pigeons were prepared and for each, 10 unfed adult ticks were placed on top of their legs to feed for 1-2 h.

Infested pigeons were divided into 4 equal groups (4 animals in each group). Four male pigeons in control group were not infested with tick and their skins prepared for histological study. All birds in group 1, 2, 3 and 4 were euthanized by Xylazin (5 mg/Kg) and Ketamin-HCl (40 mg/Kg) after 30 minutes, 4, 24 and 48 hours post infestation, respectively and Skin samples from both the biting sites and comparable adjoining normal skin were fixed in 10% neutral-buffered formalin. After fixation, the tissues were embedded in paraffin, and sections of 5 µm in thickness were stained using Hematoxylin and Eosin (H&E) and studied by a routine light microscope.

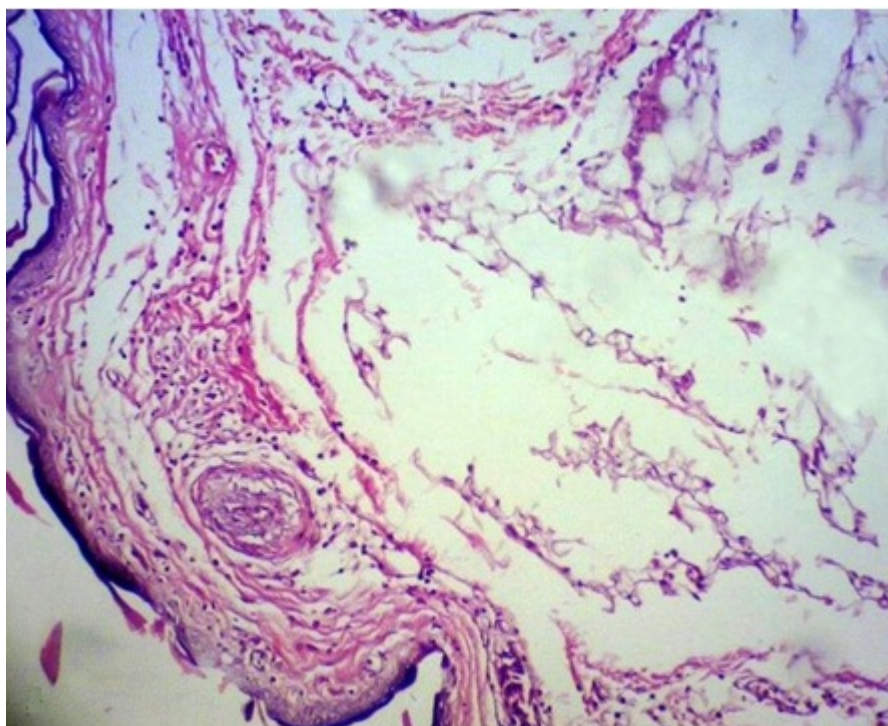
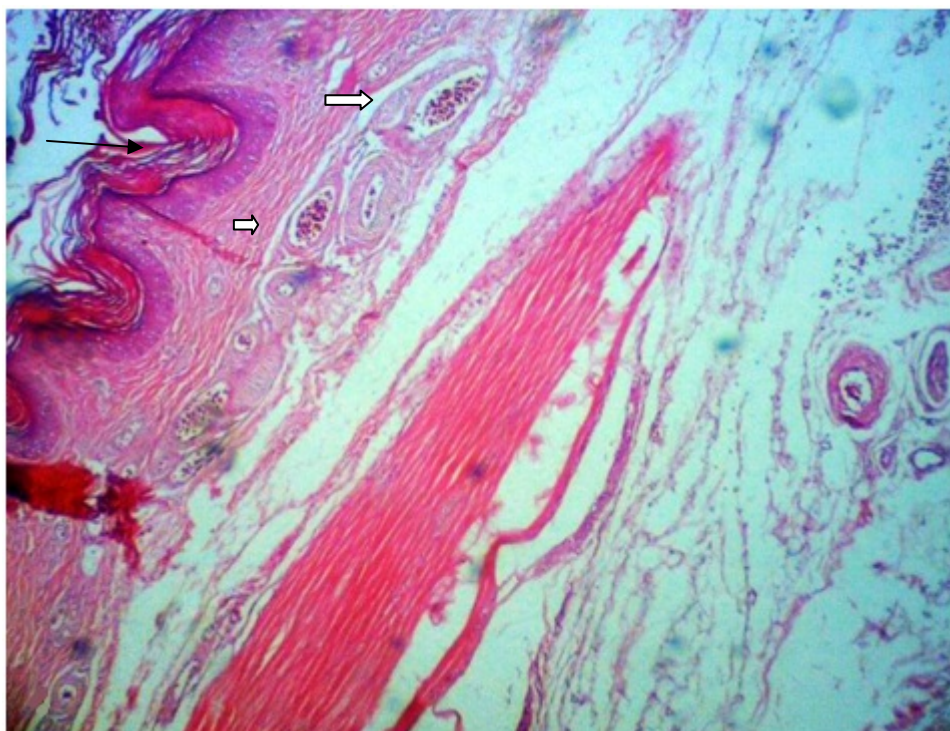


Figure 2. Edema in group 2 of pigeons is more prominent compare to group 1 (H&E staining, 100X).





**Figure 3.** Hyperkeratosis(arrow) and congestion of vessels(white arrows) in the skin of pigeon in group 3(H&E staining, 40X).

## Results

Adult ticks used for pigeon infestation were attached to natural host's skin for at least 1-2 hours. Host tissue reaction to salivary component following parasite feeding on pigeon skin varied in different groups of birds. In group 1 (30 minutes post infestation) site of tick bite was characterized by a mild congestion and small red points. Skin gross lesions in group 2 (4 h post infestation) were relative swelling and erythematous (hyperemia) which appeared as mild papula in biting location. In 24 h after removing adult ticks (group 3), congestion and swelling was not clearly seen and only characterized by demonstration of biting foci. In group 4 (48 h post infestation) relative healing reaction in biting sites appeared whereas skin biting sites were difficultly seen.

At 30 minutes post infestation, the main histopathologic findings in group 1 were edema, vascular congestion, multiple foci of hemorrhage and infiltration and aggregation of PMNs, Eosinophils and less numbers of

lymphocytes and plasma cells in the dermis (Fig. 1). At 4 h post infestation, the lesions in the pigeons of group 2 were more severe than group 1 with some differences. Edema and vascular congestion were prominent and multiple foci of perivascular infiltrates including PMNs, eosinophils and less lymphocyte were seen (Fig. 2).

At 24 h post infestation, acanthosis and hyperkeratosis were the main histopathologic findings in the epidermis. Most of the lesions were observed in the dermis. Congestion of vessels and multiple foci of extravascular (interstitial) microabscess including mostly PMNs were observed in addition to prevascular aggregation of inflammatory cells (Figs 3 and 4).

At 48 h post infestation, in comparison to group 3, acanthosis and hyperkeratosis were more prominent. In dermis, microscopic lesions were similar to group 3 but foci of micro abscess extended further in dermis diffusely including Neutrophils and less Eosinophils (Fig. 5).

## Discussion

The bite of soft ticks, notably *Argas* species, usually inhabitants of nests and burrows of birds and rodent and human dwelling in rural areas, cause irritation, blisters, bruising and a more or less severe pruritus (Estrada-Pena and Jongejan, 1999).

In some studies, the pathological features of hard tick bites such as *Rhipicephalus sanguineus* in resistant hosts (Veronez *et al.*, 2010), *Rhipicephalus sanguineus* in dogs and guinea pigs (Szabo and Bechare, 1999), *Amblyomma americanum* in the human (Fisher *et al.*, 2006), *Ixodes* species in passeriformes birds (Grigoreva, 2001), *Hyalomma anatolicum anatolicum* in rabbits (Gill and Walker, 1985) and *Ixodes* species in small mammals (Balashov and Grigoreva, 2002) were indicated. In comparison to hard tick, there are not valuable information about histopathological features of soft tick bites in human and animals and our knowledge is limited to a few reports such as *Ornithodoros lahorensis* in rat (Tavassoli *et al.*, 2007), *Ornithodoros tartakouskyi* in guinea pigs

(Mclaren *et al.*, 1983) and larvae of *Ornithodoros aff. puertoricensis* in laboratory mice (Venzal *et al.*, 2007)

For *Argas reflexus*, only some case reports of human victims with different allergic reactions of tick biting are available (Hilger *et al.*, 2005) and no experimental or natural data of pathological feature of both adult and larvae of this soft tick have yet been released. Thus this study aimed to determine the histopathological changes of pigeon skin in feeding places of soft tick *Argas reflexus*.

The type and severity of bite reactions vary based on tick species, feeding duration, mouthpart size, secretions, previous exposures and individual sensitivity (McGinely-Smith and Tsao, 2003, Krinsky, 1983; Yesudian and Thambiah, 1973; Riek and Lavoipierre, 1954).

In our study, some changes such as edema, hemorrhagic foci, vascular congestion, necrosis and inflammatory reaction mainly eosinophilic and lymphocytic proliferation were seen in various degrees based on time of infestation.

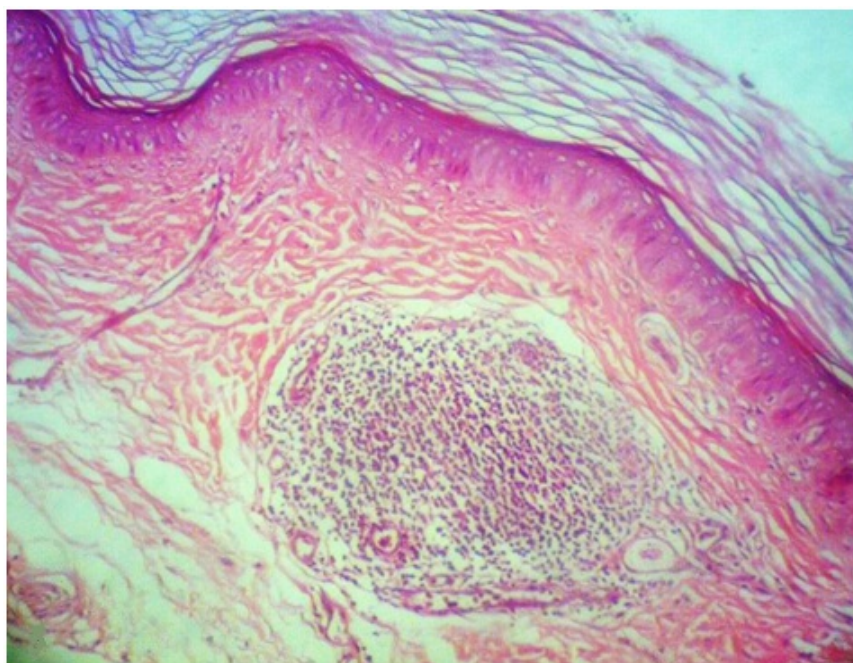
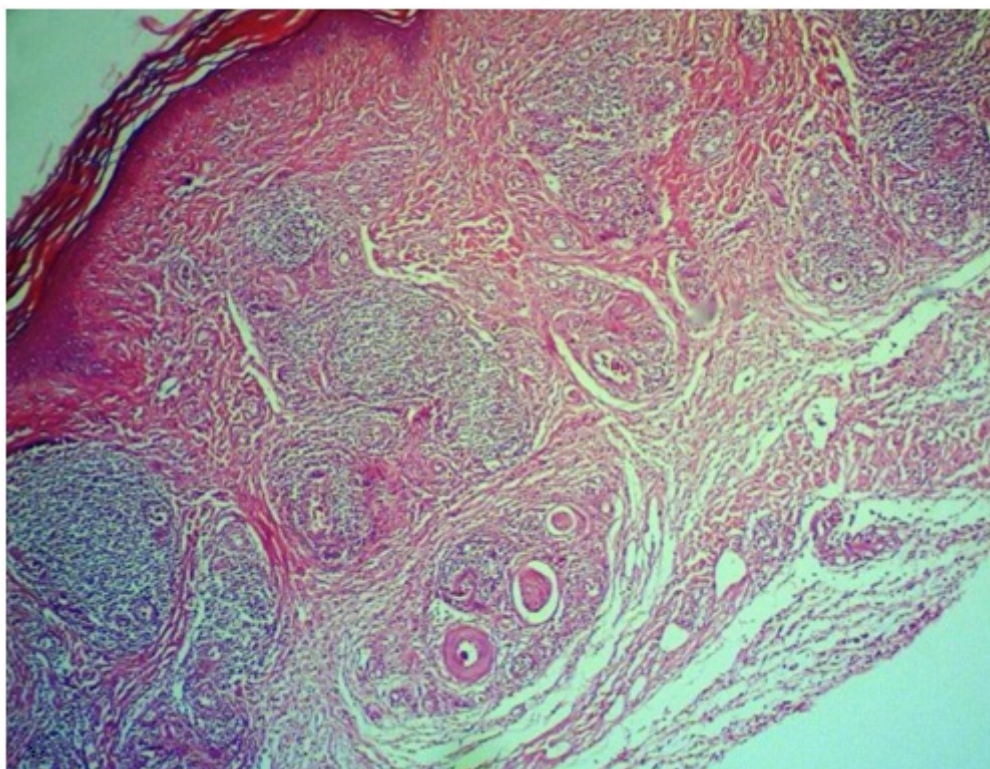


Figure 4. Extravascular (interstitial) microabscess including mostly PMNs in the skin of pigeon in group 3 (H&E staining, 100X).





**Figure 5.** Foci of microabscesses extended in dermis diffusely including heterophils and less eosinophils and the fibrotic tissue in the skin of pigeon in group 4 (H&E staining, 40X).

Micro abscess have been observed in infested pigeons and exclusively for cases that the time of post infestation was longer. Edema is one of the characteristics of inflamed tissue and is caused by an increase in vascular permeability that leads to accumulation of fluids, swelling and infiltration of leukocytes in the extra-vascular bed (Mans and Riberio, 2008, Riberio, 1989). When tick feeds on native host, the cellular infiltrate is first dominated by neutrophils followed by mononuclear cells; later a small amount of basophils and eosinophils can be observed (Kovar, 2004, Gill, 1986). When infestation is repeated, basophils and eosinophils dominate in the dermal infiltrate, and degranulation of basophils and mast cells can be observed (Kovar, 2004; DenHollander and Allen, 1985; Gill, 1986). Most cells that infiltrate in the attachment site are inhibited by tick saliva. NK cells (Kubes *et al.*, 1994, 2002; Kopecky and Kuthejlove, 1998; Kovar, 2004), neutrophils (Riberio *et al.*, 1990), macrophages (Urioste et

al., 1994, Kopecky and Kuthejlove, 1999) and mostly T cells (Ramachandra and Wilked, 1992; Bergman *et al.*, 2000; Kovar *et al.*, 2002) reduce many of their activities when they come in contact with tick saliva.

Guinea pigs that were exposed to *Rhipicephalus sanguineus* displayed a strong local reaction to ticks, mainly during tertiary infestations. Intense hyperemia, swelling, fluid exudation and even necrosis could be observed. Main dermal changes included a varying degree of cellular infiltration, edema, micro-abscesses and occasionally, hemorrhage and necrosis. Guinea pigs reacted to *Rhipicephalus sanguineus* mainly with mononuclear cells, eosinophils and basophils (Szabo and Bechara, 1999).

Balasov and Grigoreva, 2002 found that similar histopathological changes occur at the sites of anchoring and feeding of Ixodid ticks on mammals, birds and reptiles (Balashov and Grigoreva, 2002). Histopathological study of tick bite lesions in naturally infested capybaras

showed that necrosis was a common feature deep in the dermis particularly at the far end of the eosinophilic tube. Hyperplasia, cellular edema and occasionally necrosis of keratinocytes could be seen at both sides of the ruptured epidermis in these infested animals (Heijden *et al.*, 2005).

Tissue infiltration with a varying number of inflammatory cells, edema, hemorrhage and vascular dilation were the main dermal changes in anteaters and armadillos infested with ticks (Lima *et al.*, 2004).

Latif *et al.* (1990, 1991) showed that the predominant cell infiltrates in attachment site of high resistance cattle were Eosinophils with *Amblyomma variegatum* and Neutrophils with *Rhipicephalus appendiculatus*. Coetaneous lesions elicited in guinea pigs by primary and secondary feeding populations of the Argasid tick, *Ornithodoros tartakowskyi*, were analyzed by light and electron microscope. Small clusters of basophils appeared at primary bite sites within 24 h of tick attachment, and by 72 h constituted approximately 11% of the total leukocytes. Secondary feeding site exhibited basophils at all times. Eosinophil proliferation was minimal, however, and the remaining cells were of the mononuclear type (McLaren *et al.*, 1983).

Histopathological studies of *Ornithodoros lahorensis* bite on rat demonstrated foci of necrosis in the epithelium with remnant of polymorphonuclear cells infiltration and severe hemorrhages. In this survey the predominant inflammatory cells were lymphocytes and macrophages (Tavassoli *et al.*, 2007).

In our study some tissue reaction with adult of *Argas reflexus* was similar to previous studies in which PMNs were predominant with infiltrated cells.

Vascular eosinophilic hyaline thrombi were found to be a frequent histologic manifestation of a tick bite. This finding may be related to the secretory products of the tick's saliva during inoculation (Stafanato *et al.*, 2002).

Salivary glands structure and composition of Ixodid ticks are more complex than those Argasid ticks (Oleaga *et al.*, 2007; Bowman and Saver, 2004). Soft ticks often implicate in serious reactions comparing to hard ticks. Focal necrosis at the site of a tick bite can create necrotic ulcers up to several centimeters in size (McGinely-Smith and Tsao, 2003; Marshall, 1967; Kain, 1999; Cho *et al.*, 1994).

Tick bites can become secondarily infected (McGinely-Smith and Tsao, 2003; Pearce and Grove, 1987; Russell, 1974), by organisms such as *Staphylococcus aureus* and group A *Streptococcus* (Hoogstraal, 1985; Kain, 1999). Infection may manifest as impetigo, ecthyma, cellulitis or shallow painful purulent ulcers (Kain, 1999). Host scratching may also lead to increased tissue damage (Berenberug *et al.*, 1972; Goldman *et al.*, 1952) with subsequent infection (Marshall, 1967; McGinely-Smith and Tsao, 2003). In addition to transmission of infectious microbes, ticks may cause paralysis, allergies and severe toxic reactions in their hosts (Sonenshine, 1991). Anaphylactic reactions to bite of the pigeon tick, *Argas reflexus*, mediated by IgE specific for tick allergens have been observed (Klotz *et al.*, 2009, Estrada-Pena and Jongejan, 1998, Klein-Tabbe *et al.*, 2006, Hilger *et al.*, 2005).

This study well documented the different pathological changes of skin of pigeons with *Argas reflexus*. However, further study should be performed to evaluate allergic immune responses and pathological changes in other animal species including human.

### Acknowledgments

This project was funded by the Urmia University. We also thank Dr. Mohammad Hashem Nia and Dr. Haratian for their technical support.

### References

- Amosova, LI (1994). The ultrastructural characteristics of the histopathological changes at the site of attachment to the

- host body of larvae of the Ixodid tick *Ixodes ricinus*. *Parasitology* **28**, 356-363.
- Balashov, YUS and Grrigor'eva, LA (2002). Local histopathological changes of amniote skin by a feeding caused by a feeding tick (Acari: Ixodinae). *Doklady biological sciences* **385**, 349-351.
- Berenberug, JL; Ward, PA and Sonenshine, DE (1972). Tick-bite injury: Mediation by a complement-derived chemotictic chemotactic factor. *Journal of Immunology* **109**, 451-456.
- Bergman, DK; Palmer, MJ; Caimano, MJ; Radolf, JD and Wikel, SK (2000). Isolation and molecular cloning of a secreted immunosuppressant protein from *Dermacentor andersoni* salivary gland. *Journal of Parasitology* **86**, 516-525.
- Bessot, JC; Kopferschmitt, MC; deBlay, F; Dietemann, A; Nirrengarten, A and Hutt, N (1997). Chocs anaphylactiques apre`s morsure de tiques de pigeon (*Argas reflexus*): a propos de 12 cas. *Revue Francxaise de Allergologie etd Immunologie Clinique* **37**, 431-437.
- Bowman, AS and Sauer, JR (2004). Tick salivary glands: function, physiology and future. *Parasitology* **129**, S67-S81.
- Chastel, C; Bach-Hamba, D; Karabatsos, N; Bouattour, A; LeLay, G and LeGoff, F (1994). Tunis virus: a new Phlebovirus from *Argas reflexus hermanni* ticks in Tunes. *Acta Virology* **38**, 285-289.
- Cho, BK; Kang, H; Bang, D; Kim, SN; Hwang, S and Song, ES (1994). Tick bites in Korea. *International Journal of Dermatology* **33**, 552-555.
- Dautel, H; Kahl, O and Knulle, W (1991). The soft tick *Argas reflexus* (Acari: Argasidae) in urban environments and its medical significance in Berlin (West). *Journal of Applied Entomology* **11**, 380-390.
- Dautel, H and Knulle, W (1997). Life cycle and seasonal development of post-embryonic *Argas reflexus* (Acari: Argasidae) at two thermally different location in central Europe. *Experimental and Applied Acarology* **121**, 697-712.
- Dautel, H and Knulle, W (1998): The influence of physiological age of *Argas reflexus* larvae (Acari: Argasidae) and of temperature and photoperiod on induction and duration of diapause. *Oecologia* **113**, 46-52.
- Dautel, H; Scheurer, S and Kahl, O (1999). The pigeon tick (*Argas reflexus*): its biology, ecology, and epidemiological aspects. *Zentbl Bakteriologie* **289**, 745-753.
- Dautel, H; Kahl, O; Scheurer, S and Knulle, W (1994). Seasonal activities of the pigeon tick *Argas reflexus* (Acari: Argasidae) in Berlin, Germany. *Folia Parasitology* **41**, 155-160.
- Demain, JG (2003). Papulary urticaria and things that Bite in the night. *Current Allergy and Asthma Reports* **3**, 291-293.
- DenHollander, N and Allen, JR (1985). *Dermacentor variabilis*: acquired resistance to ticks in BALB/c mice. *Experimental Parasitology* **59**, 118-129.
- Estrada-Pena, A and Jongejon, F (1999). Ticks feeding on humans: a review of records on human-biting Ixodidea with special reference to pathogen transmission. *Experimental and Applied Acarology* **23**, 675-715.
- Fisher, EJ; Jun-Mo, MD; Anne, MD and Lucky, W (2006). Multiple pruritic papula from Lone Star tick larvae bites. *Archive of Dermatology* **142**, 491-494.
- Gill, HS (1986). Kinetics of mast cell, basophil and eosinophil populations at *Hyalomma anatolicum anatolicum* feeding sites on cattle and the acquisition of resistance. *Parasitology* **93**, 305-315.



- Gill, HS and Walker, AR (1985). Differential cellular responses at *Hyalomma anatolicum anatolicum* feeding sites on susceptible and tick-resistant rabbits. *Parasitology* **91**, 591-607.
- Goldman, L; Johnson, P and Ramsay, J (1952). The insect bite reaction: I. The mechanism. *Journal of Investigative Dermatology* **18**, 403-417.
- González-Acuña, DA and Guglielmone, AA (2005). Ticks (Acari: Ixodidae: Argasidae, Ixodidae) of Chile. *Experimental and Applied Acarology* **35**, 147-163
- Grigoreva, LA (2001). Histologic changes of bird skin in feeding places of ticks of the genus *Ixodes* (Acari: Ixodidae). *Parazitologia* **35**, 490-495.
- Haag-Wackernagel, D and Bircher, AJ (2010). Ectoparasites from feral pigeons affecting humans. *Dermatology* **220**, 82-92.
- Haag-Wackernagel, D and Moch, H (2004). Health hazards posed by feral pigeons. *Journal of Infection* **48**, 307-313.
- Heijden, K; Szabo, M; Egami, M; Reira, M and Matushima, E (2005). Histopathology of tick-bite lesions in naturally infested capybaras (*Hydrochoerus hydrochaeris*) in Brazil. *Experimental and Applied Acarology* **37**, 245-255.
- Hilger, C; Bessot, JC; Hutt, N; Grigioni, F; Blay, F; Pauli, G and Hentges, F (2005). IgE-mediated anaphylaxis caused by sites of the pigeon tick *Argas reflexus*: cloning and expression of the major allergen Arg r1. *Journal of Allergy and Clinical Immunology* **115**, 617-622.
- Hoogstraal, H (1985). Argasid and nuttalliellid ticks as parasites and vectors. *Advances Parasitology* **24**, 135-238.
- Jeffrey, G and Demain, MD (2003). Papular Urticaria and Things that Bite in the Night. *Allergic Dermatoses and Urticaria* **3**, 291-303.
- Kain, KC (1999). Skin lesions in returned travelers. *Travel Medicine* **83**, 1077-1102.
- Kleine-Tebb, J; Herold, D; Dautel, H; Vater, G; Heinatz, A; Schroder, I; Haut, A; Mittag, T; Lange, I; Rytter, M and Haustein, UF (1999). The Pigeon Tick (*Argas reflexus*): Zentralblatt for Severe Allergic Bite Reactions in Humans. *Zentralbl Bakteriologie* **289**, 754-755.
- Kleine-Tebbe, J; Heinatz, A; Graser, I; Dautel, H; Hansen, GN; Kespohl, S; Rihs, HP; Raulf-Heimsoth, M; Vater, G; RyHer, M and Haustein, UF (2006). Bites of the European pigeon tick (*Argas reflexus*): Risk of IgE-mediated sensitizations and anaphylactic reactions. *Journal of Allergy and Clinical Immunology* **117**, 190-195.
- Kleine-Tebbe, J; Heinatz, A; Schroder, I; Dautel, H; Nordskov-Hansen, G and Haustein, UF (1998). Positive skin prick tests (SPT) and specific IgE (sIgE) to allergens of the pigeon tick (*Argas reflexus*) in patients with local and/or systemic bite reactions. *Journal of Allergy and Clinical Immunology* **101**, S159.
- Klotz, JH; Klotz, SA and Pinnas, JL (2009). Animal bites and stings with anaphylactic potential. *Journal of Emergency Medicine* **36**, 148-156.
- Kopecky, J and Kuthejlov, M (1998). Suppressive effect of *Ixodes ricinus* salivary gland extract on mechanisms of natural immunity in vitro. *Parasite Immunology* **20**, 169-174.
- Kopecky, J; Kuthejlov, M and Pechov, J (1999). Salivary gland extract from *Ixodes ricinus* ticks inhibits production of interferon- $\gamma$  by the upregulation of interleukin-10. *Parasite Immunology* **21**, 351-356.
- Kovar, L (2004). Tick Saliva in Anti-Tick

- Immunity and Pathogen Transmission. *Folia Microbiology* **49**, 327–336.
- Kovar, L; Kopecky, J and Rihova, B (2002). Salivary gland extract from *Ixodes ricinus* tick modulates the host immune response towards the TH2 cytokine profile. *Parasitology Research* **88**, 1066–1072.
- Krinsky, WL (1983). Dermatoses associated with the bites of mites and ticks (Arthropoda: Acari). *International Journal of Dermatology* **22**, 75-91.
- Kubes, M; Fuchsberger, N; Labuda, M; Zuffov, E and Nuttall, PA (1994). Salivary gland extracts of partially fed *Dermacentor reticulatus* ticks decrease natural killer cell activity in vitro. *Immunology* **82**, 113–116.
- Kubes, M; Kopecky, P; Slovák, M; Slavkov, M; Fuchsberger, N and Nuttall, PA (2002). Heterogeneity in the effect of different ixodid tick species on human natural killer cell activity. *Parasite Immunology* **24**, 23–28.
- Latif, AA; Maina, JN; Dhadialla, TS and Nokoe, S (1990). Histological reactions to bites of *Amblyomma variagatum* and *Rhipicephalus appendiculatus* (Acari; Ixodidae) fed simultaneously on naïve or sensitized rabbits. *Journal of Medical Entomology* **27**, 316-323.
- Latif, AA; Punyau, DK; Capstick, PB; Nokoe, S; Walker, AR and Fletcher, JD (1991). Histopathology of attachment sites of *Amblyomma variegatum* and *Rhipicephalus appendiculatus* on Zebu cattle of varying resistance to ticks. *Veterinary Parasitology* **38**, 505-513.
- Lima, MF; Szabo, MP and Bechara, GH (2004). Microscopic features of tick-bite lesions in anteaters and armadillos: Emas National Park and the Pantanal region of Brazil. *Annals of the New York Academy Sciences* **1026**, 235-241.
- Mans, BJ; Andersen, JF; Schwan, TG and Ribeiro, JMC (2008). Characterization of anti-hemostatic factors in the argasid, *Space Argas monolakensis*: Implications for the evolution of blood-feeding in the soft tick family. *Insect Biochemistry and Molecular Biology* **38**, 22–41.
- Marshall, J (1967). Ticks and the human skin. *Dermatologica* **135**, 60-65.
- McGinley-Smith, DE and Tsao, SS (2003). Dermatoses from ticks. *Journal of American Academy Medical Dermatology* **49**, 363-392.
- McLaren, DJ; Worms, MJ; Brown, SJ and Askenase, PW (1983). *Ornithodoros tartakovskyi*: quantitation, ultrastructure of cutaneous basophil responses in the guinea pig. *Experimental Parasitology* **56**, 153-168.
- Miadonna, A; Tedeschi, A; Leggieri, E; Falagiani, P; Nazzari, M; Manzonei, M and Zanussi, C (1982). Anaphylactic shock caused by allergy to the venom of *Argas reflexus*. *Annals of Allergy, Asthma and Immunology* **49**, 293–294.
- Montasser, AA; Marzouk, AS; El-Alfy, SH and Baioumy, AA (2011). Efficacy of abamectin against the fowl tick, *Argas (Persicargas) persicus* (Oken, 1818) (Ixodoidea: Argasidae). *Parasitology Research* **109**, 1113-1123.
- Oleaga, A; Escudero-Poblacion, A; Camafeita, E and Perez-Sanchez, R (2007). A proteomic approach to the identification of salivary proteins from the argasid ticks *Ornithodoros moubata* and *Ornithodoros erraticus*. *Insect Biochemistry and Molecular Biology* **37**, 1149–1159.
- Pearce, RL and Grove, DI (1987). Tick infestation in soldiers who were bivouacked in the Perth region. *Medical Journal of Australia* **146**, 238-240.
- Ramachandra, RN and Wikel, SK (1992). Modulation of host-immune responses by ticks (Acari: Ixodidae): effect of salivary gland extracts on host

- macrophages and lymphocyte cytokine production. *Journal of Medical Entomology* **29**, 818–826.
- Ribeiro, JM; Makoul, GT; Levine, J; Robinson, DR and Spielman, A (1985). Antihemostatic, antiinflammatory, and immunosuppressive properties of the saliva of a tick, *Ixodes dammini*. *Journal of Experimental Medicine* **161**, 332–344.
- Ribeiro, JM; Weis, JJ and Telford, SR (1990). Saliva of the tick *Ixodes dammini* inhibits neutrophil function. *Experimental Parasitology* **70**, 382–388.
- Riek, RF and Lavoipierre, MMJ (1954). Reaction of the skin of laboratory animals to the bites of argasid ticks. *Transactions of the Royal Society of Tropical Medicine and Hygiene* **48**, 8–9.
- Roman, E; Battesti, MR and Charret, J (1960). Parasitisme chez un nourrisson de larves hexapodes de l'acarien *Argas reflexus*. *Bulletin de la Societe de Pathologie Exotique Filiales* **53**, 420–423.
- Russell FE (1974): Dermatitis due to imbedded tick parts. *JAMA* **228**, 1581.
- Sonenshine, DE (1991). *Biology of Ticks*, Vol 1. New York: Oxford University Press, pp.134-145.
- Spiewak, R; Szostak, W; Kubicka, K; Ciura, D; Lundberg, M and Johansson, SGO (2004). An “endemic” of allergy to pigeon ticks (*Argas reflexus*) after removal of doves. In: Abstract book of the XXIII EAACI Congress. Msterdam. European Academy of Allergology and Clinical Immunology. Van Wijk RG; Frew AJ; de Groot H; Kapsenberg M; de Monchy J and Van Ufford AQ (eds), p.157.
- Spiewak, R; Lundberg, M; Johansson, G and Buczek, A (2006). Allergy to pigeon tick (*Argas reflexus*) in Upper Silesia, Poland. *Annals of Agriculture and Environmental Medicine* **13**, 107-112.
- Stefanato, CM; Phelps, RG; Goldberg, LJ; Perry, AE and Bhawan, J (2001). Type-I cryoglobulinemia-like histopathologic changes in tick bites: a useful clue for tissue diagnosis in the absence of tick parts. *Journal of Cutaneous Pathology* **29**, 101-116.
- Szabó, MPJ and Bechara, GH (1999). Sequential histopathology at the *Rhipicephalus sanguineus* tick feeding site on dogs and guinea pigs. *Experimental and Applied Acarology* **23**, 915–928.
- Tavassoli, E; Zare, S; Ghaderi, F; Tehrani, AA and Tavassoli, M (2007). Histopatological featurers of *Ornithodoros lahorensis* bite on rat. *Iranian Journal of parasitology* **2**, 17-24.
- Tavassoli, M; Pourseyed, SH; Ownagh, A; Bernousi, I and Mardani, K (2011). Biocontrol of pigeon tick *Argas reflexus*(Acari:Argasidae) by entomophatogenic fungus *Metarhizium anisopliae* (ascomycota: Hypocreales). *British Medical Journal* **42**, 1445-1452.
- Trautmann, A; Amschler, A; Schultz, KD; Brecker, EB and Klein, CE (1995). Anaphylactic reactions caused by pigeon ticks. *Dermatosen* **43**, 215-218.
- Urioste, S; Hall, LR; Telford, SR and Titus, RG (1994). Saliva of the Lyme disease vector, *Ixodes dammini*, blocks cell activation by a nonprostaglandin E2-dependent mechanism. *Journal of Experimental Medicine* **180**, 1077–1085.
- Uspensky, I (2008). Argasid (soft) Ticks (Acari: Ixodida: Argasidae). In: Encyclopedia of parasitology, Mehlborn H (ed), 3<sup>rd</sup> Edition, Springer Publishing Co., pp. 283-287.
- Venzal, JM; Estrada-Pena, A and Fernandez-Deluco, D (2007). Effects produced by



- the feeding of larvae of *Ornithodoros aff. puertoricensis* (Acari: Argasidae) on laboratory mice. *Experimental and Applied Acarology* **42**, 217-223.
- Veronez, VA; Castro, MB; Bechara, GH and Szabó, MPJ (2010). Histopathology of *Rhipicephalus sanguineus* (Acari: Ixodidae) ticks fed on resistant hosts. *Experimental and Applied Acarology* **50**, 151-161.
- Wall, R and Shearer, D (1997). *Veterinary Entomology*, 1st ed. Chapman and Hall International Thompson Publisher Company, London.
- Weckesser, S; Hilger, C; Lentz, D and Jakob, T (2010). Anaphylactic reactions to bites of the pigeon tick *Argas reflexus*. *European Journal of Dermatology* **20**, 244-245.
- Wikel, SK (1982): Immune responses to arthropod and their products. *Annual Review of Entomology* **27**, 21-48.
- Yesudian, P and Thambiah, AS (1973). Persistent papules after tick-bites. *Dermatologica* **147**, 214-218.

## ارزیابی چهره هیستوپاتولوژیک گزش کنه آرگاس رفلکسوس در کبوتر

مریم قلی زاده<sup>۱</sup>، موسی توسلی<sup>۱</sup>، فرید رضایی<sup>۲</sup>، زهرا نیکوصفت<sup>۳</sup>

<sup>۱</sup>گروه پاتوبیولوژی، دانشکده دامپزشکی، دانشگاه ارومیه، ارومیه، ایران

<sup>۲</sup>گروه پاتوبیولوژی، دانشکده دامپزشکی، دانشگاه رازی، کرمانشاه، ایران

<sup>۳</sup>گروه علوم درمانگاهی، دانشکده دامپزشکی، دانشگاه رازی، کرمانشاه، ایران

دریافت مقاله: ۱۳۹۳/۰۳/۲۶ پذیرش نهایی: ۱۳۹۳/۱۲/۱۲

### چکیده

آرگاس رفلکسوس یک انگل خونخوار اجباری است که ممکن است باعث واکنش‌های قرمزی پوست و تورم موضعی شود. در مطالعه حاضر به منظور ارزیابی چهره هیستوپاتولوژیک ناشی از گزش این کنه، از کبوتر به عنوان میزبان طبیعی انگل استفاده گردید. کنه‌های بالغ از شهرستان ارومیه در شمال غرب ایران جمع‌آوری شدند و تا زمان آزمایش در دسیکاتور مناسب نگهداری شدند. شانزده کبوتر به طور تجربی توسط کنه‌های بالغ آلوده شده و در ۴ گروه ۴ تایی تقسیم شدند و به ترتیب پس از ۳۰ دقیقه، ۴، ۲۴ و ۴۸ ساعت پس از آلودگی جهت ارزیابی تغییرات هیستوپاتولوژیک محل گزش کنه آسان‌کشی شدند. ضایعات هیستوپاتولوژیک اولیه بسته به زمان آلودگی شامل ادم، نقاط خونریزی، تورم عروق، نکروز و واکنش‌های التهابی خفیف تا شدید بود. در مراحل پایانی، ظهور کانون‌های آبسه‌های ریز در درمیس چهره غالب آسیب‌شناسی بود. این تحقیق به خوبی تغییرات پاتولوژیک متفاوت را در پوست کبوترهای آلوده نشان می‌دهد. با این حال، مطالعات بیشتری جهت ارزیابی پاسخ‌های ایمنوآلرژیک و تغییرات پاتولوژیک در دیگر گونه‌های حیوانی و همچنین انسان مورد نیاز است.

**واژگان کلیدی:** آرگاس رفلکسوس، کنه، کبوتر، هیستوپاتولوژی