



Morphological and morphometrical study of the fore limb bone of common eland (*Taurotragus oryx*)

^a ^a ^{a,b} ^c
Mohammad Rafiqul Islam, Latifa Akter, Imam Hasan, Md. Arman Sharif

^a Department of Anatomy and Histology, Faculty of Veterinary Science, Bangladesh Agricultural University, Mymensingh-2202, Bangladesh.

^b Department of Biotechnology and Life Sciences, University of Insubria, Via J.H. Dunant, 3, 21100 Varese, Italy.

^c Department of Anatomy and Histology, Faculty of Veterinary Medicine & Animal Science, Bangabandhu Sheikh Mujibur Rahman Agricultural University, Salna, Gazipur, Bangladesh.

ABSTRACT

This research paper presents a comprehensive morphologic and morphometric analysis of the forelimb bones (scapula, humerus, radius, and ulna) of the common eland (*Taurotragus oryx*) that are facing the threat of extinction. The study aims to contribute essential anatomical and clinical data, as well as facilitate biomedical research and educational endeavors. Bone specimens sourced from the Bangladesh National Zoo, Dhaka, were subjected to a standard hot water maceration technique, followed by sun-drying and treatment with 5% hydrogen peroxide. The scapula displayed a distinct triangular flat shape with a well-developed spine, and demarcating supraspinous and infraspinous fossae. Scapular weights were recorded at 698 gm (right) and 718 gm (left). The humerus, a robust and elongated bone measuring an average of 35.9 cm, exhibited a compressed cylindrical diaphysis and expanded epiphyses, with the right humerus weighing 944 gm and the left, 1016 gm. Notably, the humeral shaft displayed distinct regional compressions and expansions. The radius, slightly oblique and broader than the ulna, demonstrated cranial-caudal flattening. In contrast, the ulna, the longest bone at an average of 41.6 cm in the forearm, displayed distinct anatomical features. These findings offer valuable insights for comparative anatomical investigations within this taxonomic group and hold significance for clinical applications and educational purposes.

Keywords

Common eland; Scapula; Humerus; Radius; Ulna

Number of Figures: 7
Number of Tables: 4
Number of References: 26
Number of Pages: 9

Abbreviations

No abbreviations.

Introduction

The eland, a remarkable inhabitant of the African savannah, stands as the continent's second-largest antelope species, characterized by a size disparity between males and females. Within the eland genus, *Taurotragus*, the common eland (*Taurotragus oryx*), and its slightly smaller counterpart, the giant eland (*Taurotragus derbianus*), command attention [1]. Distributed across East and Southern Africa, the common eland, also known as the southern eland or eland antelope, assumes a prominent role among the savannah and plains antelopes [1]. This species falls within the Artiodactyla order, the Bovidae family, and the *Taurotragus* genus, a lineage initially outlined by Peter Simon Pallas, a distinguished German biologist and botanist, in 1766.

Eland's behavioral patterns have fascinated researchers, as it exhibits crepuscular tendencies—actively foraging during cooler periods, particularly in the early mornings and late evenings [2]. Remarkably, the common eland holds the potential for domestication, finding utility in meat and dairy production, coupled with its amenability to taming [3]. The eland's physiological efficiency, marked by low water requirements and substantial milk output, further supports its suitability for domestication [4]. While the physiological and behavioral dimensions of the common eland have attracted scholarly attention, a comprehensive elucidation of its skeletal composition remains notably absent. In the realm of anatomical education and research, the demand for accurate teaching aids remains pronounced, particularly within disciplines such as anatomy and biology. This need holds relevance in veterinary studies, facilitating a deeper comprehension of animal anatomy during the preclinical phase [4]. The skeleton, a structural cornerstone, furnishes critical support and protection to an organism's soft tissues [5]. Museums, research institutions, schools, and environmental organizations house vertebrate skeletons, pivotal in research and educational initiatives [6]. Among skeletal segments, the appendicular skeleton, comprising the limb bones, assumes significance in understanding animal locomotion and form [7].

This study embarks on the preparation and examination of the forelimb bones of the common eland, offering valuable insights for veterinary studies and facilitating an enhanced understanding of animal anatomy. Traditional skeletal preparation techniques, widely employed by anatomists, entail a considerable time investment, ranging from one to two months, contingent on the animal's size [8]. However, while extensive studies have explored the skeletal systems of diverse species—ranging from large ruminants such

as cattle, small ruminants such as sheep and goats, [5], pet animals such as dogs [5, 9-10] and cats [11], wild carnivores such as tiger [12], leopard and Asiatic cheetah [13], West African giraffe [14, 15], the African elephant [16], Guinea pig, rat and rabbit [17] have been documented. However, the morphology and morphometrics of the common eland's skeletal system have remained relatively uncharted territory.

This research endeavors to address this gap, focusing on a comprehensive morphologic and morphometric analysis of the common eland's forelimb bones. By shedding light on the osteological intricacies of this species, the study not only aids in distinguishing it from other domestic ruminants but also presents insights applicable to surgical procedures and radiographic interpretations, thereby enriching the understanding of anatomical structures in practical contexts.

Results and Discussion

The forelimb of the common eland was comprised of several key elements, including the scapula, humerus, radius-ulna, carpals, metacarpals, and digits (manus). This comprehensive study delves into the general morphological and morphometric characteristics of the scapula, humerus, and radius-ulna, comparing these features with those of other domestic and wild animals.

Scapula Morphology

The scapula of the common eland exhibited a distinctive, large, triangular-shaped flat bone structure, featuring lateral and medial surfaces, as well as three borders: cranial, caudal, and dorsal. These characteristics were found to be comparable to various species, including cattle [5], sheep, horses [5], lions [19], and dogs [9]. The scapula's weight was recorded as 698 gm for the right side and 718 gm for the left side (Table 1). It displayed an oblique and downward orientation, with a slight curvature and greater width dorsally compared to ventrally. Notably, the cranial border was convex, rough proximally, concave, and smooth distally, measuring an average length of 38.5 cm (Figure 1). The dorsal border, while slightly convex, proved to be the shortest (average 20.8 cm) among the borders (Table 1). In contrast, small ruminants tend to have a longer dorsal border and a narrower neck. Distinctive to the scapula of the common eland, the caudal border exhibited convexity along the proximal two-thirds and concavity along the distal third. This pattern of border differentiation was also observed in various domestic ruminants such as cattle [20], sheep [5], Black Bengal goats [21], and wild ruminants like

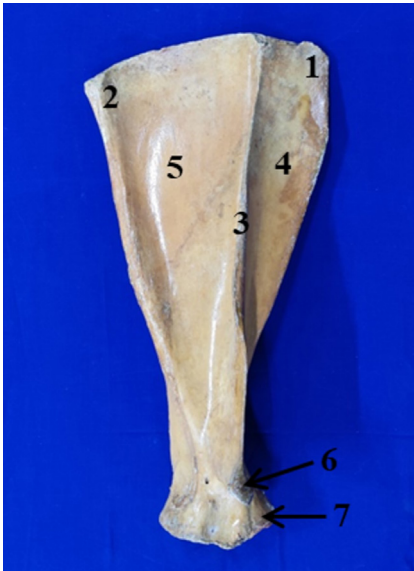


Figure 1. Lateral aspect of Scapula. 1= Cranial angle, 2= Caudal Angle, 3= Spine of Scapula, 4= Supraspinous fossa, 5= Infraspinous fossa, 6 = Acromion process, 7= Supraglenoid Tubercle.

giraffes [14, 15] and horses [20]. However, pigs [9] and certain carnivores displayed contrasting border configurations, with pigs appearing rhomboid and carnivores adopting a D-shaped structure. Moreover, the scapula's dorsal border measurements exhibited slight differences between the right (20.7 cm) and left (20.9 cm) sides, while the largest distance between the glenoid cavity and the dorsal border was 41.5 cm (Table 1).

Scapular Fossae and Spine

The lateral surface of the scapula was characterized by the presence of two fossae: a cranio-dorsal supraspinous fossa and a caudo-ventral infraspinous fossa, divided by a well-developed scapular spine (Figure 1). This spinal feature, more prominent and less sinuous in the common eland, displayed distinct bending characteristics. Unlike the horse [5], where a small spinal tuber was observed centrally, the scapular spine of the common eland lacked this feature. Additionally, the spine's projection in the pig [22] significantly differed from the findings of this study. Furthermore, the acromion process of the scapula extended prominently from the spine like cattle, sheep, Black Bengal goats, and dogs. Comparable to lions [19] and African elephants [23], the acromion process in the common eland presented an overhanging structure toward the glenoid notch. The average length of the scapular spine in the studied individual was 36.75 cm, contributing to its unique morphology (Table 1). Notably, the infraspinous fossa was larger than the supraspinous fossa, maintaining a 3:1 ratio (Figure 1),

Table 1. Morphometric data for various features of the scapula (N = 2)

Parameters	Measurements (cm)	
	Right	Left
Border:		
Cranial	39	38
Caudal	37.5	37.3
Dorsal	20.7	20.9
Length of spine	36.8	36.7
Maximum length of dorsal border to the glenoid cavity	41.6	41.4
Height of supraspinous fossa to spine	5.0	4.8
Height of infraspinous fossa to spine	4.8	4.6
Glenoid cavity:		
Height	6.5	6.5
Width	6.9	6.8

consistent with patterns observed in various ruminant and non-ruminant species [5]. The supraspinous fossa housed the supraspinatus muscle, while the infraspinous fossa accommodated the infraspinatus muscle, resembling muscle distribution in other domesticated and wild animals.

Subscapular Fossa and Glenoid Cavity

The medial surface of the scapula revealed a shallow middle subscapular fossa, hosting the subscapularis muscle (Figure 2). Notably, the areas designated



Figure 2. Medial aspect of the scapula. 1= Cranial angle, 2= Caudal angle, 3= Caudal Ridge, 4= Cranial Ridge, 5= Dorsal Margin, 6= Cranial margin, 7= Caudal Margin, 8= Scapular notch.

for the attachment of serratus ventralis muscles lacked distinct boundaries from the subscapularis fossa. This finding contrasted with cattle [24], sheep, and goats [24], where distinct boundaries were evident. The distal extremity of the scapula, connected to the bone's body by the neck, featured the glenoid cavity for articulation with the humerus. This glenoid cavity displayed circular characteristics akin to cows, Black Bengal goats, sheep, horses, and giraffes. In comparison, variations were observed in the shape of the glenoid cavity among other species, such as the elongated cavity in Asian elephants [25], the pear-shaped cavity in cats [11], and the shallow cavity in dogs [9]. Moreover, the edge of the glenoid cavity exhibited a slight cranial indentation. The presence and distinctness of the glenoid notch, however, varied across species, with more distinct notches observed in horses [5], dogs [9], and cats [11], but there is no distinct notch in Black Bengal goats [21], sheep, cattle [5]. The presence of the small and rounded supraglenoid tubercle, located close to the glenoid cavity on the cranial aspect of the scapula in the common eland, aligned with cattle features, is different from those seen in horses [5], dogs [9], and cats [11]. On the medial aspect of the glenoid angle, the tiny, rounded coracoid process was projected caudally to the supraglenoid tubercle, like that of cattle, horses [5], giraffes [14, 15], and other wild animals.

Humerus Morphology

The humerus, forming the arm of the common eland, constituted a prominent bone within the appendicular skeleton. It extended proximally from the scapula to the elbow distally, serving as a crucial link between the shoulder and the radius-ulna complex. The humerus displayed distinctive characteristics, both in terms of its length and various structural features, as discussed below. The average length of the humerus in the common eland was measured at 35.9 cm. Notably, variations were observed in weight between the right humerus (944 gm) and the left humerus (1016 gm), suggesting subtle asymmetry between the limbs (Table 2). The humerus comprises three main components: the body or shaft, the proximal extremity, and the distal extremity. The shaft exhibited an irregular cylindrical shape and displayed a noticeable twist, contributing to its unique appearance (Figure 4). The length of the shaft averaged 22.55 cm, and it was characterized by upper, middle-, and lower-part circumferences, measuring 22.15 cm, 15.95 cm, and 16.9 cm, respectively (Table 2). This complex configuration is distinct from

other species and could reflect adaptations related to locomotion and muscle attachment.

Musculospiral Groove and Medial Surface

The lateral surface of the humerus featured a shallow spiral groove, referred to as the musculospiral groove, designated for the attachment of the brachialis muscle (Figure 5). This groove encircled the cranial surface and connected proximally to the caudal surface. Comparatively, this groove exhibited variations among different species, with shallow features in cattle, a more spiral and deeper groove in horses [5], and minimal presence in giraffes [14, 15]. The medial surface of the humerus blended with the cranial and caudal surfaces, appearing rounded from side to side. The teres major tuberosity was positioned proximal to the midpoint, similar to observations in horses and cattle [5], while being absent in giraffes [14, 15]. This distinct arrangement likely contributes to the functional capabilities of the humerus within the common eland's limb structure. The crest of the humerus served as a demarcation between the cranial and lateral surfaces of the bone. The lateral surface, extending proximally, exhibited a smooth and wide configuration, which gradually transformed into a rough and narrow texture distally (Figure 5). In comparison to cattle [24], the deltoid tuberosity of the common eland's humerus, where the deltoideus

Table 2. Morphometric data for various features of the humerus (N = 2)

Parameters	Measurements (cm)	
	Right	Left
Total length	35.8	36.0
Shaft:		
Length	22.5	22.6
Circumference of the upper part	22.3	22.0
Circumference of the middle part	16.1	15.8
Circumference of the lower part	17.0	16.8
Circumference of head	26.6	27.0
Proximal extremity:		
Circumference	39.5	41.0
Width	12.2(cr-cau) 12.5(L-M)	12.3(cr-cau) 12.7(L-M)
Distal extremity		
Circumference	29.0	28.5
Width	9	8.9

muscle attached, was less prominent. This contrasts with horses, where the deltoid tuberosity was more pronounced [5]. Additionally, a small prominence known as the teres minor tuberosity was located proximal to the deltoid tuberosity, further enhancing the muscle attachment site (Figure 4, 5). Notably, these tuberosities were absent in giraffes [14, 15], differing from the observations in the present study. In sheep, the deltoid tuberosity was less prominent and closer to the proximal end [5], showcasing variations in muscle attachment across species. The lateral head of the triceps brachii muscle was attached to the humeral neck on the lateral surface by a curving line proximal to the deltoid tuberosity. The cranial surface of the shaft of the humerus ended at the radial fossa distally. The caudal surface is smooth, almost straight, rounded from side to side, and ends distally at the olecranon fossa (Figure 4). The nutrient foramen was located almost at the middle of the caudal surface of the humerus (Figure 4) like sheep [5], and Black Bengal goats [21]. According to [5], the nutrient foramen of cattle is placed in the distal third of the caudal surface of the humerus, but that of horses is positioned in the distal third of the medial surface of the humerus. In Asiatic cheetah, there were two main nutrient foramina on the shaft of the humerus: one was on the roof of the olecranon fossa, and the other was proximal to the su-

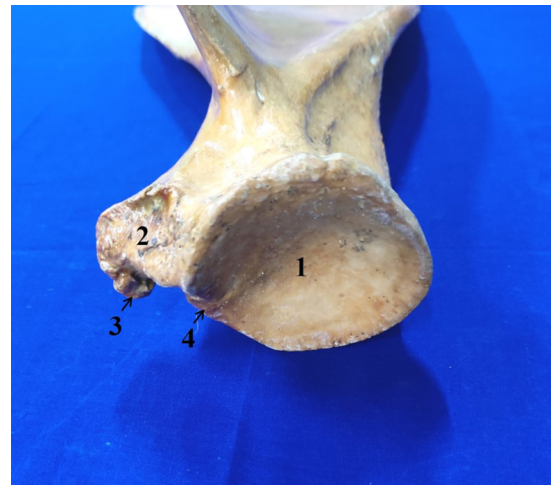

Figure 3. Distal aspect of Scapula. 1= Glenoid cavity, 2= Supraglenoid tuberosity, 3= Coracoid process, 4= Glenoid notch.

pratrochlear foramen on the medial surface [26]. The head, neck, two tuberosities, and intertuberal groove made up the proximal extremity. The neck of the humerus was clearly defined caudally.

Proximal Extremity and Tuberosities

The proximal extremity of the humerus encompassed several key features, including the head, neck, two tuberosities (greater and lesser), and the intertuberal groove (Figure 4). The head, with its rounded

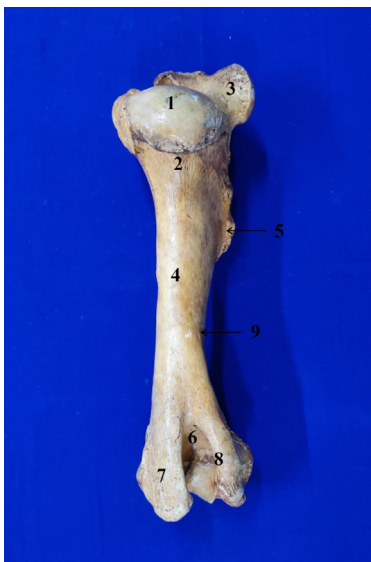


Figure 4. Humerus (caudal view); 1= Head of humerus, 2= Neck of humerus, 3= Major (lateral) tuberosity, 4= Body of humerus, 5= Deltoid tuberosity, 6= Olecranon fossa, 7= Medial epicondyle, 8= Lateral epicondyle, 9= Nutrient foramen.

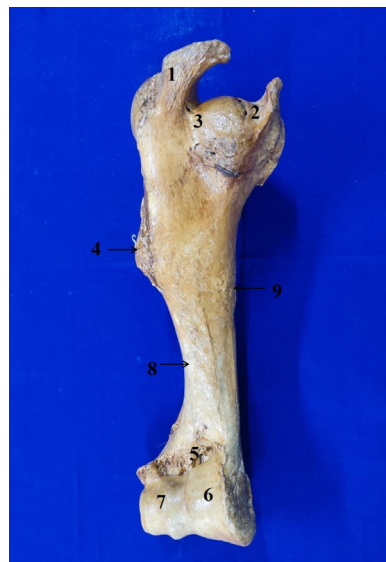

Figure 5. Humerus (cranial view); 1= Major (lateral) tuberosity, 2= Minor (medial) tuberosity, 3= Intertuberal groove, 4= Deltoid tuberosity, 5= Radial fossa, 6= Trochlea, 7= Capitulum, 8= Musculo-spiral groove for brachialis, 9= Teres major tubercle.

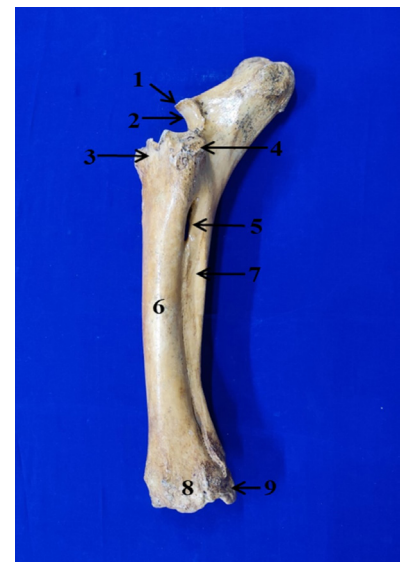


Figure 6. Radius and ulna (lateral view); 1= Anconeal process, 2= Trochlear notch, 3= Radial tuberosity, 4= Tuberosity for attachment of the lateral collateral ligament of the elbow joint, and extensor digitorum communis and lateralis, 5= Proximal interosseous space, 6= Shaft of radius, 7= Shaft of ulna, 8= Tuberosity for attachment of lateral collateral ligament of carpal joint, 9= Styloid process of ulna.

shape and convex articular surface, facilitated articulation with the glenoid cavity of the scapula. The greater tubercle, positioned cranio-laterally, extended approximately 2-3 cm beyond the head level, forming the shoulder point. This tubercle was divided into cranial and caudal parts, which played a role in delineating the lateral limit of the intertuberal groove (Figure 4). In contrast, the lesser tubercle was less prominent, possessing both cranial and caudal portions. The intertuberal groove, positioned cranially and undivided, represented a notable feature of the humerus. This arrangement differed from species like horses, Asiatic cheetahs, and giraffes, which exhibited an intermediate tubercle that divided the intertuberal groove [5, 14-15, 26].

Distal Extremity and Articulation Surfaces

The distal extremity of the humerus featured the medial epicondyle and lateral epicondyle, alongside radial and olecranon fossae (Figure 4). The trochlea (medial condyle) and capitulum (lateral condyle) provided oblique articular surfaces for articulation with the radius and ulna (Figure 5). The trochlea, larger than the capitulum, displayed a sagittal groove that extended up to the olecranon fossa. This deep fossa accommodated the ulna's anconeal process, ensuring functional integration with the radius-ulna complex (Figure 5). The radial fossa, situated cranially proximal to the trochlea's sagittal groove, was consistent with patterns observed in other species. All these characteristics are like cattle, horses, sheep [5], Asiatic cheetahs and Asian elephants [26], and giraffes [14, 15]. Black Bengal goats had shallow radial and olecranon fossae [21], whereas, in dogs, these two fossae frequently communicate with one another through a wide supratrochlear foramen [9]. The craniocaudal diameter of the proximal and distal extremities was 12.25 cm and 8.95 cm (average), respectively (Table 2).

Radius and Ulna

The forearm of the common eland is composed of two bones: the radius and ulna. The weights of the right and left radius-ulna were measured at 934 gm and 986 gm, respectively (Table 3). While the shafts of both the radius and ulna were largely fused, except for the proximal and distal interosseous spaces, there were notable differences in their relative lengths. Specifically, the ulnar bone was longer than the radius in the common eland, a characteristic shared with cattle [5], Black Bengal goats [21], and giraffes [14, 15]. This contrasts with horses, where the radius tends to be larger than the ulna. The radius was po-

sitioned craniolaterally to the ulna, articulating with the humerus at its proximal end and craniomedially at the carpal joint (Figure 6). Both bones exhibited convex cranial surfaces and concave caudal surfaces, with the ulna being thinner and fused cranially to the caudal surface of the radius, apart from the interosseous spaces. This anatomical arrangement shared similarities with cattle [5], Black Bengal goats [21], and giraffes [14, 15].

Radius Characteristics

The radius, shorter and broader than the ulna, displayed an oblique orientation, being flattened craniocaudally. It consisted of a shaft and two extremities: proximal and distal (Figure 6). The shaft's average length was 33.9 cm, with a middle part circumference of 14.15 cm (Table 3). Longitudinally curved, the radius featured a smooth, convex cranial surface and a concave caudal surface along its length. Notably, two distinct borders, lateral and medial, were observed. This contrasts with the giraffe's elongated linear-shaped radius [14, 15] and is consistent with the morphology of domestic ruminants like cows [24] and the common eland. A shallow, smooth groove was observed along the caudal border, forming the proximal interosseous space in coordination with the ulna. The distal interosseous space was notably narrow and elongated in the distal part of the radius shaft, differing from horses where this space is absent [5]. Furthermore, the distal interosseous space was small and indistinct in Black Bengal goats [21], whereas it was entirely absent in Asian elephants [25].

Table 3. Morphometric data for various features of radius (N = 2)

Parameters	Measurements (cm)	
	Right	Left
Total length	34.0	33.8
Proximal extremity:		
Circumference	25.9	25.8
Width	10.0(L-M) 5.3(Cr-Cau)	9.8(L-M) 5.4(Cr-Cau)
Distal extremity:		
Circumference	23.1	23.5
Width	7.8(L-M) 6.2(Cr-Cau)	7.8(L-M) 6.1(Cr-Cau)
Circumference of shaft:		
Upper	16.5	16.2
Middle	14.1	14.2
Lower	15.4	15.0

The proximal extremity, or head, of the radius, was transversely widened and flattened craniocaudally. It featured two proximal attachments: one with the humerus and another with the medial ulnar surface. A concave articular surface, merging with a notch for articulation with the humeral condyle, was evident on the proximal extremity. Below the edge of this articular surface, the medial and lateral tuberosities were located. A raised, rough area on the cranial surface of the proximal extremity, termed the radial tuberosity, was also observed (Figure 6). The distal extremity was similarly flattened craniocaudally, forming the trochlea. It presented three articular surfaces that articulated with the proximal row of radial, intermediate, and ulnar carpal bones. This configuration corresponded with observations in domestic ruminants [5] and Black Bengal goats [21].

Ulna Characteristics

The ulna, constituting the longest bone with an average length of 41.6 cm in the forearm of the common eland (Table 4), exhibited a relatively underdeveloped structure that was fused with the radius along its caudolateral side. The ulnar shaft, triangular, featured three surfaces and tapered distally (Figure 7). The proximal end of the ulna was notably prominent, possessing a larger circumference (average of 15.3 cm) compared to the distal end (average of 7.2 cm) (Table 4). At the proximal end of the ulna, the olecranon projected beyond the radius, and its free end expanded to form the olecranon tuber (Figure 7). The olecranon process was composed of two surfaces and two borders. The medial surface was concave, while the lateral surface was convex. The anconeal process, characterized by a sharp border, protruded cranially proximal to the articular surface. The trochlear notch, wider at its cranial part, was positioned proximally. On either side of the articular surface, the lateral and medial coronoid processes extended distally, creating a concave surface for articulation, and continued the trochlear notch proximally. In the distal extremity of the ulna, articulation with the accessory carpal bone and the ulnar carpal bone was observed in the common eland. The ulnar carpal bone's lateral facet was formed by extending the distal end downward to create the lateral styloid process, a feature consistent with findings in cattle, sheep [5], Black Bengal goats [21], West African giraffes [14, 15], Asiatic cheetahs, and Asian elephants [26]. However, this characteristic was absent in horses [5]. Contrary to horses [5], in the common eland of this study, the ulna extended to the distal extremity of the radius. This alignment corresponded with observations in cattle [24], sheep [5], Black Bengal goats [21], West African giraffes [14, 15], Asiatic cheetahs, and Asian elephants [26]. In

Table 4.

Morphometric data for various features of the ulna (N = 2)

Parameters	Measurements (cm)	
	Right	Left
length	41.7	41.5
Proximal extremity:		
Circumference	15.4	15.2
Width	6.2	6.5
Distal extremity:		
Circumference	7.2	7.1
Shaft:		
Upper	6.2	6.1
Middle	7.2	7.1
Lower	4.8	4.8

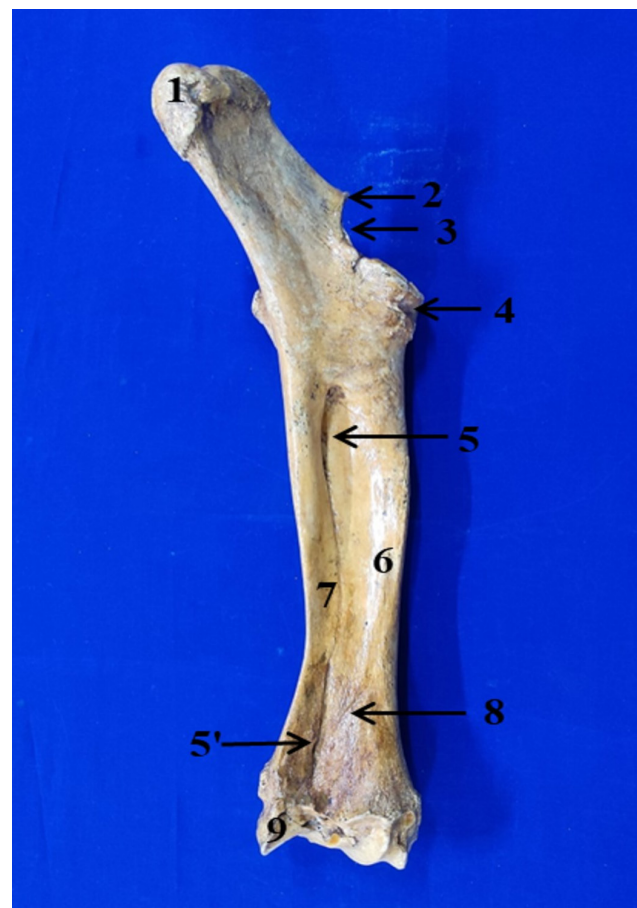


Figure 7.

Radius and ulna (caudomedial view); 1= Olecranon, 2= Anconeal process, 3= Trochlear notch, 4= Proximal extremity of radius, 5, 5'= Proximal and distal interosseous spaces, 6= Shaft of radius, 7= Shaft of ulna, 8= Vascular groove, 9= Styloid process of the ulna.

contrast, the ulna was fused with the proximal third of the radius in horses [5].

Materials and Methods

Specimen Collection

This common eland, aged 16 years and weighing 475 kg, died due to age-related complications at the Bangladesh National Zoo, Dhaka, in November 2020. The bones were collected from the deep burial with aseptic measure from National Zoo, Dhaka, Bangladesh. The bones were transported under aseptic conditions to the laboratory of the Department of Anatomy and Histology, Faculty of Veterinary Science, Bangladesh Agricultural University. The objective was to prepare bones for museum specimens and educational purposes, with official authorization from the director of Bangladesh National Zoo (Order on.01/2021/217).

Preparation of Bones

The bones were collected in a sequential manner, processed by removing the mud with a brush, and washed under running tap water, followed by dipping in detergent water for 2 hours. Bones were then subjected to boiling in 5% soda water for 1 hour, followed by a 7-day immersion in the same solution. This process aimed to facilitate the complete digestion of extra muscles, tendons, ligaments, and associated structures, drawing from the methodology outlined by [18]. The container housing the bones was hermetically sealed, placed in a shaded area at room temperature, and left undisturbed throughout this period. Post 7 days, bones of the forelimbs (scapula, humerus, radius, and ulna) were retrieved, with excess tissues meticulously removed using a blade. The collected bones underwent a thorough cleaning process using detergent and were subsequently rinsed extensively under running water. Cleaned bones were immersed in a container filled with a 5% hydrogen peroxide solution. Repeated rinsing under running water ensued until the bones reached the desired level of whiteness. This step aimed to enhance bone aesthetics. A 10% bleaching water solution was used to submerge the bones for two hours, thereby forestalling potential microbial degradation. Sun exposure facilitated the complete drying of the bones.

Biometric Study

The morphological parameters of each forelimb bone were meticulously examined from various angles. A digital balance was employed to measure the bone weight in grams (gm). Additionally, metallic calibrated scales facilitated precise measurements of bone length, width, height, and circumference in (cm). To document the findings, individual photographs of the prepared bones were captured using a digital camera.

Conclusion

In conclusion, this comprehensive study focused on the gross anatomy of the forelimbs of the common eland has elucidated distinct characteristics, as well as differences and similarities with other mammals. Through meticulous examination of morphometrical and morphological features, valuable insights were gained into the structural attributes of the bones. This knowledge bears significance for diverse applications, including bone identification, radiographic interpretation, and forensic investigations involving the common eland. Furthermore, these findings pave the way for a deeper comprehension of the precise anatomical parameters, ultimately contributing to the enhancement of veteri-

inary care practices.

Authors' Contributions

M.R.I., I.H. conceived and planned the experiments. M.R.I., I.H. carried out the experiments. M.R.I., I.H., contributed to sample preparation. L.A., contributed to the interpretation of the results. M.R.I., L.A., A.S. took the lead in writing the manuscript. All authors provided critical feedback and helped shape the research, analysis and manuscript.

Acknowledgements

The authors would like to express their gratitude to Bangladesh National Zoo, Dhaka, Bangladesh for giving permission to collect the bones of Common Eland for the Anatomy museum of BAU.

Competing Interests

The authors declare they have no conflict of interest associated with this work.

References

- Pappas LA. *Taurotragus oryx*. Mammalian Species, 2002. 689:1-5. Doi:10.1644/1545-1410(2002)689<0001:to>2.0.co;2.
- Lewis JG. Game domestication for animal production in Kenya: shade behaviour and factors affecting the herding of eland, oryx, buffalo and zebu cattle. *The J Agric Sci*. 1978 90(3): 587-595. Doi: 10.1017/S0021859600056124.
- Lightfoot CJPJ. Eland (*Taurotragus oryx*) as a ranching animal complementary to cattle in Rhodesia. *J Rhod Agr*. 1977; 74:47-120.
- Posselt J. The domestication of the Eland. *Rhodesian J Agri R*. 1963:81-87.
- Getty R (1975) *General osteology The Anatomy of the Domestic Animals*. Philadelphia & London. W. B. Saunders Company. 5th edn.
- Bemis WE, Hilton EJ, Brown B, Arrindell R, Richmond AM, Little CD, Nelso GJ (2004) *Methods for preparing dry, partially articulated skeletons of osteichthyans, with notes on making Ridewood dissections of the cranial skeleton*. *Copeia*, 3: 603-609. Doi:10.1643/CI-03-054R1.
- RK Ghosh. *Primary Veterinary Anatomy*. 2006 4th edn.
- Gofur M and Khan M. Development of a quick, economical and efficient method for preparation of skeleton of small animals and birds. *Env. Sci*. 2010; 2(7):13-7.

9. Evans Hedla. Miller 's Anatomy of the Dog. Philadelphia,W. B. Saunders Company. 2013; 4th edn:177–96.
10. Stark H, Fischer MS, Hunt A, Young F, Quinn R, Andrada E. A three-dimensional musculoskeletal model of the dog. *Scie Rep*. 2021; 11(1):1-13. Doi: 10.1038/s41598-021-90058-0.
11. Reighard. Anatomy of the cat. Henry Holt and Company, New York, 1935; 62–76.
12. Tomar MPS, Taluja JS, Vaish R, Shrivastav AB, Shahi A Sumbria D. Gross anatomy of scapula in Tiger (*Panthera tigris*). *Ind J AnI Res*. 2018; 52(4):547–50. Doi:10.18805/ijar.B-3252.
13. Podhade DN, Shrivastava AB, Parmar ML, Vaish R, Lohkare AC, Jasutkar RK, Tiwari DK. Studies on characteristic features of patella of the leopard (*Panthera pardus*) as an aid in wildlife forensics. *Royal Vet J of India*. 2009; 5(1/2):39-40. URL: <https://www.cabdirect.org/cabdirect/abstract/20103032621>.
14. Jahan S, Sohel MSH & Rahman ML. Morphology and morphometric analysis of bones of the forelimb of giraffe (*Giraffa camelopardalis*). *Bangladesh J Vet and Ani Sci*. 2021; 9(1): 59–66.
15. Onwuama KT, Salami SO, Kigir ES & Jaji AZ. Gross Anatomical Studies on the Hind Limb of the West African Giraffe (*Giraffa camelopardalis* peralta). *Vete Medi Inte*, 2021 .Doi:10.1155/2021/8818525.
16. Hautier L, Stansfield FJ, Allen WT & Asher RJ. Skeletal development in the African elephant and ossification timing in placental mammals. *Proc Royal Soc Bio Sci*. 2012; 279(1736):2188-2195. Doi:10.1098/RSPB.2011.2481.
17. Özkan ZE, Dýnç GAA. Investigations on the comparative gross anatomy of scapula, clavícula, skeleton brachii and skeleton antebrachii in rabbits (*Oryctolagus cuniculus*), guinea pigs (*Cavia porcellus*) and rats (*Rattus norvegicus*). *Fýrat Uni J Heal Sci*. 1997; 11:171–175.
18. Hasan I AND Islam MR. Preparation of indigenous duck (*Anas platyrhynchos*) skeleton to enhance veterinary anatomy teaching. *Asi J Med and Bio Res*. 2019; 5(3):192–196. Doi:10.3329/AJMBR.V5I3.43587.
19. Nzalak, JO, Eki, MM, Sulaiman, MH, Umosen, AD, Salami, SO, Maidawa, SM, & Ibe, CS. Gross anatomical studies of the bones of the thoracic limbs of the Lion (*Panthera leo*). *J Vete Ana*. 2010; 3(2):65-71. Doi:10.21608/JVA.2010.44901.
20. Budras KD, Habel RE, Habel RE, Wunsche A, Buda S. *Bovine Anatomy: An Illustrated Text*. Schlütersche GmbH and Co. Hannover, Germany. 2003; 1st edn.
21. Siddiqui MSI, Khan MZI, Moonmoon S, Islam MN, Jahan MR. Macro-anatomy of the bones of the forelimb of Black Bengal goat (*Capra hircus*). *Bangladesh J. Vet. Med*,2008; 6(1):59-66. Doi:10.3329/BJVM.V6I1.1340.
22. König HE AND Liebich H. *Veterinary Anatomy of Domestic mammals*, in *Textbook and colour Atlas*. Schattauer, Stuttgart, Germany, 2004; 27–29.
23. Smuts MM and Bezuidenhout AJ. Osteology of the pelvic limb of the African elephant (*Loxodonta africana*). *The Onder J Vet Res*. 1994; 61(1):51–66.
24. Mcleod WM. *Bovine Anatomy*. Cornell University, Burgess Publishing Company. 1958; 2nd edn.
25. Ahasan, A.S.M.L. Macroanatomía de los Huesos del Miembro Torácico de un Elefante Asiático (*Elephas maximus*). *Int. J Morp*. 2016; 34(3):909–17. Doi:10.4067/S0717-95022016000300016.
26. Nazem MN, Sajjadian SM and Nakhaei A. Anatomy, functional anatomy and morphometrical study of forelimb column in Asiatic cheetah (*Acinonyx jubatus venaticus*). *Italian J Anat and Embr*. 2017; 122:157–72. Doi:10.13128/IJAE-22975.

COPYRIGHTS

©2024 The author(s). This is an open access article distributed under the terms of the Creative Commons Attribution (CC BY 4.0), which permits unrestricted use, distribution, and reproduction in any medium, as long as the original authors and source are cited. No permission is required from the authors or the publishers.

**How to cite this article**

Rafiqul Islam M, Akter L, Hasan I, Sharif MA. Morphological and morphometrical study of the fore limb bone of common eland (*Taurotragus oryx*). *Iran J Vet Sci Technol*. 2024; 16(2): 1-9.
DOI: <https://doi.org/10.22067/ijvst.2024.83739.1286>
URL:https://ijvst.um.ac.ir/article_45215.html