

## A case of atrial fibrillation in a horse: clinical and electrocardiographic features

Ali Reza Taghavi Razavizadeh<sup>\*1</sup>, Mohammad Reza Aslani<sup>2</sup>

<sup>1</sup>Department of Clinical Sciences, Faculty of Veterinary Medicine, Ferdowsi University of Mashhad, Mashhad, Iran

<sup>2</sup>Department of Clinical Sciences, Faculty of Veterinary Medicine, University of Sharekord, Iran

Received: June 06,2011

Accepted: November 29,2012

### Abstract

Atrial fibrillation (AF) was detected as an incidental finding in a 14 years old brood mare horse which was maintained for student education in the teaching hospital, Faculty of Veterinary Medicine, Mashhad. Irregular heart rhythm, variable intensity of heart sounds and "f" waves were revealed in clinical examination and electrocardiography. Hematology showed normal values and hyponutremia was observed in serum biochemical analysis. Treatment of the horse was done with oral administration of quinidine sulfate (200 mg tabs). Normal rhythm was appeared after 24 hours of treatment. Herein, we have discussed the etiology and the treatment procedure of this dysrhythmia.

**Keywords:** Atrial fibrillation, Quinidine sulfate, Electrocardiogram, Biochemical factors, Horse

---

\* Corresponding author: Ali Reza Taghavi Razavizadeh  
Email: rezavizadeh@um.ac.ir

## Introduction

Atrial fibrillation (AF), a problem affecting the atria of the heart, is the most important arrhythmia in horses. It has rarely been reported in Iran and there is only one case report of atrial fibrillation in a thoroughbred horse with a history of body condition loss and poor performance (Mokhber-Dezfuli *et al.*, 2007). Atrial fibrillation is associated with abnormal electrical activity in the atria, which prevents the normal contraction of the atrial myocardium. In these situations, cardiac output is reduced. However, exercise intolerance is the most common presenting sign in horses with AF. Less frequently, epistaxis, prolonged recovery following exercise and tachypnea are seen and occasionally congestive heart failure (CHF), collapse, ataxia, myopathies and colic are associated with AF (Patteson, 1999).

Horses are predisposed to AF because they have a high resting vagal tone and a large atrium (De Clercq *et al.*, 2006). AF in horses can be paroxysmal or persistent. Paroxysmal AF occurs occasionally in horses with other systemic diseases, particularly gastrointestinal disorders or under general anesthesia. Acquired or congenital cardiac diseases such as semilunar valvular stenosis, patent ductus arteriosus, and cardiomyopathy can also result in atrial enlargement and predispose atria to onset of atrial fibrillation. Mitral and tricuspid regurgitation are the most common coexisting cardiac diseases in horses with AF. Focal myocardial disease can result in physical heterogeneity, which also promotes the persistence of AF (Manohar *et al.*, 1992; Reef *et al.*, 1995). A report has suggested that AF may also develop secondary to myocardial hypoxia associated with primary pulmonary hypertension in young horses (Kobluk *et al.*, 1995).

Quinidine sulfate, a class I anti-arrhythmic drug, is the drug of choice for treatment of AF in the absence of underlying heart disease. This drug is contraindicated in horses with congestive heart failure or a resting heart rate

greater than 60 bpm ((Kobluk *et al.*, 1995). Treatment of AF with quinidine sulfate leads to a high success rate (85%) in cases with no anatomical lesions of the atrial myocardium (Birettoni *et al.*, 2007). In contrast to humans and dogs, horses with AF, usually have no macroscopic underlying cardiac pathology. This means that after successful medical treatment these animals can return to their previous athletic ability (De Clercq *et al.*, 2006). Quinidine sulfate prolongs the effective refractory period, suppressing the re-entry mechanisms by which AF is maintained. It also has vagolytic effects that increase AV nodal conductivity and  $\alpha$ -adrenoreceptor blocking effects, which may lead to vasodilation and hypotension. The conventional treatment regimen is the administration of 20-22 mg/kg of the drug every 2 hours until the rhythm convert to normal sinus rhythm or signs of toxicity are noticed. Treatment intervals are then prolonged to every six hours to achieve steady state plasma concentration because the half life of drug is about 6 hours. Many horses revert to sinus rhythm after a dose of approximately 30–60 g (Patteson., 1999; Kobluk *et al.*, 1995; Adams., 2001). The plasma concentration of considered therapeutic for the conversion of AF to sinus rhythm is between 2 to 5  $\mu\text{g/mL}$  (Reef *et al.*, 1995).

In addition to quinidine sulfate, amiodarone (a  $\text{K}^+$ -channel blocker) and Flecainide (a  $\text{Na}^+$  -channel blocker) are used as alternative drugs for treatment of atrial fibrillation (De Clercq *et al.*, 2006).

## Case presentation

AF was detected as an incidental finding in a 14 years old brood mare horse which was maintained for student education in the teaching hospital of School of Veterinary Medicine, Mashhad. The horse was thin with rough hairs and showed hoof deformity of the right forelimb due to chronic laminitis. Clinical examination revealed an irregular heart rhythm and variable intensity of heart

sounds. Occasionally a long pause of several seconds was noticed. The heart rate was 54 bpm. Using base – apex lead, electrocardiograms (ECGs) were taken and there was irregularly irregular R-R intervals. Coarse "f" waves were also detected on the all ECGs (Fig 1, 2).

Treatment of the horse was done with a delay of 5 months after diagnosis. It was orally treated with quinidine sulfate (200 mg tabs, Switzerland, Sigma), at a dose of 22 mg/kg, 2 times with 2 hours interval. Two hours after dosing, ECG revealed "f" waves with a saw tooth appearance and less irregularity in R-R interval (Fig 3). The rhythm converted to sinus

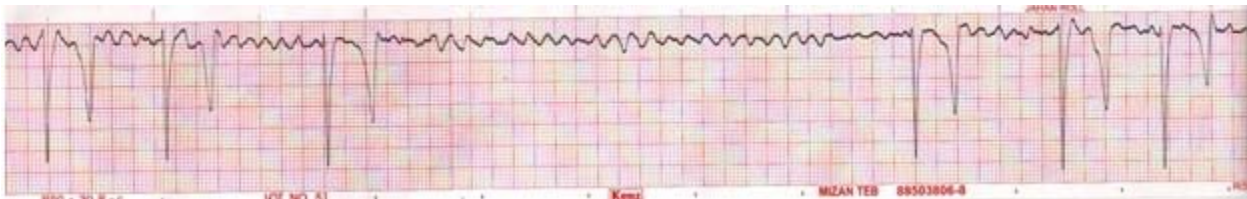rhythm 24 hours after administration of second dose (Fig4). Follow up of the case for 13 months, did not show any signs of AF.

Two blood samples were obtained, for hematology and biochemical analysis, before and after treatment with quinidine sulfate.

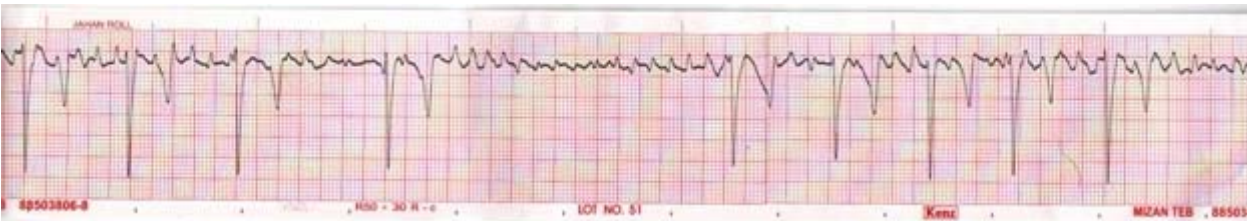CBC of the horse was in normal range. Biochemical analysis revealed a reduction in concentrations of potassium, phosphorus and BUN after treatment with quinidine sulfate (table 1). After treatment with quinidine sulfate and return of cardiac function to normal condition, the concentration of potassium, phosphorus and BUN were decreased (table 1).

**Table 1. Some biochemical factors in a horse with atrial fibrillation, before and after treatment with quinidine sulfate.**

Parameters	Before treatment	After treatment
Sodium (Meq/L)	117	135
Potassium (meq/L)	4.4	2.6
Magnesium (mg/dl)	4.10	3.89
Calcium (mg/dl)	14.9	15.1
Phosphorous (mg/dl)	3.29	2.12
Glucose (mg/dl)		118
BUN (mg/dl)	17.24	13.32
Creatinine(mg/dl)	0.843	1.09
Total bilirubin (mg/dl)	1.83	2.26
Albumin (g/dl)	3.21	3.65
ALP (U/L)	177	179
LDH (U/L)	6 81	715
AST (U/L)	349	390



**Figure 1. Electrocardiogram of the horse; 20 days Before treatment with quinidine sulfate; (10mm/mv , 25mm/S).**



**Figure 2. Electrocardiogram of the horse, immediately before treatment with quinidine sulfate.**

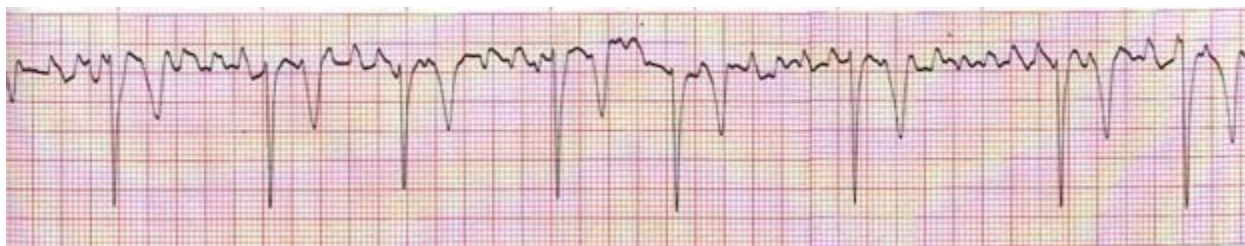


Figure 3 . Electrocardiogram of the horse , 2 hours after treatment with quinidine sulfate.

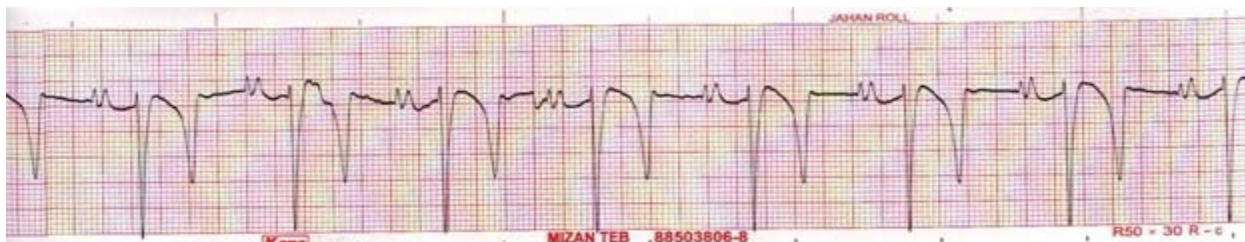


Figure 4 . Electrocardiogram of the horse, 24 hours after treatment with quinidine sulfate.

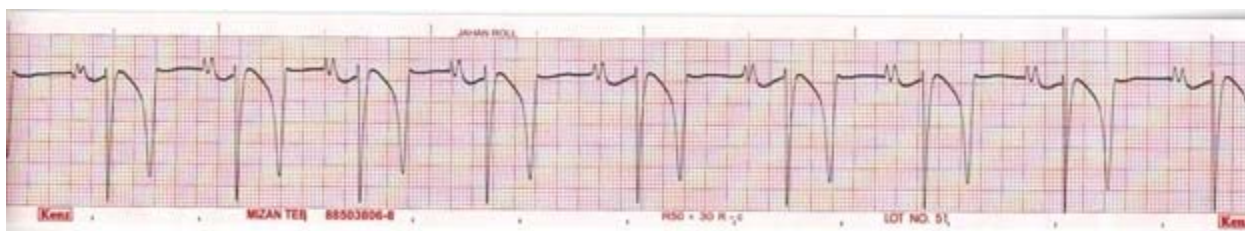


Figure 5. Electrocardiogram of the horse, 26 days after treatment with quinidine sulfate.

## Discussion

In horses with AF, the heart rate may be normal or elevated. Heart rate above 48 bpm is usually classified as tachycardia and greater than 60 bpm are strongly suggestive of the presence of underlying heart disease and congestive heart failure. The pulse quality will depend on the diastolic interval, and on the presence of any underlying heart disease. In AF, when compensatory mechanisms do not occur, the atrial component of ventricular filling is absent and cardiac output may decrease. In these horses, absence of the A sound (4<sup>th</sup> heart sound) is corresponded to the ECG finding of an absence of P waves in any lead, due to the lack of any coordinated atrial activity. The P waves are replaced by “f” waves (random and continuous undulation of the base line). The “f” waves are usually large

and coarse if AF is of recent onset and smaller or fine with longer duration AF. In AF, the R-R intervals are irregular and the rhythm can be described as irregularly irregular; this may be more obvious at normal heart rates than in tachycardias (Patteson., 1999; Kobluk et al., 1995). Because the supraventricular impulse spreads normally in the ventricles, the duration and configuration of the QRS complex remain normal (Manohar *et al.*, 1992).

Serum electrolytes should be determined in horses with AF, because electrolyte imbalances, especially potassium depletion may also contribute to this cardiac arrhythmia (Reef *et al.*, 1995). Possibly decrease in blood pressure and cardiac output due to atrial fibrillation and cardiac insufficiency causes of reduction in renal blood flow and it reduce the amount of potassium and phosphorus presented to the kidney for excretion. Acute

decreases in renal function may cause hyperkalemia and acidemia because of impaired renal excretion of cations (Stockman *et al.*, 2007). In this case, the concentration of potassium and phosphorus were within normal range. Occasionally, intravenous balanced replacement fluids may be necessary to improve blood pressure and renal perfusion, as pre-renal azotemia is common in these horses (Reef *et al.*, 1995).

In the present case, the concentration of sodium before starting the treatment was lower than normal values (136-142 Meq/L) (Table 1). After treatment, the concentration of serum sodium returned to normal range. Edematous disorders due to some conditions such as congestive heart failure, hepatic cirrhosis and nephritic syndrome can result to hyponatremia (Stockham *et al.*, 2002). There was no gross edema in the horse.

The concentration of AST was higher than normal range (152-294 U/L) before and after treatment, during the study, the horse was suffered from tearing of jaw muscles with halter rope, so, skeletal or possibly cardiac muscle damage can be described as the causative factor for elevation of AST in the horse. Elevation of LDH in the horse can also be related to muscle damage (normal range: 160-410 U/L) (Stockham *et al.*, 2002).

The concentration of glucose, bilirubin, creatinine, albumin and ALP unchanged before and after treatment and their values were in normal range (table 1). Although the serum concentration of calcium and magnesium were unchanged before and after the treatment, their amounts were higher compared to normal values (10.6-13 and 1.3-2 mg/dl, respectively). During quinidine treatment, the first change would be that fibrillation converts to a saw-toothed pattern in the baseline of the electrocardiogram and then sinus rhythm prevails. Immediately after conversion, the P waves are usually wide (Manohar *et al.*, 1992). The ventricular rate rises during quinidine administration because of enhanced AV conduction (vagolytic effect) (Fig. 4,5). The  $\alpha$ -adrenergic blocking effects of

quinidine may lead to hypotension, weakness, and ataxia. Therefore, horses receiving quinidine should not be moved or exercised (Reef *et al.*, 1995).

Because the AF was detected as an incidental finding, its duration was calculated from the last normal examination, so probable duration of AF was about 5 months. The prognosis for successful conversion of AF depends on the duration of the arrhythmia and the presence and severity of underlying heart disease. In horses with recently developed AF, the prognosis for successful conversion is excellent, with a recurrence rate of only 15 percent. If AF has been present for greater than 4 months, the prognosis for conversion is still good, however, the treatment period is often more prolonged, side effects of quinidine administration is more frequent, and the arrhythmia is more likely to recur, with recurrence rates of 60 percent or even greater. Poor prognostic indicators include a heart rate of more than 60 bpm (in the absence of colic or some other non-cardiac disease causing tachycardia) and loud cardiac murmurs (grade III/V or greater), clinical signs usually associated with severe underlying cardiac disease and congestive heart failure (Reef *et al.*, 1995; Kobluk *et al.*, 1995). In this case, no evidence of murmur and CHF were observed. Most of the horses that experience a recurrence of atrial fibrillation do so within 1 year of initial conversion, but periods as long as 6 years have occurred between episodes of atrial fibrillation in some horses (Reed *et al.*, 1998).

## References

- Adams, R. H. 2001. Veterinary pharmacology and therapeutics. 3 ed. Iowa state university press.
- Biretoni, F., F. Porciello, M. Rishniw, G. Della Rocca, A. Di Salvo, and M. Sqorbini. 2007. Treatment of chronic atrial fibrillation in the horse with flecainide: personal observation. *Veterinary Research Communication*

- 31,273-275.
- De Clercq, D., G. van Loon, K. Baert, R. Tavernier, S. Croubels, P. De Backer, and P. Deprez. 2006. Intravenous amiodarone treatment in horses with chronic atrial fibrillation. *The Veterinary Journal* **172**, 129–134.
- Kobluk, C. N., T. R. Ames, and R. J. Geo. 1995. *The horse, Diseases and Clinical Management*. W.B. Saunders. Philadelphia.
- Manohar, M. and D. L. Smertzer. 1992. Atrial fibrillation. *The Compendium, Small Animal, Continuing Education* 4(10).
- Mokhber-Dezfuli, M. R., N. Alidadi, M. Darestani-Farahani, and A. Rezakhani. 2007. The first report of equine atrial fibrillation in Iran. *Journal of Veterinary Research* **62**, 53-55.
- Patteson, M. W. 1996. *Equine cardiology*. 1ed. Wiley Blackwell. USA.
- Reed, S. M. and W. M. Bayly. 1998. *Equine Internal Medicine*. W.B. Saunders Co. Philadelphia.
- Reef, V. B., J. M. Reimer, and P. A. Spencer. 1995. Treatment of atrial fibrillation in horses: New perspectives. *Journal of Veterinary Internal Medicine* **9**, 57-67.
- Stockham, S. L. and M. A. Scott. 2002. *Fundamentals of Veterinary Clinical Pathology*. 1 ed. Iowa State Press.

## یک مورد فیبریلاسیون دهلیزی اسب: سیمای درمانگاهی و الکتروکاردیوگرافی

علیرضا تقوی رضوی زاده<sup>۱</sup>، محمد رضا اصلانی<sup>۲</sup>

<sup>۱</sup> گروه علوم درمانگاهی، دانشکده دامپزشکی، دانشگاه فردوسی مشهد، مشهد، ایران

<sup>۲</sup> گروه علوم درمانگاهی، دانشکده دامپزشکی شهرکرد، شهرکرد، ایران

پذیرش نهایی: ۱۳۹۱/۰۹/۰۹

دریافت مقاله: ۱۳۹۰/۰۳/۱۶

### چکیده

در یک راس مادبان ۱۴ ساله نگهداری شده در بیمارستان آموزشی دانشکده دامپزشکی مشهد، به طور تصادفی فیبریلاسیون دهلیزی تشخیص داده شد. بی نظمی در ضربان و شدت صداهای قلبی در معاینه درمانگاهی و امواج f در الکتروکاردیوگرام اخذ شده مشاهده شد. هماتولوژی طبیعی بود و اندازه گیری برخی فاکتورهای بیوشیمیایی قبل و بعد از درمان، وجود هیپوناترمی را قبل از درمان نشان داد. اسب فوق به وسیله قرص های کوئینیدین سولفات ۲۰۰ میلی گرمی و توسط لوله معدی به طور خوراکی مورد درمان قرار گرفت. در طی ۲۴ ساعت ریتم طبیعی در اسب ظاهر گردید. در مقاله حاضر به عوامل سبب ساز و انواع داروهای استفاده شده برای درمان این دیس ریتمی نیز پرداخته شده است.

**واژگان کلیدی:** فیبریلاسیون دهلیزی، کوئینیدین سولفات، الکتروکاردیوگرام، فاکتورهای بیوشیمیایی، اسب