



Long-term outcome after surgical treatment of a congenital flexor tendon deformity in a pony

Ülke G. Çalışkan^a, Göksen Çeçen Ayalp^b, Hakan Salcı^b, Nureddin Çelimli^c

^a Veterinary Department, Ihsangazi Vocational School, Kastamonu University, 37250, Kastamonu, Turkey.

^b Faculty of Vet Med, Department of Surgery, Bursa Uludag University, Bursa, Turkey.

^c Akademi Veterinary Clinics Nilüfer 16110 Bursa, Turkey.

ABSTRACT

Equine congenital or acquired flexor tendon deformity can occur immediately after birth or at any stage in the first 24 months of life. The long term prognosis after treating a severe flexor tendon deformity in horses may be poor. Although unfavorable prognosis of flexion deformities is a concept, but results of this presented case reveals that performing an appropriate treatment without any complications, will result in a functional improvement even in older patients, such as in this very case. The aim of this report is to present the long-term outcomes after the surgical treatment and postoperative supports of a congenital flexor tendon deformity in a pony.

Keywords

Limb Deformities, Congenital, Tenotomy, Pony

Abbreviations

DIPJ: distal interphalangeal joint
AL-DDFT: Accessor ligament of the deep digital flexor tendon (inferior check ligament)
DDFT: deep digital flexor tendon
iv: intravenously

Number of Figures: 2
Number of Tables: 0
Number of References: 13

Introduction

Flexural limb deformities are common orthopedic problems in horses [1-3]. They can occur immediately after birth or in the first 24 months of life [1] and identified as congenital or acquired [1-10], or unclear [3]. No single treatment regime is always successful for the flexural deformity [3,4,7,8,11]. The prognosis is unfavorable in younger foals with severe deformities of the distal interphalangeal joint (DIPJ) that result in weight-bearing on the dorsal surface of the hoof wall [4]. In the presented case, it was aimed to emphasize that the prognosis can be changed positively with an appropriate treatment protocol despite advanced age and severity of the deformity.

Case presentation

A 2 years old, 120 kg male pony was brought to the Large Animal Clinic of the Surgery Department, Faculty of Veterinary Medicine, Uludag University with a congenital postural defect of the right front limb. According to history, the former owner of the pony said this anomaly came from birth. And the current owner bought the pony with this deformity one year ago. A splinting bandage was previously applied to the affected limb by a private veterinarian when the current owner bought it, but there wasn't any improvement.

A tendon deformity that had caused a Grade II hyperflexion of the right DIPJ (Figure 1a-d) was observed with an irregular shaped elongation on the sole (Figure 1e). The right hoof sole did not touch the ground during stepping and the dorsal hoof ground angle was $>115^\circ$. There was a hyperextension on the left hoof with an irregular shaped elongation on the sole (Figure 1a-c). The general health status and he-

matological analyses of the pony were normal. In the radiological examination, the right third phalanx toe was in the vertical position and the right DIPJ was hyperflexed. No osteophyte proliferation was determined in any of the phalanges (Figure 1f).

A desmotomy on the right inferior-check-ligament (AL-DDFT) was performed using a standard technique [5] under dissociative anesthesia. Preanesthesia was carried out with xylazine HCl (Alfazyne® 2%; Ege Vet, Turkey), 0.5 mg/kg, intravenously (iv). Anesthesia was induced with ketamine HCl (Alfamine® 10%, Ege Vet, Turkey) 2.2 mg/kg, IV, and midazolam (Dormicum® 15 mg/3 ml, Deva, Turkey) 0.1 mg/kg, IV. Anesthesia was maintained with a combination of low dose ketamine HCl with midazolam. Penicillin (Clemipen-Strep®; Topkim, Turkey), 22 000 UI/kg body weight and flunixin meglumine (Finadyne®, Sanofi DIF, Turkey) 1.1 mg/kg were administered iv before surgery. The pony was positioned in lateral recumbency with the affected limb down. The right metacarpal area was prepared for aseptic surgery. A longitudinal skin incision (4-6 cm long) was made at the point where the inferior check ligament becomes hidden by metacarpal IV. The subcutaneous tissues were incised parallel to the skin incision. A curved hemostatic forceps was used to separate the DDFT and the AL-DDFT. The AL-DDFT was transected with a surgical blade. The foot was extended to see the gap between the cut ends of the AL-DDFT (Figure 2a, b). The subcutaneous tissues were closed with a simple continuous pattern and skin was closed with simply separated sutures using 2-0 absorbable sutures in separate layers. Then, trimming on the hooves of the front feet (Figure 2c) and a bandage was applied on the right pastern. The hyperextension on the left DIPJ was resolved after trimming.

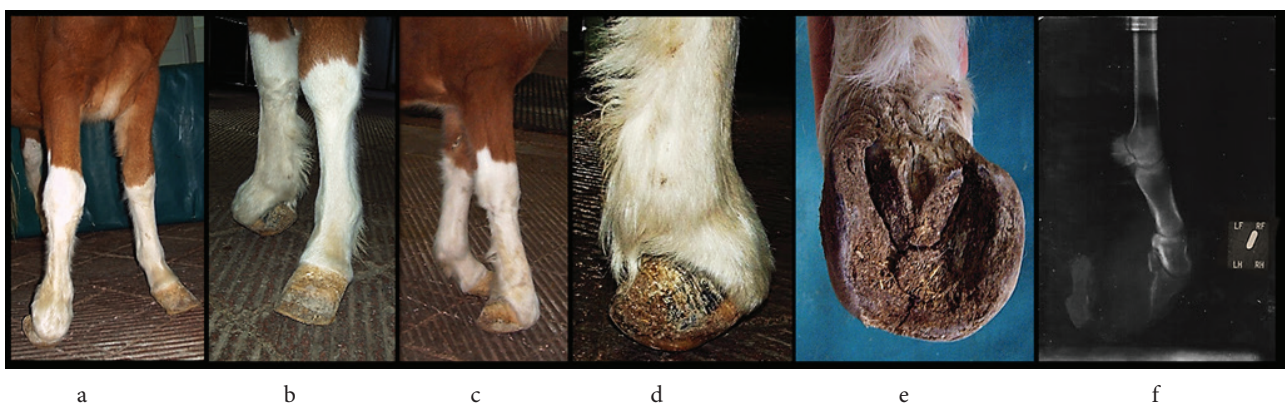


Figure 1. The photos of the case which had a grade II hyperflexion of the right DIPJ.

a-d) A hyperflexion in the distal interphalangeal joint (DIPJ) on the right distal front limb and a hyperextension on the left distal front limb. e) An irregular shaped elongation on the right hoof sole. f) The right DIPJ hyperflexion and no osteophyte proliferation were seen on the preoperative radiograph.

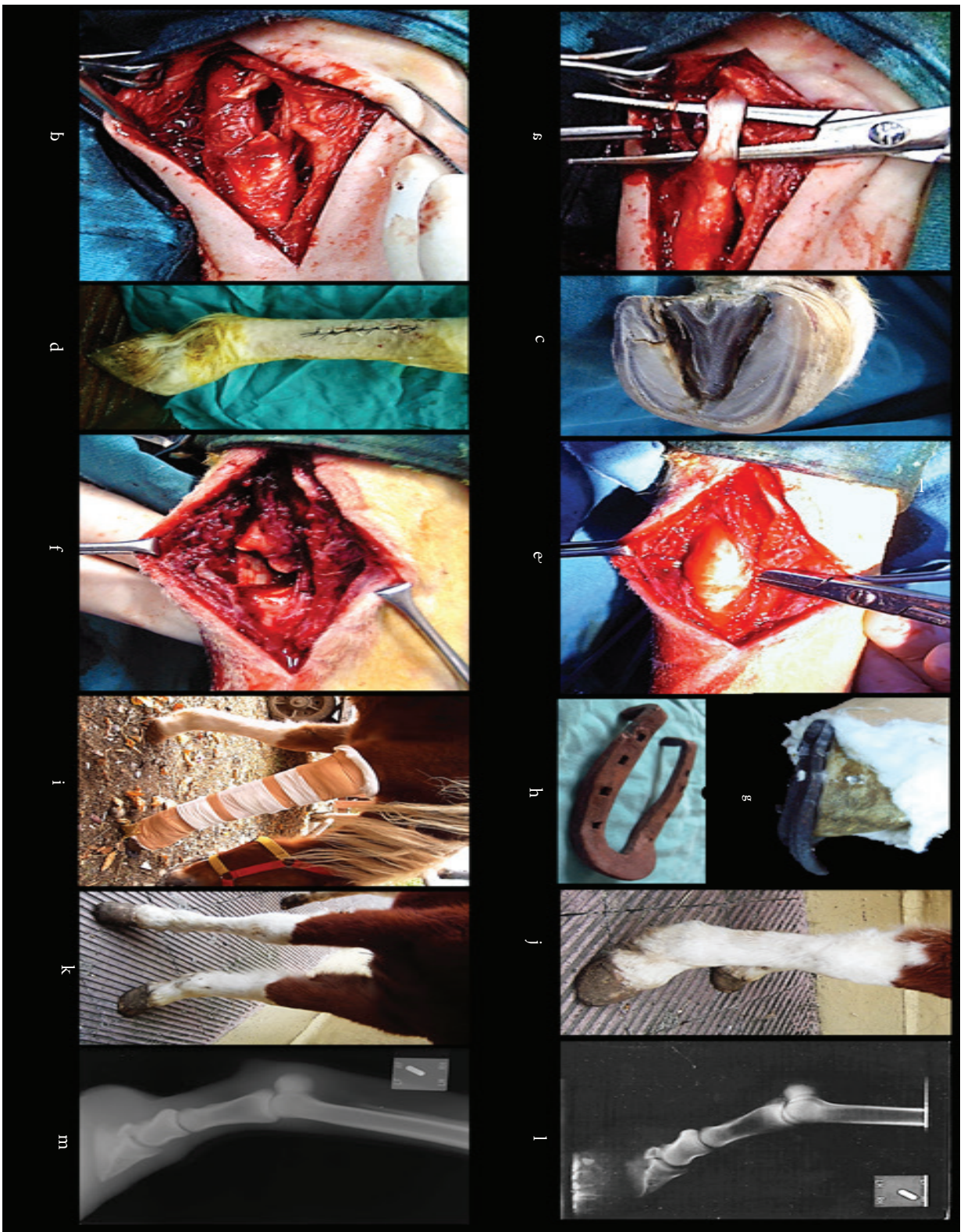


Figure 2. The intraoperative and postoperative photos of the case which had a grade II hyperflexion of the right DIPJ. a & b. Desmotomy of the right AL-DDFT. c) The right front sole after trimming. d) No recovery was observed on the flexion severity one week after desmotomy. e & f). Tenotomy of the right DDFT. g) An orthopedic-shoe with a toe extension. h) A splinted bandage on the right front leg. i-j) Clinically and radiologically functional improvement on the right front-limb at day 49. m) Radiological follow-up examination seven years after the tenotomy.

Results & Discussion

After one week, no improvement was observed relating to the flexion severity (Figure 2d). A tenotomy on the deep digital flexor tendon (DDFT) was performed using a standard technique [5] under the same anesthesia and medication protocol. The pony was positioned in lateral recumbency with the affected limb down. The right metacarpal area was prepared for aseptic surgery. A skin incision (10 cm long) was made on the lateral side of the mid metacarpal region. The digital synovial sheath was opened. The DDF tendon was elevated and incised transversely (Figure 2e-f). Then the ability to extend the foot was controlled. The subcutaneous tissues and skin was closed with suitable suture patterns using 2-0 absorbable sutures in separate layers.

Then, an orthopedic-shoe with a toe extension was applied (Figure 2g) with a splinted bandage on the posterior side of the right front leg (Figure 2i). Resting of the animal was recommended to the owner. Seven days after tenotomy, the stance hyperflexion on the right DIPJ had remarkably disappeared, although tendon callus on the DDFT tenotomy region had not been seen ultrasonographically. The orthopedic-shoe on the right hoof was changed with another horseshoe which has 1.5 cm spurs (Figure 2h). Resting was advised to the owner for another three weeks. At the end of the 3 weeks, the right-foot was observed in the normal situation during both standing and walking. Forty-nine days after DDFT tenotomy and application of the orthopedic shoe, functional recovery was observed on the right front limb (Figure 2j,k,l). The owner was advised to increase the speed and time of walking, gradually and to avoid hard exercises, during the next 5 months. Seven years after the tenotomy, no recurrence of flexor tendon deformity was observed based on clinical and radiological follow-up examinations (Figure 2m). The pony has been living a healthy life as a riding horse.

Flexural deformities seen in horses occur more frequently in the forelimbs [6-9, 12], one side more severely affected [7,9,12]. Its etiology is obscure, although the in-utero fetal position may be involved for congenital deformities [7]. Genetic factors [6, 10], nutrition (excessive carbohydrates 'energy' and unbalanced minerals) [6, 10, 12], and excessive exercise [10] thought to play roles as the causes of acquired flexural deformities. In the presented case (2 years old), the etiology was thought should be related to the intra-uterine fetal position, because the right forefoot had a severe hyperflexion from birth due to history. Carlier et al. (2016) have reported the success rate as 56% for the surgical correction of the abnormal hoof conformation [2]. Jansson and SØnnichsen (1995) empha-

sized that the normal function and appearance of the hoof and toe can be achieved by surgery and reported a higher success rate for a desmotomy as 90% (26/29) [8]. A desmotomy was reported as successful for Grade I cases with a hoof ground angle between 90°-115°, but a DDFT tenotomy was advised for Grade II cases (>115°) [2,4,6]. Potential complications such as incision swelling dehiscence, postoperative scarring, an infection with serious complications like carpal tenosynovitis or desmitis could be seen after surgery [13]. In this case, no adhesion or other complications were observed during the recovery period. Corrective shoes with a toe extension [2,8,13] should be used for 2-3 months after surgery [13]. If the heels could be elevated, it can reduce tension in the DDFT [8, 11] and relieve the pain. In this case, the horseshoe applications made the pony move more comfortably. Exercise is important [2,6,7] but controlled exercise should be done to prevent over-tension in the tendon in the treatment process [6]. Controlled exercise can elongate palmar soft tissues while protecting limbs from overuse [4]. In this case, the owner advised to increase the speed and time of walking, gradually and to avoid hard exercises, during the next 5 months, since the pony was not a racehorse. The prognosis varies according to the chronicity and severity of the deformity [4]. A better prognosis can be achieved in younger patients than six-months-old [2] and also in patients younger than 24 months old [2, 13]. In this case, the age of the pony and the severity of the flexion deformity may have been obstacles to improvement at the desired level after desmotomy. Recurrence of the deformity can be seen in operated cases [1]. The presented case, although was 2 years old and suffering from a severe DIPJ deformity, treated successfully without any recurrence. Nevertheless, it was thought, the treatment success was increased because there was no osteophyte on the foot.

In conclusion, clinical outcomes of this case presentation reveal that appropriate treatment protocols, concurrent with thorough post-operation care, lead to a better prognosis, and provide functional improvement without any complication, even in older patients.

Acknowledgments

This case report was presented as a poster at The 14th National Veterinary Surgery Congress in 2014 in Antalya, Turkey.

Authors' Contributions

Performed clinical evaluations and the anesthesia of the case, and wrote the manuscript: ÜGÇ and GÇA; Performed the surgeries and control examinations of the case: GÇA; Performed the surgeries of the case: HS; Analyzed the radiographic and ultrasonographic evaluations of the case: NÇ.

Conflict of Interests

The authors declare that they have no competing interests.

References

- Greet TR. Managing flexural and angular limb deformities: The new market perspective. In: Proceedings of the 46th Annual Convention of the American Association of Equine Practitioners; 2000 November 26-29; San Antonio, Texas, USA, c2000, p. 130-6.
- Carlier S, Oosterlinck M, Martens A, Pille F. Treatment of acquired flexural deformity of the distal interphalangeal joint in the horse: a retrospective study of 51 cases. *Vlaams Diergeneeskd Tijdschr.* 2016;85(1):9-14.
- Greet T. Angular and flexural limb deformities in foals and yearlings. Part 2: Flexural limb deformities. *Vet. Nurs. J.* 2016;31(7):210-2.
- Adams SB, Santschi EM. Management of congenital and acquired flexural limb deformities. In: Proceedings of the 46th Annual Convention of the American Association of Equine Practitioners; 2000 November 26-29; San Antonio, Texas, USA, c2000, p. 117-125
- Auer JA. Diagnosis and treatment of flexural deformities in foals. *Clin Tech Equine Pract.* 2006;5(4):282-95.
- Avisar Y. Corrective trimming and shoeing in contracted tendons of foals. *ANVIL Magazine* [Internet]. 1997 [cited 2019 June 20]; Available from: <http://www.anvilmag.com/farrier/yehuda2.htm>
- Greet TR. The management of flexural limb deformities in the foal and yearling. In: Chopin J, editor. Australian College of Veterinary Scientist Annual Conference Equine Chapter Conference Program and Proceedings; 2008 July 3-5, Gold Coast (Australia), c2008. p. 28-38.
- Jansson N, Sønnichsen HV. Acquired flexural deformity of the distalinterphalangeal joint in horses: Treatment by desmotomy of the accessory ligament of the deep digital flexor tendon: A retrospective study. *J Equine Vet Sci.* 1995;15(8):353-6.
- Kidd JA, Barr ARS. Flexural deformities in foals. *Equine Vet. Educ.* 2002;14(6):311-21.
- O'Grady SE. Flexural deformities of the distal interphalangeal joint (clubfeet). *Equine Vet. Educ.* 2012;24(5):260-8.
- O'Grady SE. How to manage the club foot-birth to maturity. In: Proceedings of American Association of Equine Practitioners (AAEP) Annual Convention, Equine chapter Lameness examination and therapy. 2014 Dec 10, Salt Lake City, UT, USA, c2014. p. 60-72.
- Lloyd-Bauer PM, Fretz PB. Correction of acquired flexural deformity by deep digital flexor tenotomy in a miniature horse. *Can. Vet. J.* 1989;30(7):585.
- Tnibar A. Desmotomy of the accessory ligament of the deep digital flexor tendon in horses: an update. *J Equine Vet Sci.* 2010;30(12):715-9.

COPYRIGHTS

©2021 The author(s). This is an open access article distributed under the terms of the Creative Commons Attribution (CC BY 4.0), which permits unrestricted use, distribution, and reproduction in any medium, as long as the original authors and source are cited. No permission is required from the authors or the publishers.



How to cite this article

Çalışkan UG, Çeçen Ayalp G, Salcı H, Çelimli N (2020). Long-term outcome after surgical treatment of a congenital flexor tendon deformity in a pony. *Iran J Vet Sci Technol.* 12(2):83-87.
DOI: <https://doi.org/10.22067/veterinary.v12i2.87593>.
URL: https://ijvst.um.ac.ir/article_31032.html