

Comparative pathomorphological study of rickets types in broiler chickens

Ivan Dinev*

*Department of General and Clinical Pathology, Faculty of Veterinary Medicine,
Trakia University, 6000 Stara Zagora, Bulgaria*

Received: January 25, 2011

Accepted: June 20, 2011

Abstract

The purpose of this study was to determine the incidence of rickets types in broiler chickens on the basis of gross and microscopic lesions in field clinical cases with regard to differential pathomorphological diagnosis.

Clinical, serological, gross anatomy and histological investigations were carried out in broiler chickens with signs of rickets. The survey included 12 finisher broiler flocks (ten Ross 308 and two Cobb 500 flocks) from 4 different farms.

Gross lesions in chickens from two of farms were indicative of hypophosphataemic rickets and the other two- of hypocalcaemic rickets types. Microscopic lesions correlated to macroscopic ones.

The results of investigations showed that lesions resulting from calcium deficiency were very different from those occurring after phosphorus deficiency or calcium excess. It was suggested that macroscopic lesions in the proximal tibiotarsus could be used to distinguish field cases of Ca-deficiency and P-deficiency rickets in broiler chickens. The lesions in other leg parts (femur and tarsometatarsus) were not consistent with regard to differential diagnosis of rickets types due to the insufficient lesions in these bones.

Keywords: broiler chickens, rickets types, gross and microscopic lesions, differential pathomorphological diagnosis.

* corresponding author: Ivan Dinev, ,PhD,DVM
idinev@uni-sz.bg
idinevnz@mail.bg

Introduction

Rickets is a metabolic disturbance in young growing birds characterized with thickening and poor mineralization of bone growth plates. In general, etiology is related to dietary calcium (Ca), phosphorus (P) and vitamin D3 deficiency, impaired Ca/P ratio or impaired absorption of one or both of these macroelements (Riddell, 1992; Thorp, 1992). Erroneous feed mixing could also provoke outbreaks (Riddell, 1992). In both forms (Ca-deficiency and P-deficiency), the proper calcification of cartilage is impaired.

The effect of excessive dietary P level is similar to that of dietary calcium deficiency. In hypocalcaemic rickets, the epiphyseal plate is thickened due to accumulation of proliferating chondrocytes (Jande and Dickson, 1980) accompanied by increased length of perforating epiphyseal blood vessels (Lacey and Huffer, 1982). This finding is specific in most cases of field rickets and low blood plasma calcium are believed to a common cause. In hypophosphataemic rickets, accumulation of hypertrophic chondrocytes is observed (Lacey and Huffer, 1982).

The different alimentary deficiencies result in various histopathological manifestations, described in experimentally induced hypocalcaemic and hypophosphataemic rickets (Long et al., 1984a, b, c). On the basis of pathological lesions, two rickets types have been determined: hypocalcaemic, characterized with accumulation of proliferating chondrocytes (Jande and Dickson, 1980), and hypophosphataemic (P-deficiency) distinguished by accumulation of hypertrophic chondrocytes in the metaphyseal zone (Lacey and Huffer, 1982).

Subclinical rickets is commonly seen in broiler chickens, probably due to dietary calcium deficiency and phosphorus excess (Riddell and Pass, 1987). A study upon endochondral ossification defects in commercial broiler flocks in Australia has shown that 50% of birds in 3 out of 6 flocks had rachitic tibiotarsal lesions at the age of 2

weeks. In the other flocks, the incidence was from 12% to 16%. The lesions were not severe enough to cause lameness (Vaiano et al., 1994). Severe clinical lesions were rarely encountered (Pattison, 1992). The wide distribution of subclinical rickets could sometimes remain unnoticed. Despite the present level of knowledge about poultry diets, rickets is still a problem in broiler production (Riddell, 1992).

The histopathological diagnosis could be complicated in field cases and hypophosphataemic rickets could possibly be mistaken for the hypocalcaemic form (Randall 1991). Thorp (1994) reported that cases of tibial dyschondroplasia (TD) of alimentary origin could be also classified as forms of rickets with different histopathology, as Ca- and P-deficiency rickets. Although the gross pathology of rickets could not be differentiated from dyschondroplasia, there are differences at a cellular level (Thorp et al., 1991).

The purpose of this study was to determine the incidence of rickets types in broiler chickens on the basis of gross and microscopic lesions in field clinical cases with regard to differential pathomorphological diagnosis

Materials and methods

The present survey includes clinical, blood biochemical, gross anatomy and histological examinations in broiler chickens with manifestations of rickets. The studies were performed in 12 broiler flocks in 4 different farms: Farm A with 6 flocks of 18,000 Ross 308 broiler chickens each; farm B with 2 flocks of 15,000 Cobb 500 broilers each; farm C with 3 flocks of 18,000 Ross 308 broilers each and farm D – 1 flock with 10,000 Ross 308 broilers. The farms were located in different regions of the country. In all farms, birds were raised on a straw litter in 24-hour light. The feeding was as per technological requirements of the respective strain.

Gross anatomy studies were performed on necropsied bodies of dead chickens from affected flocks, noting the present macroscopic skeletal lesions.

Samples of the proximal tibias from birds with gross anatomy lesions were obtained for histopathological examinations. Ten tibiotarsal bone samples were collected from each farm. The materials were fixed in 10% neutral formalin for 48–72 h. Then the bones were demineralized in 6% nitric acid for 72 h, processed by routine histological techniques and embedded in paraffin. The cross sections were stained with haematoxylin and eosin (H/E).

Blood serum concentrations of magnesium (Mg), calcium (Ca) and inorganic phosphate (P) were assayed on an automated analyzer in 25 samples obtained from each flock by the time of observing clinical signs and gross lesions typical for rickets.

Results

Initial signs of rickets have been observed at the age of 14 days in farm A, 18 days in farms B and C, and 8 days in farm D. Clinically, rickets was manifested with usual signs – various extent of leg weakness – from unstable gait to complete inability of chickens to stand up, lying down on their bent legs or on their side. Some of affected chickens used their wings for support when moving.

In chickens from farms A, B and C, the period of clinically manifested rickets (days 14–26) was accompanied by insignificantly higher daily mortality – up to 0.16% as compared to the previous rate of 0.05%. In farm D, where rickets outbreak was observed after the age of 7 days and clinical signs ended by the 18th day, the total daily mortality was 1500 (15%) chickens. In about half of necropsied chickens from farm D, rickets-specific gross lesions were observed in the costochondral junctions – the so-called rachitic rosary (Fig 1). In all these cases, death occurred in emaciated chickens that were not able to reach the feed or the water sources, lying down because of leg weakness.

The gross anatomy examination of the skeleton of dead chicken bodies from farms A and B revealed macroscopic lesions typical for

hypocalcaemic rickets. The proximal tibiotarsus exhibited specific alterations. The proliferative zone (PZ) of the growth plate was considerably and irregularly elongated. The upper PZ part was semi-transparent and epiphyseal blood vessels were seen through, whereas the lower part was opaque (Fig. 2). In almost 25% of cases in farm B, the lower part of PZ turned into a wedge-shaped projection. The hypertrophic zone (HZ) was small and poorly vascularized.

Gross lesions observed in chickens from farms C and D were typical for hypophosphataemic rickets. The HZ of the tibiotarsal growth plate was lengthened towards the metaphysis (Fig. 3). The spicules in the upper part (under PZ) were semi-transparent and blood vessels were visualized. The transition from transparent to opaque spicules was usually irregular. Chickens from farm C exhibited such lesions in the distal tibiotarsus and the proximal tarsometatarsus as well (Fig. 4). In some of these cases (\approx 25%) variable amount of fibrous-like tissue was detected in the metaphysis.

Microscopically, the growth plate PZ in chickens from farms A and B was elongated, irregular and poorly vascularized. The cartilage columns were short, wide and with irregular shape, whereas proliferating chondrocytes were disorganized (Fig. 5). In the metaphysis in some chickens, cartilage spicules were surrounded by various amounts of loose connective tissue. Only a small zone of hypertrophic cartilage and reduced calcification was present.

Chickens from farm D demonstrated a marked elongation of cartilage cell columns in the metaphyseal primary spongiosa (Fig. 6). Lengthened cartilage cell columns were projected in a candle-like manner towards the medullary cavity. They were lined by eosinophilic bridges of collagenous substance. In broilers from farm C, the observed alterations were similar. The growth plate HZ was elongated, non-calcified, but normally vascularized from metaphyseal blood vessels.

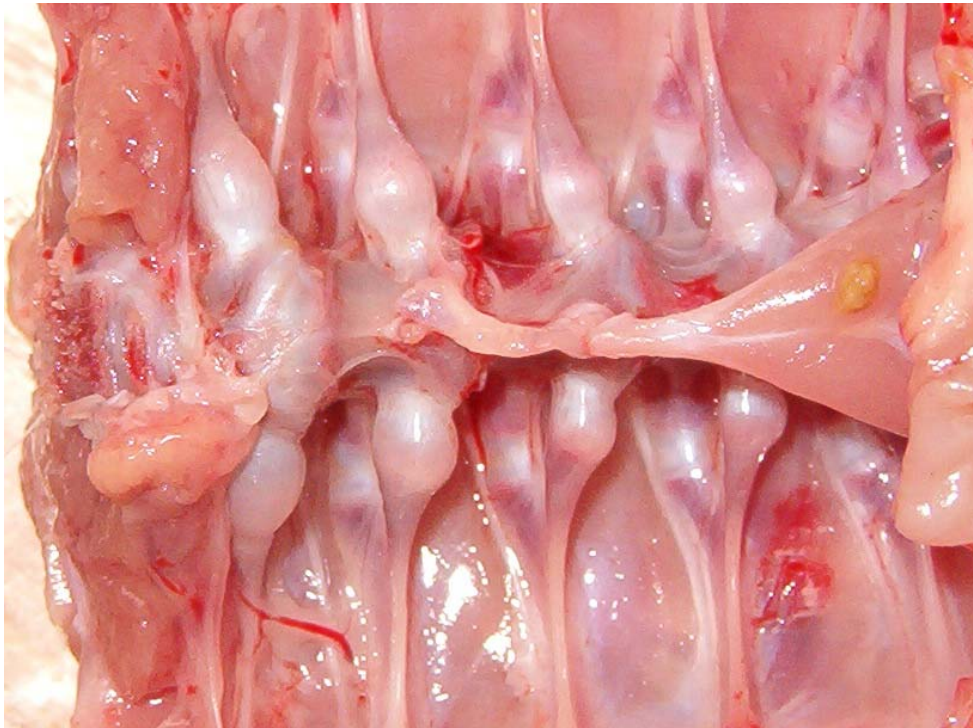


Figure 1. Specific macroscopic lesions in the region of costochondral junctions - rachitic rosary in a 10-day-old chickens from farm D.

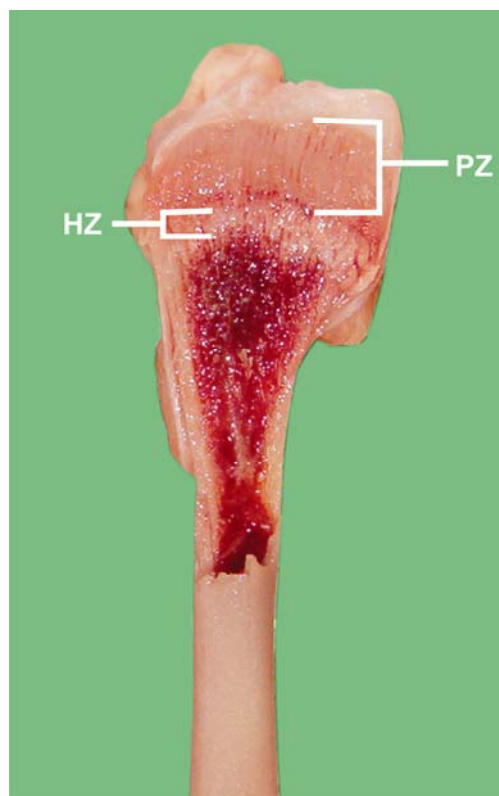


Figure 2. Hypocalcaemic rickets in a 21-day-old chicken from Farm B. A considerably elongated growth plate proliferative zone (PZ) and widening of the proximal tibiotarsus is seen. The hypertrophic zone (HZ) is not altered.

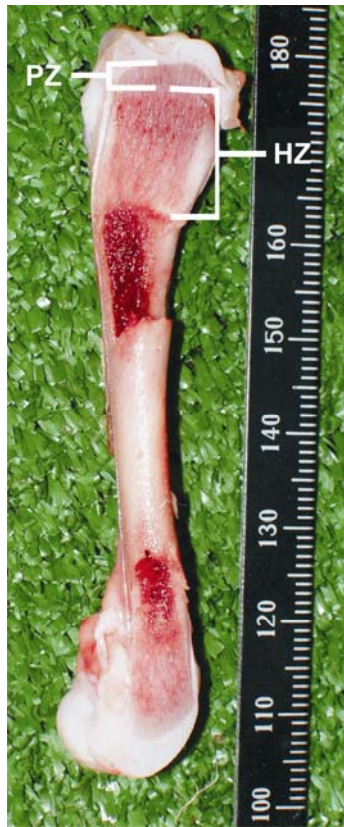

Figure 3. P-deficiency rickets in a 23-day-old chicken from farm C. Considerable extension of growth plate hypertrophic zone (HZ) towards the metaphyse of proximal and distal tibiotalarsus. The proliferative zone (PZ) is not altered.

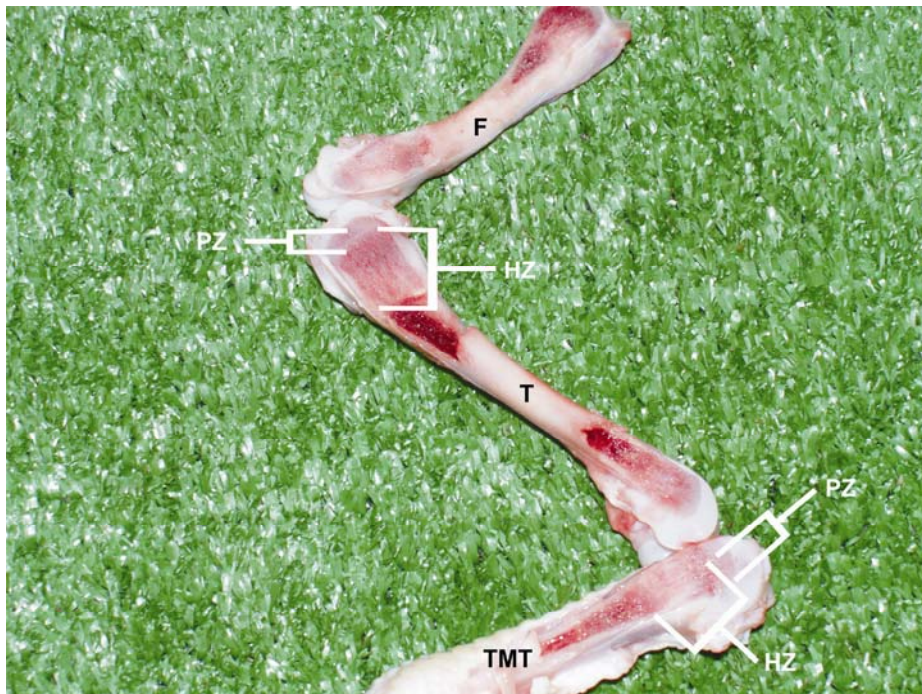


Figure 4. Marked lesions in the proximal tibiotalarsus (T) and less prominent alterations in the distal femur (F) and proximal tarsometatarsus (TMT) in a 23-day-old chicken from farm C with hypophosphataemic rickets.

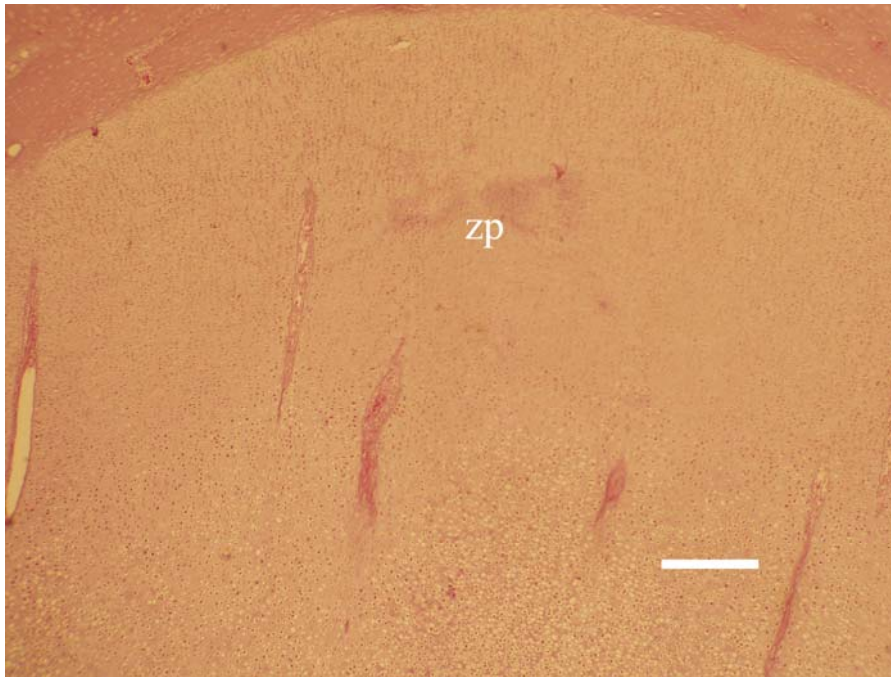


Figure 5. Histopathological lesions in a chicken with Ca-deficiency rickets from farm A. The growth plate proliferative zone (zp) is widened, irregular and poorly vascularized. Only a small zone of cartilage hypertrophy and reduced calcification is seen , H/E, Bar = 40 μ m.

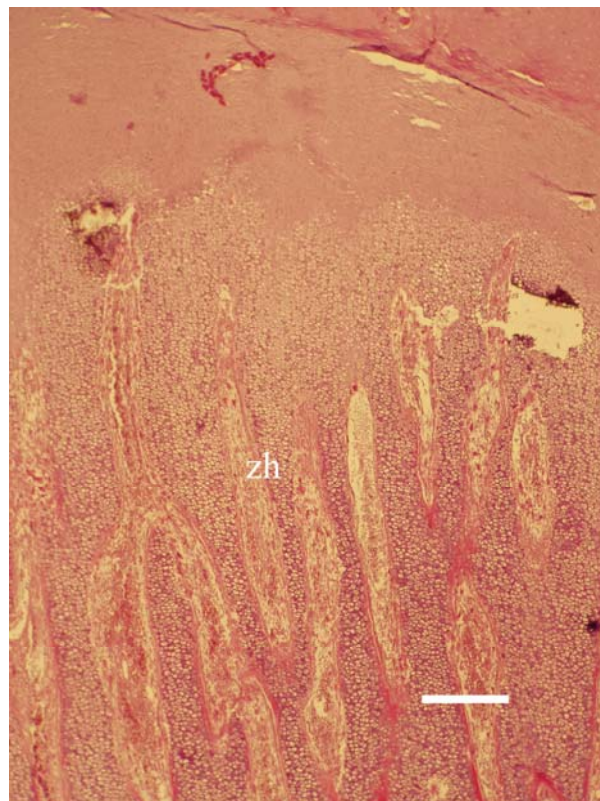


Figure 6. Histopathological lesions in a chicken with hypophosphataemic rickets from farm C. The growth plate hypertrophic zone (zh) is enlarged, non-calcified, but normally vascularized by metaphyseal blood vessels, H/E, Bar = 40 μ m.

The rickets was also confirmed by the analysis of blood serum samples (25 from each flock). The mean values and minimum-maximum values (mmol/L) of studied parameters are presented in **Table 1**. The Ca/P mean arithmetic ratios for studied parameters in the different farms were as followed: farm A – 2.4/1.96 (1.22/1); farm B – 2.32/2.52 (0.92/1); farm C - 3.301/1.326 (2.489/1); farm D – 3.497/1.349 (2.592/1). The mean blood serum concentrations of Mg were 1.00 mmol/L (farm A); 0.935 mmol/L (farm B); 0.983 mmol/L (farm C) and 1.03 mmol/L (farm D).

Table 1. Serum magnesium, calcium and inorganic phosphate concentrations in investigated broiler chicken flocks (n=25).

Magnesium, mmol/L			
Farm	min-max	geometric mean	arithmetic mean
A	0.793-1.784	0.987	1.000
B	0.755-1.653	0.928	0.935
C	0.670-2.110	0.955	0.983
D	0.811-1.834	0.987	1.030
Calcium, mmol/L			
Farm	min-max	geometric mean	arithmetic mean
A	1.690-2.910	2.370	2.400
B	1.400-3.100	2.300	2.320
C	2.874-4.003	3.290	3.301
D	2.094-4.783	3.480	3.497
Inorganic phosphate, mmol/L			
Farm	min-max	geometric mean	arithmetic mean
A	1.347-2.723	1.910	1.960
B	1.100-3.200	2.480	2.520
C	1.000-1.652	1.320	1.326
D	0.158-1.879	1.330	1.349
/ ratio			
Farm	Arithmetic mean coefficient		
A	1.220/1		
B	0.920/1		
C	2.489/1		
D	2.592/1		

Discussion

The field pathomorphological investigations of rickets in broiler chickens have shown the distribution of the two rickets types:

hypocalcaemic and hypophosphataemic, characterized by accumulation of proliferating or hypertrophic chondrocytes in the growth plate, respectively (Jande and Dickson, 1980; Lacey and Huffer, 1982; Long et al., 1984a, b). The blood Ca and P concentrations of broiler chickens from affected flocks also supported the rickets type determined on the basis of macro- and microscopic lesions. The Mg concentrations rejected the hypothesis of rachitis due to dietary magnesium excess and secondary impairment of phosphorus absorption (Lee et al., 1980).

As per our results, the lesions due to Ca deficiency were very different from those due to P deficiency or calcium excess. Thus, we consider that gross proximal tibiotarsal lesions could be used to differentiate hypocalcaemic from hypophosphataemic field cases of rickets in broiler chickens, as shown experimentally by Long et al. (1984a, b, c).

The lesions in the other leg bones (femur and tarsometatarsus) were not reliable to distinguish between both types of rickets as in these parts of the skeleton, the lesions were not enough prominent. This could be attributed to the transient deficiency of minerals or imbalance during the rapid growth stage of long bones, particularly the tibia, as the proximal tibia is considered as a site for fastest growing growth plat (Angel, 2007). Furthermore, the lesions could also vary by extent.

Studies performed by us conformed that Ca-deficiency rickets could be hardly distinguished from tibial dyschondroplasia only on the basis of gross lesions. In such cases, differences at cell level should be considered (Thorp et al., 1991). We agree with authors believing that rickets lesions could play a role in the development of TD (Edwards, 1992; Thorp, 1994). It could be assumed that TD could be secondary to rickets resulting from the reduced chondrocyte hypertrophy, when birds attempt to adapt to low-calcium diet (Long et al., 1984b). This statement is supported by experimental data that high-phosphorus ration had caused rickets

in 2-week-old chickens, and later, at the age of 4 weeks – TD (Long et al., 1984b; Riddell and Pass, 1987), and by data from a field investigation of high prevalence of rickets in 2-week-old broiler chickens that led to TD at the age of 3-4 weeks (Parkinson et al., 1992). It should be noted that this opinion is not entirely shared. Riddell (1992) classifies TD and rickets as completely different metabolic disorders.

In conclusion, macroscopic lesions of the proximal tibiotarsus could be used to differentiate Ca-deficiency from P-deficiency rickets in field cases among broiler chickens. Only on the basis of gross lesions, hypocalcaemic rickets could be hardly differentiated from tibial dyschondroplasia, as from etiological point of view, the latter condition could be secondary to the former one (Edwards, 1992; Thorp, 1994).

References

- Angel, R. (2007) Metabolic disorders: limitations to growth of and mineral deposition into the broiler skeleton after the hatch and potential implications for leg problems. *The Journal of Applied Poultry Research* 16, 138-149
- Edwards, H.M. (1992) Nutritional factors and leg disorders, In: Whitehead CC, Editor, *Bone biology and skeletal disorders in poultry*, Carfax publishing company, Abingdon, 167-193.
- Jande, S.S. and Dickson, I.R. (1980) Comparative histological study of the effects of high calcium diet and vitamin D supplements on epiphyseal plates of vitamin-D-deficient chicks. *Acta Anatomica* 108, 463-468.
- Lacey, D.L. and Huffer, W.E. (1982) Studies on the pathogenesis of avian rickets . I. Changes in epiphyseal and metaphyseal vessels in hypocalcaemic and hypophosphatemic rickets. *American Journal of Pathology* 109, 288-301.
- Lee, S.R., Britton, W.M. and Rowland, G.N. (1980) Magnesium toxicity: bone lesions, *Poultry Science* 59, 2403-2411.
- Long, P.H., Lee, S.R., Rowland, G.N. and Britton, W.M. (1984a) Experimental rickets in broilers: Gross, microscopic and radiographic lesions. I. Phosphorus Deficiency and calcium excess. *Avian Diseases* 2, 460-474.
- Long, P.H., Lee, S.R., Rowland, G.N. and Britton, W.M. (1984b), Experimental rickets in broilers: Gross, microscopic and radiographic lesions. II. Calcium Deficiency. *Avian Diseases* 4, 921-932.
- Long, P.H., Lee, S.R., Rowland, G.N. and Britton, W.M. (1984c) Experimental rickets in broilers: Gross, microscopic and radiographic lesions. III. Vitamin D Deficiency. *Avian Diseases* 4, 933-943.
- Parkinson, G.B., Vaiano, S.A. and Aзуolas, J.K. (1992) Rickets and tibial dyschondroplasia in Australian broiler chickens, In: *Australian poultry science symposium*, University of Sydney, Sydney, New South Wales, 125-130
- Pattison, M. (1992) Impacts of bone problems on the poultry meat industry, In: Whitehead CC. Editor, *Bone biology and skeletal disorders in poultry*, Carfax publishing company, Abingdon, 329-338.
- Randall, C.J. (1991) A colour atlas of diseases & disorders of the domestic fowl & turkey, 2nd edn., London (Wolfe Publishing, ltd), 114-116
- Riddell, C. (1992) Non infectious skeleton disorders of poultry – an overview, In: Whitehead, CC, Editor, *Bone biology and skeletal disorders in poultry*, Carfax publishing company, Abingdon, 119-145.
- Riddell, C. and Pass, D.A. (1987) The influence of dietary calcium and phosphorus on tibial dyschondroplasia in broiler chickens. *Avian Diseases* 31, 771-775.
- Thorp, B. (1992) Abnormalities in the growth of leg bones, In: Whitehead, CC Editor, *Bone biology and skeletal disorders in poultry*, Carfax publishing

company, Abingdon, 147-166.

Thorp, B. (1994) Skeletal disorders in the fowl: a review. *Avian Pathology* 23, 203-236.

Thorp, B.H., Whitehead, C.C. and Rennie, J.S. (1991) Avian tibial dyschondroplasia: a comparison of the incidence and severity as assessed by gross examination and histopathology. *Research in veterinary*

science 51, 48-54

Vaiano, S.A., Azuolas, J.K., Parkinson, J.B. and Scott, P.C. (1994) Serum total calcium, phosphorus, 1,25-dihydroxycholecalciferol, and endochondral ossification defects in commercial broiler chickens. *Poultry Science* 73, 1296-1305.

مقایسه پاتومورفولوژیک انواع ریکتز در جوجه های گوشتی

ایوان دینف *

گروه پاتولوژی عمومی و بالینی، دانشکده دامپزشکی دانشگاه تراکیا، ۶۰۰۰ استارازاگورا، بلغارستان

پذیرش نهایی: ۹۰/۳/۳۰

دریافت مقاله: ۸۹/۱۱/۵

چکیده

هدف از مطالعه حاضر بررسی وقوع انواع ریکتز بر اساس ضایعات ماکروسکوپی و میکروسکوپی در نمونه های بالینی بیماری در جوجه های گوشتی و تشخیص تفریقی پاتومورفولوژیک آن است. بررسی های بالینی، سرولوژیک، ماکروسکوپی و هیستولوژیک در جوجه های گوشتی با علایم ریکتز انجام گرفت. مطالعه شامل ۱۲ گله گوشتی (۱۰ گله از نژاد Roos 308 و ۲ گله از Cobb 500) از ۴ مزرعه مختلف بود. ضایعات ظاهری و نیز میکروسکوپی نمایانگر وجود ریکتز ناشی از کمبود فسفر در دو مزرعه و ریکتز ناشی از کمبود کلسیم در دو مزرعه دیگر بود. نتایج بررسی نشان داد که ضایعات ناشی از کمبود کلسیم با ضایعات ناشی از کمبود فسفر یا زیاد بود کلسیم تفاوت بسیاری دارند. پیشنهاد میگردد که ضایعات ماکروسکوپی در ناحیه پروکسیمال تیپوتارس می تواند به منظور تشخیص موارد ریکتز ناشی از کمبود کلسیم و کمبود فسفر در جوجه های گوشتی به کار رود. ضایعات در سایر قسمت های پا (فمور و تارسومتاتارس) در جهت تشخیص تفریقی انواع ریکتز به دلیل عدم وجود ضایعات کافی در آن استخوان ها کمک کننده نبود.

واژگان کلیدی: جوجه گوشتی، انواع ریکتز، ضایعات ظاهری و میکروسکوپی، تشخیص تفریقی پاتومورفولوژیک