

# Necrotic ulcerative dermatitis due to simultaneous infections of *Malassezia* and *Microsporium gallinae* in a pigeon (*Columba livia domestica*)

Samaneh Eidi, Hossein Nourani, Abolghassem Naghibi

Department of Pathobiology, Faculty of Veterinary Medicine, Ferdowsi University of Mashhad, Mashhad, Iran

## Keywords

*Malassezia*, *Microsporium gallinae*, pigeon, skin lesions, pathology

## Abstract

A homing pigeon (*Columba livia domestica*) was referred to the mycology laboratory of the Faculty of Veterinary Medicine, Ferdowsi University of Mashhad, Iran with the presence of ulceration, bleeding, loss of feathers and scabs and crust in the head region. Mycological evaluation was shown simultaneous infections by *Malassezia* and *Microsporium gallinae*. Pathological findings revealed severe and deep necrotic skin lesions associated with fungal hyphae and especially numerous yeasts. It was concluded that keratinophilic fungi, especially dermatophytes in skin and feathers of birds can cause severe lesions and be a potential source of spread of disease in the human population and animals. It also suggests considering the

role of *Malassezia* spp. as a risk factor in the development of skin lesions and the emergence and exacerbation of infections such as dermatophytes.

## Abbreviations

sp. and spp.: Species

*M. gallinae*: *Microsporium gallinae*

KOH/DMSO: Potassium Hydroxide/Dimethyl sulfoxide

µm: micrometer

## Introduction

Skin and feather problems are common disorders in avian species (Schmidt and Lightfoot, 2005). Bird's skin and feather lesions and their inflammation due to various fungi such as *Candida* sp., *Aspergillus* sp., *Malassezia* sp., *Geotrichum candidum*, *Microsporium gallinae*, *Rhodotorula* sp., *Penicillium cyclopium* and various other species have been described (Dahlhausen, 2005; Shivaprasad, 2008).

Decomposing skin and feathers of birds are known as carrier of microorganisms, especially pathogenic fungi which are capable to infect humans and animals (Miljkovic et al., 2011). Skin and feathers are a rich source of keratin and are regarded as one of the reservoirs of keratin-degrading microorganisms. Some of these keratinophilic fungi are species of dermatophytes known to cause cutaneous infections of keratinized tissues, viz skin, feather, hair and nail (dermatophytoses) of humans and animals (Gungnani et al., 2012).

*Microsporium gallinae* (*M. gallinae*) is a dermatophyte that causes favus of the comb in chickens and related species (Murata et al., 2013). This fungal species also infects dogs (Baudet, 1943; Georg et al., 1962; Dvorak and Otčenasek, 1964; Komarek and Wurst, 1989), monkeys (Gordon and Little, 1968), cats (Dvorak and Otčenasek, 1964; Korting and Zienicke, 1990), squirrels (Georg et al., 1962), mice, canary, pigeon, and turkey (Chermette et al., 2008), and has been isolated from birds' nests (Goodenough and Stallwood, 2010).

White crusts or plaques containing fungal elements are associated with hyperkeratosis, and lesions may spread to the skin of the head and the neck with feather loss, although the feathers are not invaded. Based on 44 reports, it would appear that the endemic areas of *M. gallinae* include European, Middle Eastern, and South American countries, in addition to the USA (Takahashi et al., 2003), Sweden, France, Germany, Czechoslovakia, Spain, Germany, Paki-

stan, Iran, Nigeria, Puerto Rico, Venezuela, and Japan (Miyasato et al., 2011).

Recent research indicates that *Malassezia* spp. and other fungi may play a role in some cases of dermatitis or feather picking. *Malassezia* spp. is occasionally found as an etiologic agent, generally documented on cytology or histopathology, for feather loss and dermatitis (Schmidt and Lightfoot, 2005).

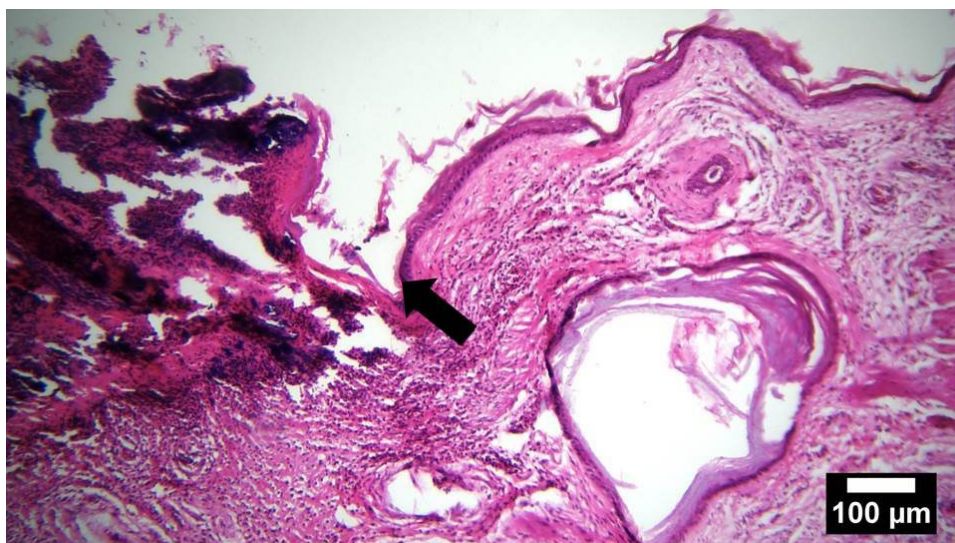
To the best of our knowledge, there is no report on severe and deep necrotic skin lesions due to simultaneous infections by *Malassezia* and *M. gallinae* in homing pigeon in the world and in this manuscript, mycological, gross and histopathological aspects of the case are reported from Mashhad, Iran.

## Case presentation

A homing pigeon (*Columba livia domestica*) was referred to the mycology laboratory of the Faculty of Veterinary Medicine, Ferdowsi University of Mashhad, Iran. The clinical signs included the presence of ulceration, bleeding, loss of feathers and scabs and crust in the head.

Sample collection from the skin lesions were done by a sterile scalpel. Direct microscopic examination was carried out on the samples mounted in 20% KOH/DMSO (Merck Co., Darmstadt, Germany). Also, the samples were cultured on Mycosel agar (Merck Co., Darmstadt, Germany) and modified Dixon agar containing 0.05% chloramphenicol (Merck, Darmstadt, Germany) and 0.05% cycloheximide (Sigma, St Louis, MO, USA). Plates were then incubated aerobically at both 25°C and 31°C for 2-4 weeks and were monitored daily.

For histopathological examinations, samples of the head lesions were taken and fixed in 10 per cent buffered formalin and processed according to the standard histological techniques for paraffin embedding. Tissue sections 5 µm thick were prepared and used for conventional hae-



**Figure 1**

The border (arrow) between the skin ulcer (left) and normal cutaneous structures (right)

matoxylin–eosin and special Periodic Acid Schiff (PAS) staining methods.

## Results and Discussion

Hyaline septate branching mycelium and arthroconidia were observed during direct examination of skin samples. Colonies grown on Mycosel agar were flat with a suede-like texture and white in color with strawberry-colored pigmentation diffusing into the medium. Subsequently, the colonies were examined under the light microscope after staining with lactophenol cotton blue. Septate hyphae with small numbers of macroconidia consisting of 4–6 cells ( $4-7 \times 12-18 \mu\text{m}$ ) and ovoid to pyriform, single-celled microconidia ( $1-2 \mu\text{m}$  in diameter) attached to the hyphae at right angles were observed. Macroscopy and Microscopy results from culture revealed the presence of *Microsporium gallinae* (*M. gallinae*).

Microscopic examination from colonies grown on modified Dixon agar determined numerous spherical or oval-shaped yeasts with unipolar budding and a distinct collarette, typical of *Malassezia* sp.

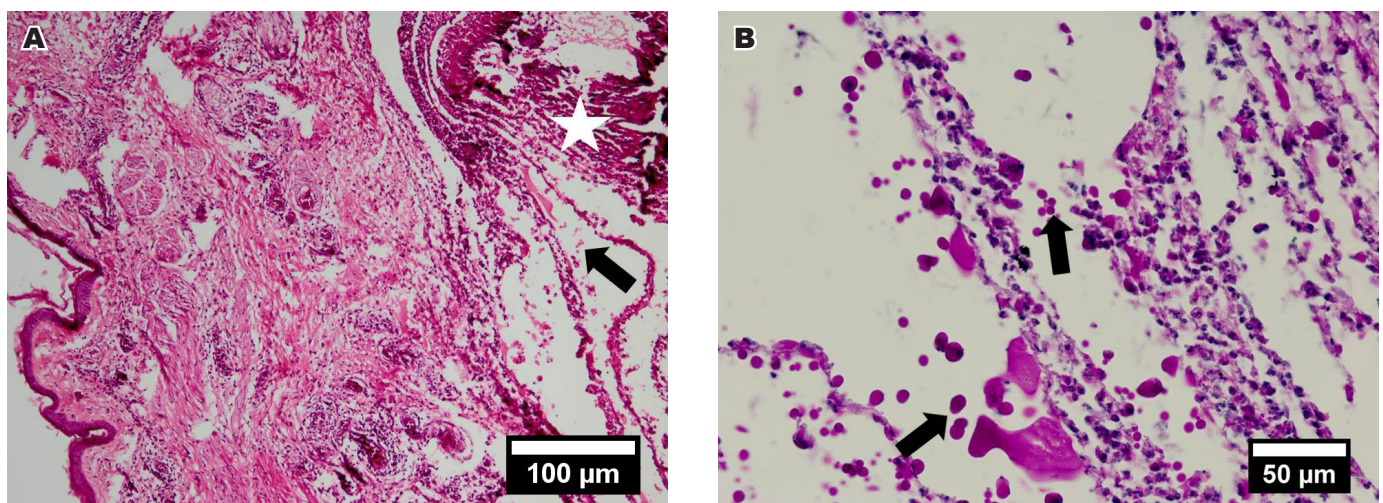
Histopathological examinations of the head skin lesions revealed ulcer and crust formation, hemorrhages, hyperemia and superficial epidermal necrosis and tissue debris (Figure 1). Diffuse necrotic dermal lesions were observed beneath the skin ulcer. Some sequestered necrotic areas were seen in subcutaneous that were surrounded by infiltrations of mixed inflammatory cells, including macrophages, lymphocytes and plasma cells. Fungal hyphae and especially numerous yeasts were found in the central parts of these subcutaneous necrotic areas (Figure 2A). In PAS stained sections, the fungal structures were purple in color and seen in the superficial keratin layer adjacent to the ulcers and also were associated with the central parts of subcutaneous lesions (Figures 2B and 3).

Cutaneous lesions in birds may be due to nutritional

deficiencies, external parasites, microbial agents, and etc. Fungal dermatitis is rarely reported in birds. Infections of the integument caused by *Candida albicans*, *Rhodotorula*, *M. gallinae*, *Aspergillus*, *Rhizopus*, *Malassezia* and *Mucor* species have been described (Dahlhausen, 2005; Shivaprasad, 2008). Skin and feather lesions associated with *Aspergillus* have been recognized in pigeons and psittacine birds (Tudor, 1983); but to our knowledge, there is no report on severe and deep necrotic skin lesions due to simultaneous infections by *Malassezia* and *M. gallinae* in homing pigeon that the present article describes.

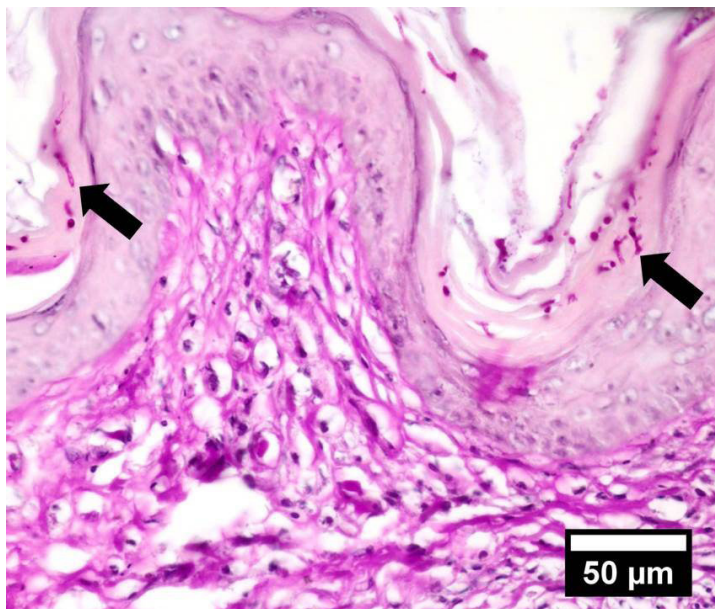
*M. gallinae* is the principal dermatophyte of gallinaeous species, and is associated with a white crust on the comb and wattles (“fowl favus”). *Microsporium* sp. has been documented as a cause of dermatologic problems in the duck, pigeon and canary (Ritchie et al., 1994). Histologic lesions included hyperkeratosis of the epidermis with invasion of the stratum corneum by fungal mycelia, acanthosis, acantholysis, and hydropic degeneration of cells in the stratum corneum. The underlying dermis was infiltrated by mononuclear inflammatory cells and contained lymphoid foci. Fungi can also be seen in the feather follicles associated with hyperkeratosis (Shivaprasad, 2008).

Occasionally birds are seen with superficial infections by yeasts morphologically resembling *Malassezia* (Schmidt et al., 2015). The genus *Malassezia* lives on the surface of the skin and mucous membranes of some mammals and birds; is a commensal organism that may eventually act as a pathogen. Changes in the host’s skin microenvironment and immune problems can cause colonies to act as opportunistic pathogens (Brasao et al., 2015). Gross changes are usually not seen in psittacine birds, and, in small passerines, they are nonspecific, with some flaking, thickening of the skin, and possible reddening, particularly if there is pruritis and self-trauma. In psittacine birds, there is usually a minimal perivascular dermal inflammatory infiltrate comprised primarily of lymphocytes and plasma cells, with



**Figure 2**

(A) The sequestered necrotic area (asterisk) in the subcutaneous of the pigeon’s head and associated yeasts (arrow). (B) Higher magnification of a portion from panel A figure stained by PAS method with numerous and positive purple yeasts (arrows) in the central part of the subcutaneous necrotic area.



**Figure 3**  
Fungal hyphae (arrows) and yeasts within the superficial keratin layer adjacent to the skin ulcer (PAS staining).

organisms found in the keratin. Small passerine birds may have significant superficial dermatitis, with a pleocellular infiltrate (Schmidt et al., 2015). *Malassezia spp.* and *M. gallinae* have been reported in birds; so that the most skin lesions caused by them appear in the superficial epidermis, hair follicles epithelial cells or associated dermis. In this study, severe and deep necrotic skin lesions were associated with fungal hyphae and especially numerous yeasts but there was no lesions and fungal structures in the feather follicles.

In conclusion, the results of the present case shows that keratinophilic fungi, especially dermatophytes in skin and feathers of birds can cause severe lesions and be a potential source of spread of disease in the human population and animals. It also suggests considering the role of *Malassezia spp.* as a risk factor in the development of skin lesions and the emergence and exacerbation of infections such as dermatophytes.

## Acknowledgements

Authors would like to thank the Faculty of Veterinary Medicine, Ferdowsi University of Mashhad for providing the necessary laboratory facilities and equipment.

## References

- Baudet, E. (1943) Dermatomycosis in a dog produced by 10 *Microsporum* (Achorion) *gallinae*. *Journal of the American Veterinary Medical Association* 102, 383-384.
- Brasao, S.C., Gomes, D.O., Ramos, G.B., Ciuffa, A.Z., Nascimento, L.R., Lima, A.M.C. and Santos, A.L.Q. (2015) *Malassezia spp.* detected at the edge of the eye of a White-eyed Parakeet (*Aratinga leucophthalma*, *stadius muller*, 1776) - A Case report. *Bioscience Journal* 31(4), 1159-1163.
- Chermette, R., Ferreiro, L. and Guillot, J. (2008) Dermatophytoses in animals. *Mycopathologia* 166(5-6), 385-405.
- Dahlhausen, R.D. (2005) Implication of mycoses in clinical disorders. In: Harrison, G.J., and Lightfoot, T.L., eds. *Clinical Avian Medicine*. Vol. II, Spix Publishing, 691-704.
- Dvorak, J. and Otcenasek, M. (1964) Geophilic, zoophilic and anthropophilic dermatophytes. A review. *Mycopathologia et Mycologia Applicata* 23, 294-296.
- Georg, L.K., Ajello, L., Friedman, L. and Brinkman, S.A. (1962) A new species of 13 *Microsporum* pathogenic to man and animals. *Sabouraudia* 1, 189-196.
- Goodenough, A.E. and Stallwood, B. (2010) Intraspecific variation and interspecific differences in the bacterial and fungal assemblages of blue tit (*Cyanistes caeruleus*) and great tit (*Parus major*) nests. *Microbial Ecology* 59(2), 221-232.
- Gordon, M.A. and Little, G.N. (1968) Trichophyton (*Microsporum?*) *gallinae* ringworm in a monkey. *Sabouraudia* 6(3), 207-212.
- Gungnani, H.C., Sharma, S. and Gupta, B. (2012) Keratinophilic fungi recovered from feathers of different species of birds in St Kitts and Nevis. *West Indian Medical Journal* 61(9), 912-915.
- Komarek, J. and Wurst, Z. (1989) Dermatophytes in clinically healthy dogs and 12 cats. *Veterinary Medicine (Praha)* 34(1), 59-63 [in Czech].
- Korting, H.C. and Zienicke, H. (1990) Dermatophytoses as occupational dermatoses in industrialized countries. Report on two cases from Munich. *Mycoses* 33(2), 86-89.

- Miljkovic, B., Pavlovski, Z., Jovicic, D., Radanovic O. and Kureljusic B. (2011) Fungi on feathers of common clinically healthy birds in Belgrade. *Biotechnology in Animal Husbandry* 27(1), 45-54.
- Miyasato, H., Yamaguchi, S., Taira, K., Hosokawa, A., Kayo, S., Sano, A., Uezato, H. and Takahashi, K. (2011) Tinea corporis caused by *Microsporum gallinae*: the first clinical case in Japan. *Journal of Dermatology* 38(5), 473- 478.
- Murata, M., Takahashi, H., Takahashi, S., Takahashi, Y., Chibana, H., Murata, Y., Sugiyama, K., Kaneshima, T., Yamaguchi, S., Miyasato, H., Murakami, M., Kano, R., Hasegawa, A., Uezato, H., Hosokawa, A. and Sano, A. (2013) Isolation of *Microsporum gallinae* from a fighting cock (*Gallus gallus domesticus*) in Japan. *Medical Mycology* 51(2), 144-149.
- Ritchie, B.W., Harrison, G.J. and Harrison, L.R. (1994) Mycoses. In: Bauck L. (eds), *Avian Medicine: Principles and application*, 997-1006.
- Schmidt, R.E. and Lightfoot, T.L. (2005) Integument. In: Harrison, G.J. and Lightfoot, T.L., eds. *Clinical Avian Medicine*. Vol. I, Spix Publishing, 395-410.
- Schmidt, R.E., Reavill, D.R. and Phalen, D.N. (2015) *Pathology of Pet and Aviary Birds*, 2nd ed. Wiley Blackwell, Iowa State Press, 179-180.
- Shivaprasad, H.L. (2008) Integumentary system. In: Fletcher, O.J., Abdul-Aziz, T., eds. *Avian histopathology*, 3rd ed. American Association of Avian Pathologists, Omni Press, 392-402.
- Takahashi, Y., Sano, A., Takizawa, K., Fukushima, K., Miyaji, M. and Nishimura, K. (2003) The epidemiology and mating behavior of *Arthroderma benhamiae* var. *erinacei* in household four-toed hedgehogs (*Atelerix albiventris*) in Japan. *Nihon Ishinkin Gakkai Zasshi* 44(1), 31-38.
- Tudor, D.C. (1983) Mycotic infections of feathers as a cause of feather pulling in pigeons and psittacine birds. *Veterinary Medicine and Small Animal Clinician* 78, 249-253.