

## Histopathological study of avian tuberculosis in naturally infected domestic pigeons with *Mycobacterium avium* subsp. *avium*

Mansour Mayahi<sup>1</sup>, Saleh Esmacilzadeh<sup>2</sup>, Nader Mosavari<sup>3</sup>, Kaveh Parvandar Asadollahi<sup>1\*</sup>

<sup>1</sup> Department of Clinical Sciences, Faculty of Veterinary Medicine, Shahid Chamran University of Ahvaz, Ahvaz, Iran

<sup>2</sup> Department of Pathobiology, Faculty of Veterinary Medicine, Shahid Chamran University of Ahvaz, Ahvaz, Iran

<sup>3</sup> Razi Vaccine & Serum Research Institute, Karaj, Iran

Received: December 21, 2012

Accepted: February 12, 2013

### Abstract

The aim of this study was to investigate the histopathology of avian tuberculosis in naturally infected domestic pigeons (*Columba livia* var. *domestica*) with *Mycobacterium avium* subsp. *avium*. Avian tuberculosis is one of the most important diseases that affect all species of birds, and is most often caused by *Mycobacterium avium* and *Mycobacterium genavense*. 80 out of more than 600 pigeons were selected based on their clinical signs and poor health conditions and under standard conditions were euthanized, necropsied, followed by bacterial culture on specific media for *Mycobacterium avium* subsp. *avium*. Fifty *Mycobacterium avium* subsp. *avium* were isolated from pigeons. All acid-fast bacilli isolates were tested by the PCR assays targeting the 16S rRNA, IS1245 and IS901 genes. After definitive identification of *Mycobacterium avium* subsp. *avium* by culturing and PCR assay, 45 fixed samples including liver, gizzard, proventriculus, intestines, kidneys and lungs from positive pigeons were subjected for histopathology studies. Tissues sections were prepared as usual and stained by haematoxylin and eosin, Ziehl-Neelsen and Congo red. Based on gross findings, liver and intestines were the most affected organs. Histologically, caseative uncalcified granulomatous inflammation was noticed in the affected organs. Also histopathology examinations showed that most of the granulomatous lesions in the lungs were in microscopic size and it seems that lungs were affected more than it was expected. In Ziehl-Neelsen's staining, a large number of acid-fast bacilli were observed within multinucleated giant cells and in necrotic areas. Also in Congo red staining, deposition of amyloid in liver and kidneys sections were observed. In conclusion, histopathology findings were typical of avian tuberculosis, including acid-fast bacilli and uncalcified caseous necrosis centers that were surrounded by multinucleated giant cells, macrophages and lymphocytes.

**Keywords:** Pigeon, *Mycobacterium avium* subsp. *avium*, amyloid, granulomatous lesions, acid-fast bacilli

---

\* Corresponding author: Kaveh Parvandar Asadollahi  
Email: kaveh\_parvandar@yahoo.com  
Tel: +98 611 3336312

## Introduction

Avian tuberculosis is one of the most important diseases that affect most orders of birds (Van darheyden, 1997 and Tell *et al.*, 2001). Several mycobacterial species can be involved in the etiology of avian tuberculosis. The disease is most often caused by *Mycobacterium avium* belonging to serotypes 1, 2 and 3 (genotype IS901+ and IS1245+) and *M. genavense* (Dvorska *et al.* 2007 and Fulton *et al.*, 2008). All species of birds can be infected with *Mycobacterium avium*. Domesticated fowl or captive wild birds are affected more frequently than those living in a wild state (Fulton *et al.*, 2008). Symptoms of mycobacteriosis in birds include chronic illness characterized by weight loss, diarrhea, dyspnea, lameness and poor feathering even though a significant number of birds die acutely without recognized symptoms (Van darheyden, 1997). The most common route of infection for susceptible birds is via the alimentary tract; however, pulmonary avian tuberculosis and egg transmission have also been described (Thorel *et al.*, 1997 and Dvorska *et al.*, 2007). Lesions are seen most frequently in liver, spleen, intestines and bone marrow and less infrequently in the other organs. Gross lesions consist of irregular grayish-yellow or grayish-white masses, which are firm but easily incised (Thorel *et al.*, 1997 and Cowper *et al.*, 2007). Microscopically, lesions of avian tuberculosis consist of a central necrotic core surrounded by epithelial macrophages, lymphocytes, multinucleated giant cells and a fibrous capsule. Calcification is rarely seen in birds. Amyloid deposition occurs mainly in the liver, but is also seen in the spleen, blood vessels and parenchyma of many organs (Tell *et al.*, 2001 and Fulton *et al.*, 2008). Acid-fast staining of granulomatous tissues typically reveals large numbers of acid-fast bacilli in contrast to other *Mycobacterium* spp, such as *M. bovis* and *M. tuberculosis*, in which organisms are rare within tubercles (Tell *et al.*, 2001). Because of the importance of avian

tuberculosis in avian diseases and the risk of the zoonotic disease, this motivated our interest to investigate the histopathology of avian tuberculosis in naturally infected domestic pigeons (*Columba livia* var. *domestica*) with *Mycobacterium avium* subsp. *avium*.

## Materials and methods

Eighty suspected pigeons (*Columba livia* var. *domestica*) to avian tuberculosis, out of more than 600 pigeons from more than 10 lofts, were selected based on their clinical signs including swollen joints, lameness, emaciation tubercle formation under the skin, granulomas in the conjunctival sac and poor health condition were collected. The birds were euthanized and subjected to necropsy examinations. Gross lesions observed in the internal organs were noted on the working sheets and immediately tissues of each bird were aseptically collected in 50 ml screw cap containers and sent to the tuberculin department of the reference laboratory in dry ice chambers for definitive identification. Subsequently, tissue samples of 58 pigeons which they had macroscopic necropsy lesions were taken and fixed in 10% neutral buffered formalin for histopathology examinations.

### *Mycobacterial isolation*

After thawing the tissue samples in the tuberculosis reference laboratory, approximately 4 grams of tissues of each bird were pooled and grinded in a pestle and mortar containing sand using sterile materials and equipments. The homogenized mixtures were decontaminated according to the NALC-NAOH method (Salfinger *et al.*, 1987). The inoculums were cultured on Lowenstein Jensen and Herrold egg media. The inoculated slopes were incubated at 41°C for 8 to 12 weeks. Genomic DNA of all isolates from each infected pigeons was extracted according to the van sooling method (Van Soolingen *et*

*al.*, 1997). All acid fast isolates (Kantor *et al.*, 1998) were tested by the PCR assays targeting the 16S rRNA gene for identification of mycobacterium members, IS1245 for mycobacterium avium complex and finally IS901 for identification of *Mycobacterium avium* subsp. *Avium* (Kunze *et al.*, 1991 and Guerrero *et al.*, 1995 and Ikonopoulos *et al.*, 2009). Analyses of PCR products were conducted on ethidium bromide-stained 2% agarose gels in a submerged electrophoresis system.

#### Histopathological examinations

As stated earlier, the samples obtained from the necropsies were fixed in 10% neutral buffered formalin. After definitive identification, 45 fixed Samples including 20 liver, and 5 samples from each of gizzard, proventriculus, intestines, kidneys and lungs from positive pigeons were selected and processed routinely, embedded in paraffin and sectioned on a manual microtome (Lieca, RM2235, Germany) at a thickness of 4 µm. Then they were stained with haematoxylin and eosin (H&E) and Ziehl-Neelsen (ZN) for the detection of acid-fast bacilli in tissues (Luna, 1968). Also Congo red staining was employed to investigate the presence of amyloid in some of the liver and kidney sections (Luna, 1968).

#### Results

Culturing, ZN staining and molecular identification confirmed that the pigeons were infected with *Mycobacterium avium* subsp. *avium* (Fig. 1 and 2). In necropsy

examinations firm grayish-yellow or grayish-white and raised nodules were found especially on liver and intestines (Fig. 3 and 4). Liver and intestines were the most frequently affected organs, and Lungs were the least affected organs while no macroscopic lesion was found in the gonads, kidneys and CNS. In necropsy and histopathology examination of 45 fixed samples, gross and microscopic granulomatous lesions were seen in all livers and Intestines and in 2 gizzards and proventriculus, but gross and microscopic granulomatous lesions were seen in one and three lungs, respectively (Table 1). Granulomatous lesions observed in the liver, lungs, gizzard, proventriculus and intestines were characterized by uncalcified caseous necrosis, which were surrounded by numerous multinucleated giant cells (they mainly consisted of foreign body giant cells), macrophages and thick layer of lymphocytes (Figure 5). Also granulomatous lesions observed in the gizzard, proventriculus and intestines were in the serosal layer (Figure 6). In Ziehl-Neelsen's staining, a large number of acid-fast bacilli were observed within multinucleated giant cells and in necrotic areas (Fig. 7). In liver sections amyloidosis in the wall of some sinusoids and bile ducts (Fig. 8) together with fatty change, cell swelling and cellular atrophy were seen. In kidney sections no granulomatous lesions were observed, but amyloidosis in the wall of uriniferous tubules was seen (Fig. 9).

**Table 1.** Comparison of observed lesions in necropsy and histopathological examinations in the organs of infected pigeons with *Mycobacterium avium* subsp. *Avium*.

Organ	Liver	Intestines	Gizzard	proventriculus	Lungs	Kidneys
Sample number	20	5	5	5	5	5
Necropsy lesions	20	5	2	2	1	-
Histopathology lesions	20	5	2	2	3	-

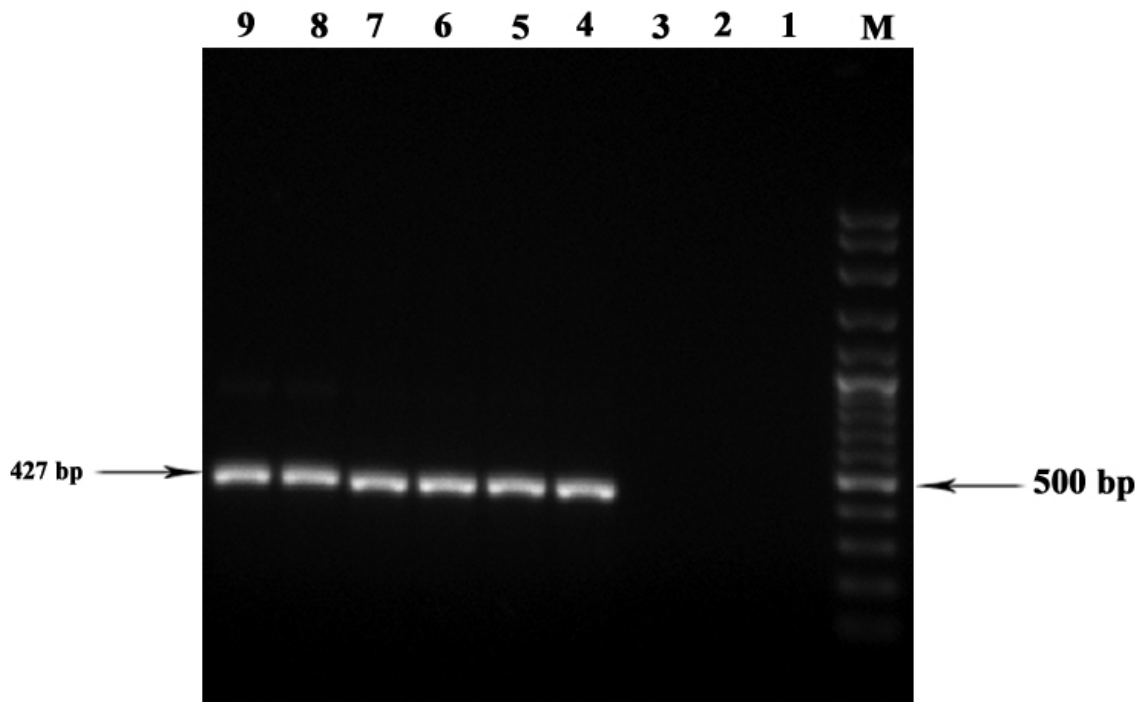


Figure 1. The example of PCR amplification product. The 427 bp specific fragment from IS1245. Lane M, DNA size marker (100 base pair ladder). Lane 1 and 2, negative controls (distilled water). Lane 3, negative species control (*Mycobacterium bovis* AN5 strain, ATCC number 35726). Lane 4, positive control (*Mycobacterium avium* subsp. *avium* D4 strain, ATCC number 35713). Lane 5 to 9 samples tested for *Mycobacterium avium* subsp. *avium*

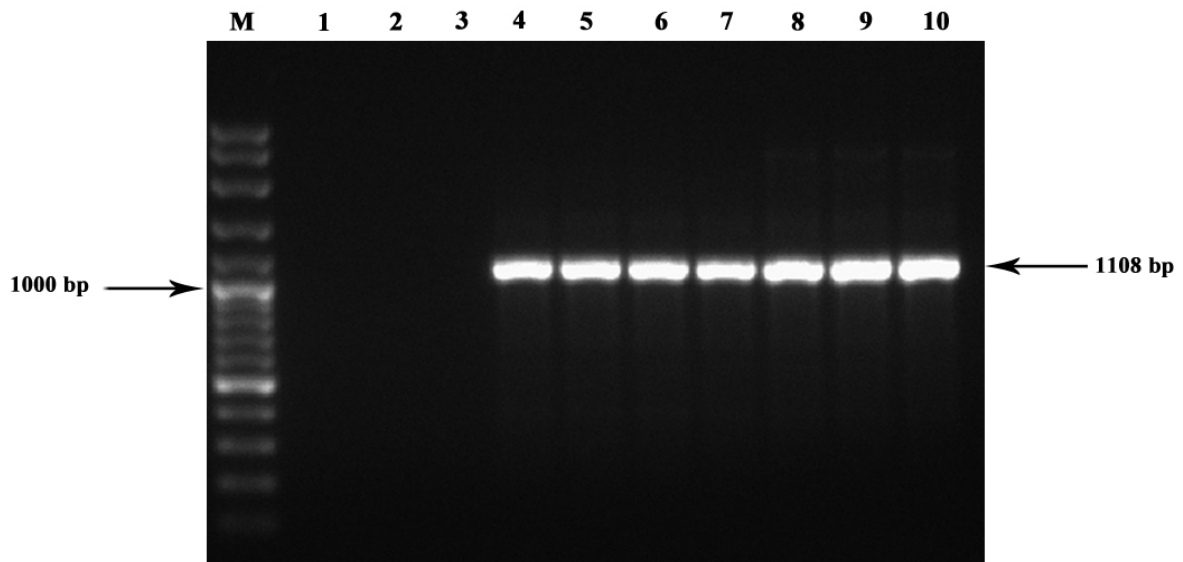
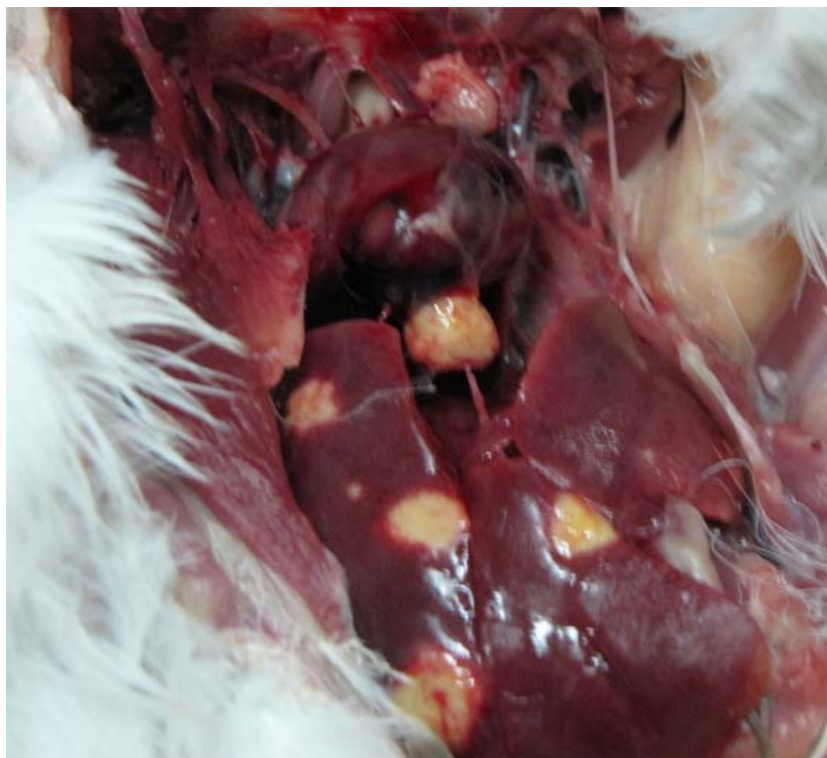
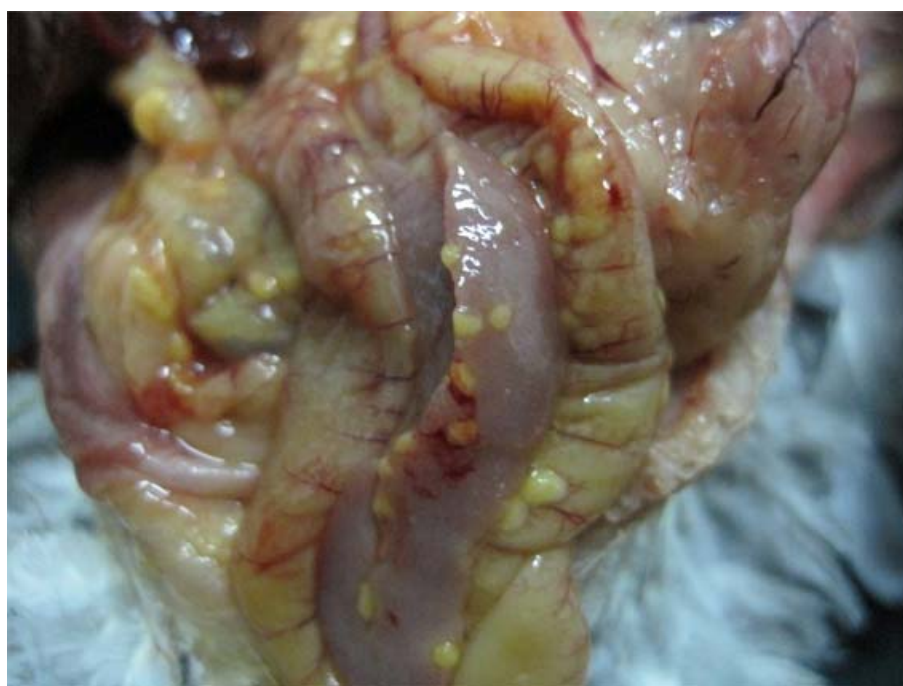

Figure 2. The example of PCR amplification product. The 1108 bp specific fragment from IS901. Lane M, DNA size marker (100 base pair ladder). Lane 1 and 2, negative controls (distilled water). Lane 3, negative species control (*Mycobacterium bovis* AN5 strain, ATCC number 35726). Lane 4, positive control (*Mycobacterium avium* subsp. *avium* D4 strain, ATCC number 35713). Lane 5 to 10 samples tested for *Mycobacterium avium* subsp. *avium*



**Figure 3. Multifocal granulomatous hepatitis in affected pigeon.**



**Figure 4. Nodular granulomatous lesions in the intestines of affected pigeon.**

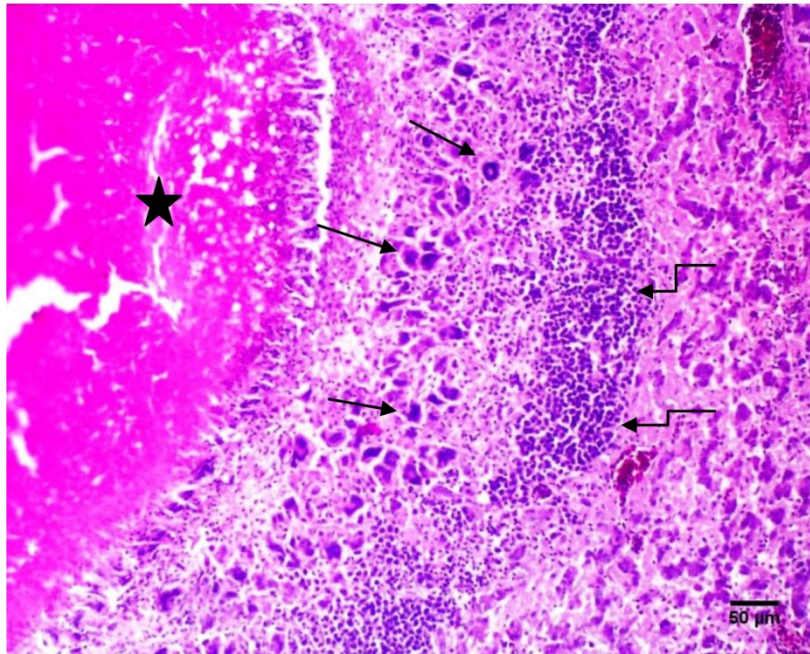


Figure 5. Liver; pigeon. Granuloma with central caseonecrosis (star) ringed by multinucleated giant cells (arrow) and thick layer of lymphocytes (elbow arrow). H&E,  $\times 100$

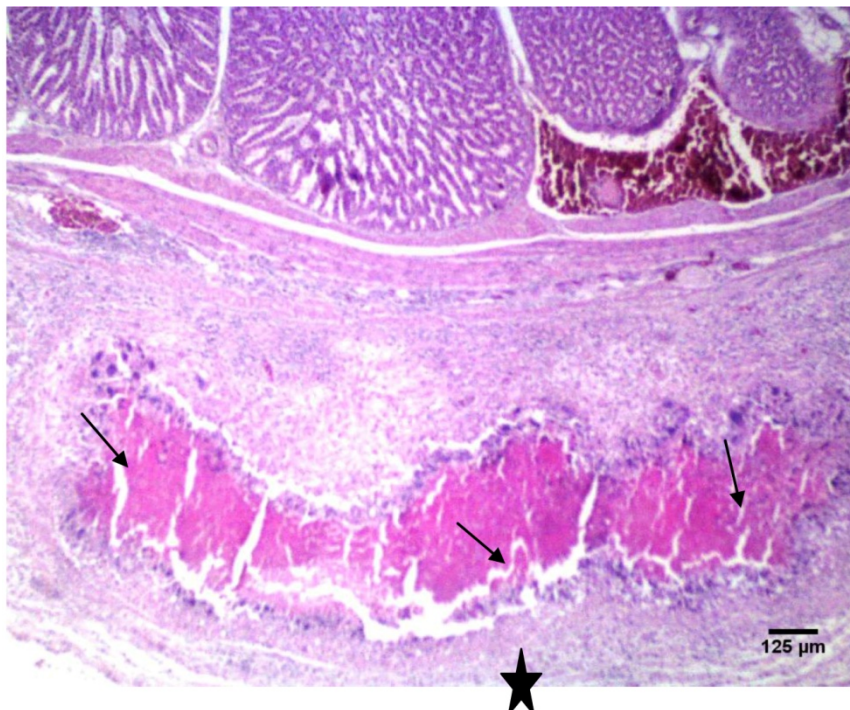


Figure 6. Proventriculus; pigeon. Granuloma in serosal layer of proventriculus, with central caseonecrosis (star) ringed by multinucleated giant cells (arrow). H&E,  $\times 40$

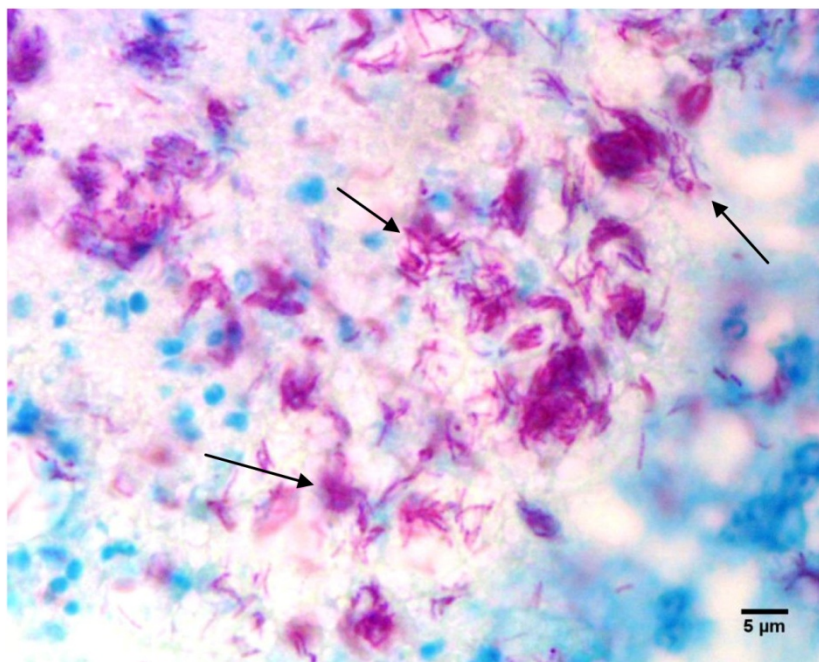


Figure 7. Liver; pigeon. Numerous acid-fast bacilli were discovered within in necrotic areas (arrow).Ziehl-Neelsen, ×1000

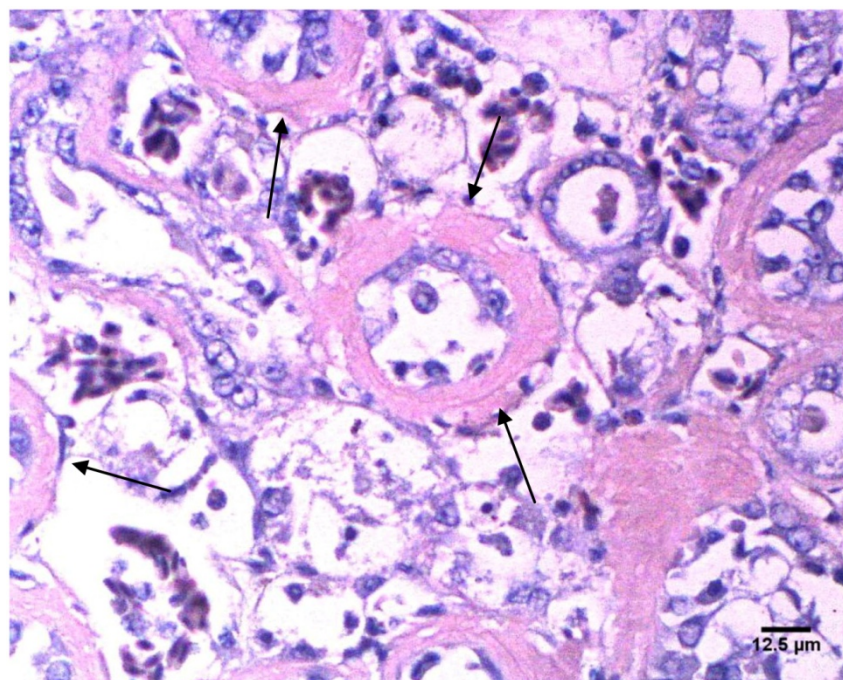
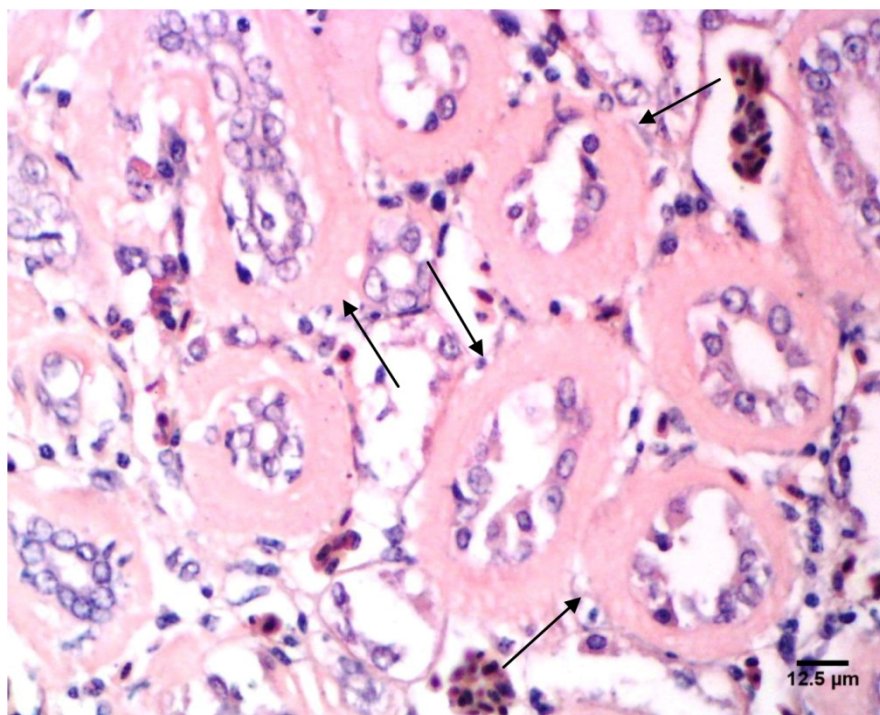


Figure 8. Liver; pigeon. Amyloid deposition in the wall of bile ducts (arrow). Congo red, ×400



**Figure 9.** Kidney; pigeon. Amyloid deposition in the wall of uriniferous tubules (arrow). Congo red,  $\times 400$

## Discussion

A few histopathology studies about avian tuberculosis are presented in the literature (Thorel *et al.*, 1997 and Cowper *et al.*, 2007 and Skoric *et al.*, 2010). Apparently, such studies have never been documented so far in Iran. In present study, all of the isolates carried IS901 insertion sequence, a pathogenicity determinant, and also IS1245 locus. Such isolates that belong to serotypes 1, 2 and 3 of *Mycobacterium avium* are considered as the most pathogenic strains of *Mycobacterium avium* in birds (Tell *et al.*, 2001 and Dvorska *et al.*, 2003). In the necropsy examinations, form and color of nodules were consistent with other records of avian tuberculosis lesions (Thorel *et al.*, 1997 and Tell *et al.*, 2003). In all the avian species, the infection is acquired by ingestion; however, an occasional occurrence of aerogenic pulmonary infection has also been described (Shitaye *et al.*, 2010) which correlated with our findings because lung lesions were observed only in one pigeon while liver and intestines were the most affected organs. Only in lungs of one pigeon

gross granulomatous lesions were seen, but in histopathology examinations, microscopic lesions were seen in 3 out of 5 lungs. It seems that lungs were affected more than it was expected and most of the granulomatous lesions in the lungs were in microscopic size. These lungs seem to be affected due to secondary hematogenous spread of infection because in other organs of these pigeons granulomatous lesions were seen (Van darheyden, 1997 and Van Soolingen *et al.*, 1997).

In histopathological examinations of granulomatous lesions, caseous necrosis centers which were encircled by numerous multinucleated giant cells, macrophages and thick layer of lymphocyte were observed (Fig. 5) and indicated a complete immune response. In humans, the ability to form multinucleated giant cells is considered one indicator of an effective immune response to tuberculosis (Byrd, 1998 and Smith *et al.*, 2000). Multinucleated giant cells may limit the growth as well as the cell-to-cell spread of *Mycobacterium tuberculosis* (Byrd, 1998 and North *et al.*, 2004 and Dannenberg, 2006). In



humans with human immunodeficiency virus/acquired immune deficiency syndrome and tuberculosis, poorly developed granulomatous do not have multinucleated giant cells (Smith *et al.*, 2000).

Amyloidosis is a pathological condition that is characterized by the deposition of insoluble fibrillar proteins in various tissues and organs of the body, following prolonged inflammation or infection (Cotran *et al.*, 1999). Amyloid deposits have been reported previously in birds with chronic inflammatory diseases such as Mycobacteriosis and Aspergillosis (Montali *et al.*, 1976 and Meyerholz *et al.*, 2005). In this study in the liver and kidney sections, deposition of amyloid was seen. Infection with *Mycobacterium avium* subsp. *avium* was a probable cause of the deposition of amyloid in these pigeons. In necropsy and histopathology examinations of granulomatous lesions no calcification was seen and this finding was consistent with lesions in mycobacterial infections described in birds (Thorel *et al.*, 1997 and Tell *et al.*, 2003). Also in Ziehl-Neelsen's staining, numerous acid fast bacilli were observed within multinucleated giant cells and in necrotic areas in contrast to other *Mycobacterium* spp, such as *M. bovis* and *M. tuberculosis*, in which organisms are rare within tubercles (Tell *et al.*, 2001). In this study among the examined organs, liver was the best organ for histopathology study of avian tuberculosis because in this organ numerous macroscopic and microscopic granulomatous lesions, acid fast bacilli and amyloid deposition were seen. In conclusion, histopathology findings were typical of avian tuberculosis, including acid fast bacilli and uncalcified caseous necrosis which were surrounded by multinucleated giant cells, macrophages and lymphocytes, also further histopathology studies on other organs of affected pigeons and on other affected bird species are suggested.

### Acknowledgments

This manuscript was extracted from

dissertation project approved by Shahid Chamran University of Ahvaz. The study was supported by deputy research of Shahid Chamran University of Ahvaz and Razi Vaccine and Serum Research Institute, Karaj, Iran.

### References

- Byrd, T.F. (1998) Multinucleated giant cell formation induced by IFN- $\gamma$ /IL-3 is associated with restriction of virulent *Mycobacterium tuberculosis* cell-to-cell invasion in human monocytes monolayers. *Cellular Immunology* **188**, 89-96.
- Cotran, R.S., Kumar, V., and Collins, T. (1999) Robbins Pathologic Basis of Diseases. Philadelphia, PA: WB Saunders Co. 251-259.
- Cowper Coles, P., Cicuta, M. E., Zumarraga, M., Etchetchoury, I., Lertora, J., Ramirez, G.V. (2007) Avian mycobacteriosis in chicken from a rural area of Argentina. *Revista Veterinaria* **18**, 72-77.
- Dannenbergh, A.M. (2006) Pathogenesis of Human Tuberculosis. Insights from the Rabbit Model. Washington, DC: American Society for Microbiology Press.
- Dvorska, L., Bull, T. J., Bartos, M., Matlova, L., Svastova, P., Weston, R. T., Kint, J., Parmova, I., Van Soolingen, D., Pavlik, I. (2003) A standardized restriction fragment length polymorphism (RFLP) method for typing *Mycobacterium avium* isolates links IS901 with virulence for birds. *Journal of Microbiological Methods* **55**, 11-27.
- Dvorska, L., Matlova, L., Ayele, W.Y., Fischer, O.A., Amemori, T., Weston, R.T., Alvarez, J., Beran, V., Moravkova, M., Pavlik, I. (2007) Avian tuberculosis in naturally infected captive water birds of the Ardeidae and Threskiornithidae families studied

- by serotyping, IS901 RFLP typing, and virulence for poultry. *Veterinary Microbiology* **119**, 366-374.
- Fulton, R., Sanchez, S. (2008) Tuberculosis, pp. 940-941. In Y.M Saif, H.J Barnes, J.R Glisson, A.M Fadly, L.R McDougald, D.E Swayne. (Eds). Disease of poultry. 12<sup>th</sup> edition. Blackwell publishing.
- Guerrero, C., Bernasconi, C., Burki, D., Bodmer, T., Telenti, A. (1995) A novel insertion element from *Mycobacterium avium*, IS1245, is a specific target for analysis of strain relatedness. *Journal of Clinical Microbiology* **33**, 303-304.
- Ikonopoulos, J., Fragkiadaki, E., Liandris, E., Sotirakoglou, K., Xylouri, E., Gazouli, M. (2009) Estimation of the spread of pathogenic mycobacteria in organic broiler farms by the polymerase chain reaction. *Veterinary Microbiology*. 278-282.
- Kantor, I.N.D., Kim, S.J., Frieden, T., Laszlo, A., Luelmo, F., Yvesnorval, P., Rieder, H., Valenzuela, P., Weyer, K. (1998) Laboratory services in tuberculosis control, Microscopy part II. World Health Organization.
- Kunze, Z.M., Wall, S., Appelberg, R., Silva, M.T., Portaels, F., McFadden, J.J. (1991) IS901, a new member of a widespread class of atypical insertion sequences, is associated with pathogenicity in *Mycobacterium avium*. *Molecular Microbiology* **5**, 226-227.
- Luna, Lee G. (1968) Manual of Histologic Staining Methods of the Armed Forces Institute of Pathology. 3<sup>rd</sup>ed. McGraw-Hill Book Company. pp. 34-36, 153-155, 220.
- Meyerholz, D.K., Vanloubbeeck, Y.E., Hoistetter, S.J., Jordan, D.M., Fales-Williams, A.J. (2005) Surveillance of amyloidosis and other diseases at necropsy in captive trumpeter swans (*Cygnus buccinator*). *Journal of Veterinary Diagnostics and Investigation* **17**, 295-298.
- Montali, R.J., Bush, M., Thoen, C.O., Smith, E. (1976): Tuberculosis in captive exotic birds. *Journal of the American Veterinarian Medical Association* **169**, 920-927.
- North, R.J. & Jung Y.J. (2004) Immunity to tuberculosis. *Annual Review in Immunology* **22**, 599-623.
- Salfinger, M., and Kafader, F.M. (1987): Comparison of two pretreatment methods for the detection of Mycobacteria of BACTEC and Lowenstein-Jensen slants. *Journal of Microbiological Methods* **6**, 315-321.
- Shitaye. J. E., Halouzka, R., Svobodova, J., Grymova, V., Grym, M., Skoric, M., Fictum, P., Beran, V., Slany, M., Pavlik, I. (2010) First isolation of *Mycobacterium genavense* in a blue headed parrot (*Pionusmenstruus*) imported from Surinam (South America) to the Czech Republic: a case report 55, 339-347
- Skoric, M., Fictum, P., Frgelecova, L., Kriz, P., Slana, I., Kaevska, M and Pavlik, I. (2010) Avian tuberculosis in a captured Ruppell's griffon vulture (*Gyps ruppellii*). *Veterinarni Medicina* **55**, 348-352.
- Smith, M.B., Boyars, M.C., Veasey, S., Woods, G.L. (2000) Generalized tuberculosis in the acquired immune deficiency syndrome. A clinicopathologic analysis based on autopsy findings. *Archives of Pathology and Laboratory Medicine* **124**, 1267-1274.
- Tell, L.A., Foley, J., Needham, M.L., Walker, R.L. (2003) Diagnosis of avian mycobacteriosis; comparison of culture, acid-fast stains, and polymerase chain reaction for the identification of *Mycobacterium avium* in experimentally inoculated Japanese quail (*Coturnixcoturnix japonica*). *Avian Diseases* **47**, 444-452.
- Tell, L.A., Woods, L., Cromie, and R.L. (2001) Mycobacteriosis in birds. *Revue*

- Scientifiqueet Technique Office International des Epizooties* **20**, 180-203.
- Thorel, M.F., Huchzermeyer, H., Weiss, R., Fontaine, J.J. (1997) *Mycobacterium avium* infections in animals. *Veterinary Research* **28**, 439-447.
- Van Dar Heyden, N. (1997) Clinical manifestations of mycobacteriosis in pet birds. *Seminars in Avian and Exotic Pet Medicines* **6**, 18-24.
- Van Soolingen, D., Hoogenboezem, T., De Haas, P.E.W., Hermans, P.W.M., Koedam, A., Teppema, K.S., Brennan, P.J., Besra, G.S., Portaels, F., Top, J., Schouls, L.M. & Van Embden, J.D.A. (1997) A novel pathogenic taxon of the *Mycobacterium tuberculosis* complex, *canettii*: characterization of an exceptional isolate from Africa. *International Journal of Systematic and Evolutionary Bacteriology* **47**, 1236-1245.

## بررسی آسیب‌شناسی سل پرندگان در کبوتران خانگی به طور طبیعی آلوده شده با مایکوباکتریوم اوئیوم تحت گونه اوئیوم

منصور میاحی<sup>۱</sup>، صالح اسماعیل زاده<sup>۲</sup>، نادر مصوری<sup>۳</sup>، کاوه پروندار اسدالهی<sup>۱\*</sup>

گروه علوم درمانگاهی دانشکده دامپزشکی دانشگاه شهید چمران اهواز، اهواز، ایران  
گروه پاتوبیولوژی دانشکده دامپزشکی دانشگاه شهید چمران اهواز، اهواز، ایران  
موسسه واکسن و سرم سازی رازی، کرج، ایران

پذیرش نهایی: ۱۳۹۱/۱۰/۰۱

دریافت مقاله: ۱۳۹۱/۰۴/۱۳

### چکیده

هدف این مطالعه بررسی آسیب‌شناسی سل پرندگان در کبوتران خانگی به طور طبیعی آلوده شده با مایکوباکتریوم اوئیوم تحت گونه اوئیوم می‌باشد. سل پرندگان یکی از مهم‌ترین بیماری‌هایی می‌باشد که بیشتر گونه‌های پرندگان را مبتلا می‌کند و اغلب توسط مایکوباکتریوم اوئیوم و مایکوباکتریوم جنارنس ایجاد می‌گردد. هشتاد کبوتر از بیش از ۶۰۰ کبوتر بر مبنای نشانه‌های بالینی و شرایط نامناسب نگهداری و سلامت انتخاب گردیدند و تحت شرایط استاندارد آسان‌کشی، کالبدگشایی و بدنال آن کشت باکتریایی بروی محیط‌های اختصاصی جهت مایکوباکتریوم اوئیوم تحت گونه اوئیوم صورت گرفت. پنجاه جدایه مایکوباکتریوم اوئیوم تحت گونه اوئیوم از کبوتران جدا گردید. همه باسیل‌های اسید فست جدا شده، به وسیله آزمایش PCR با پرایمرهای ۱۶S rRNA و IS۱۲۴۵ و IS۹۰۱ مورد بررسی قرار گرفتند. پس از تشخیص قطعی مایکوباکتریوم اوئیوم تحت گونه اوئیوم توسط کشت و آزمایش PCR، مطالعات آسیب‌شناسی بروی ۴۵ نمونه فیکس شده از کبوتران مبتلا شامل، کبد، سنگدان، پیش‌معدده، روده‌ها، کلیه‌ها و ریه‌ها صورت گرفت. مقاطع بافتی طبق روش‌های متداول تهیه و توسط روش‌های هماتوکسیلین-ئوزین، زیل نلسون و کنگورد رنگ‌آمیزی شدند. بر مبنای یافته‌های کالبدگشایی کبد و روده‌ها بیشترین ارگان‌های مبتلا بودند. به لحاظ بافت‌شناسی ضایعات التهابی کازئوز کلسیفیه نشده در ارگان‌های مبتلا مورد توجه قرار گرفت. همچنین بررسی‌های آسیب‌شناسی نشان داد که بیشتر جراحات ریوی در اندازه‌های میکروسکوپی بوده و این نشان می‌دهد که ریه‌ها به میزان بالاتری از آنچه که انتظار می‌رفت درگیر می‌باشند. در رنگ‌آمیزی زیل نلسون تعداد زیادی باکتری‌های اسید فست در داخل سلول‌های غول پیکر و مناطق نکروزه مشاهده گردید. همچنین در رنگ‌آمیزی کنگورد رسوب آمیلوئید در کبد و کلیه‌ها مشاهده شد. نتیجه یافته‌های آسیب‌شناسی، شامل باسیل‌های اسید فست، مراکز نکروزه کازئوز غیر کلسیفیه که توسط سلول‌های غول پیکر، ماکروفاژها و لنفوسیت‌ها احاطه شده بودند، معرف سل پرندگان بود.

**واژگان کلیدی:** کبوتر، مایکوباکتریوم اوئیوم تحت گونه اوئیوم، آمیلوئید، جراحات گرانولوماتوز، باسیل‌های اسید فست