

Benign mesenchymal hepatic tumors in camels (*Camelus dromedarius*)

Annahita Rezaie^{1*}, Babak Mohamadian¹, Seyed Kamal aldin Hossein Zadeh², Saharnaz Anbari²

¹Department of Pathobiology, Faculty of Veterinary Medicine, Shahid Chamran University of Ahvaz, Ahvaz, Iran

²Graduate in Veterinary Medicine, Faculty of Veterinary Medicine, Shahid Chamran University of Ahvaz, Ahvaz, Iran

Received: December 26, 2015

Accepted: July 2, 2016

Abstract

Benign tumors in liver are rare and appear not to have been previously reported in camel (*Camelus dromedarius*). This study describes histopathologic characteristics of lipoma, cavernous hemangioma and leiomyoma in the liver of dromedary camels. Seventy livers of dromedary camels which were slaughtered for human consumption were collected from July to November 2011 from the north east of Iran and they had macroscopic lesions and all of them were studied histopathologically. Microscopic examination revealed different metaplastic and neoplastic lesions in the liver of the camels. Lipoma (with multiple large vacuolated cells), cavernous hemangioma (with large lakes filled with oval erythrocytes) and leiomyoma (with homogenous intense eosinophilic spindle cells) were diagnosed as benign tumors. The relatively high occurrence of these mesenchymal neoplastic lesions may be due to some metabolic imbalances and some toxicosis in dromedary camels which live in the deserts. Also, metaplastic changes are the causes of lipoma. According to the literature, this is the first report of hepatic cavernous hemangioma and leiomyoma in camels (*Camelus dromedarius*).

Keywords: camel, liver, cavernous hemangioma, leiomyoma, lipoma

* **Corresponding author:** Annahita Rezaie
Email: a.rezaie@scu.ac.ir , rezaie20a@yahoo.com
Tel: +98 611 3330010 4131

Introduction

Hepatic mesenchymal neoplasms were derived from the liver's connective tissue and endothelium (Cullen and Brown, 2012). Also benign tumors of the liver are rare in all species.

Lipoma is a benign tumor of well differentiated adipocytes and is most common in dogs and uncommon in other species. The more common site of this tumor is subcutaneous of trunk, gluteal and proximal limbs and they are well circumscribed and unencapsulated (Goldschmidt and Hendrick, 2002). In horses, lipomas can arise as pedunculated tumors in the mesentery. In cats and rarely in dogs, lipomas with myeloid cells have been seen in adrenal, spleen and liver and are called myelolipomas. Occurrence of lipoma in the liver is unusual because adipose tissue is not normally present in the liver (Migakai and Albert, 1982).

Hemangiomas and hemangiosarcomas are tumors of endothelial cells which are more common in the skin. Hemangioma is benign tumor of vascular endothelium and is common in dogs, but it is rare in other domestic animals. They are dermal or subcutaneous tumors occurring anywhere on the body (Goldschmidt and Hendrick, 2002).

Leiomyoma is benign tumor of smooth muscle and is the most common type of gastrointestinal stromal tumors (Goldschmidt and Hendrick, 2002).

To the best of the author's knowledge, hepatic hemangioma and leiomyoma have not been previously reported to occur in camels. This paper describes the histopathologic features of benign mesenchymal neoplasms in the livers of camels in Iran.

Material and methods

In this study, 70 samples of liver were collected from July to November 2011. They came from camels that were slaughtered in the Mashhad and Tabas abattoir. Specimens were fixed in 10% neutral buffered formalin for at least 24 hours and then were routinely

processed. The tissues were paraffin embedded and sectioned at 5 μ m thickness. Then the sections were stained with the following stains: Haematoxylin and Eosin, Masson's Trichrome and Oil Red O. The last one was done on the cryocut sections.

Results

In the present work multiple benign tumors and metaplastic lesions were diagnosed which are as follows: lipoma, cavernous hemangioma, leiomyoma and osteolipomatous metaplasia.

Lipoma was diagnosed in 3 (5%) in livers. In macroscopic inspection in one liver there were multiple, white and raised nodules which were solid and firm in the cut sections and they were distributed everywhere (Fig. 1). On the basis of their gross characteristics, the tentative diagnosis was abscess. In other livers, there were only white and raised nodules. Microscopic examination revealed multiple large vacuolated cells which resembled mature lipocytes. Most of the nodules were nonencapsulated with irregular margins and were located between hepatocytes (Fig. 2). In one case there was leukocytic infiltrates between the cells. Fatty degeneration was often seen in the liver cells.

Osteolipomatous metaplasia was illustrated in one case. In gross inspection of this liver, there were hard, white and raised nodules and they could not be cut easily. The first suspected instance was calcified cyst. Microscopic lesions showed large fat cells between hepatocytes and foci of new bone spicules formation and calcification of this area showed ossification (Fig. 3).

Cavernous hemangioma was diagnosed in one camel. There was a brown and raised area seen in macroscopic inspection. The main microscopic characterizations of this liver were large cystic areas which consisted of oval erythrocytes (Fig. 4A). The walls of these spaces were coated by flattened endothelium. There were fine strands of fibrous connective tissue which separated the cysts (Fig. 4B).



Figure 1. Cut surface of lipoma in camel's liver.

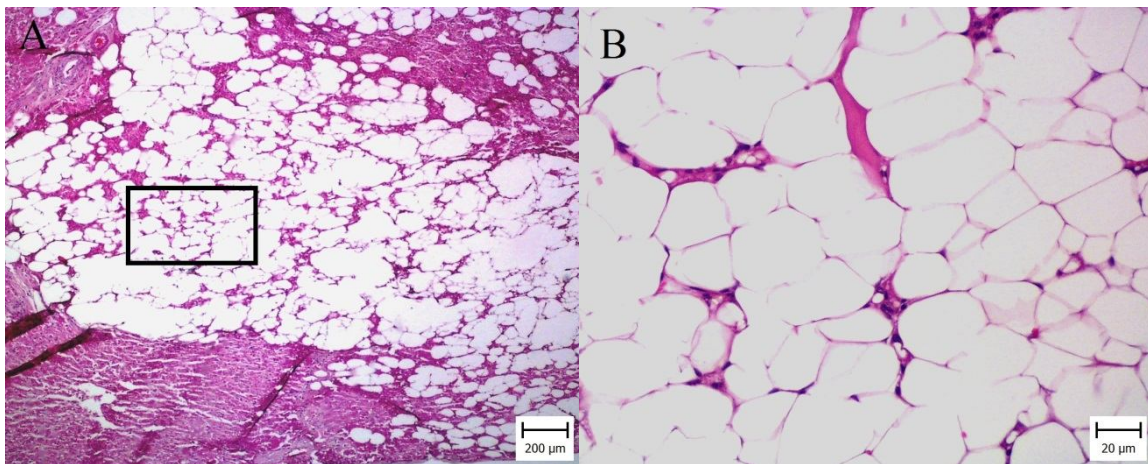


Figure 2. Photomicrographs of lipoma in camel liver (H&E). A: Adipocytes with vacuolated cytoplasm are seen between hepatocytes and they are encapsulated with irregular borders (Bar = 200 μ m). B: High-power magnifications of the indicated area of figure A. Note mature adipocytes (Bar = 20 μ m).

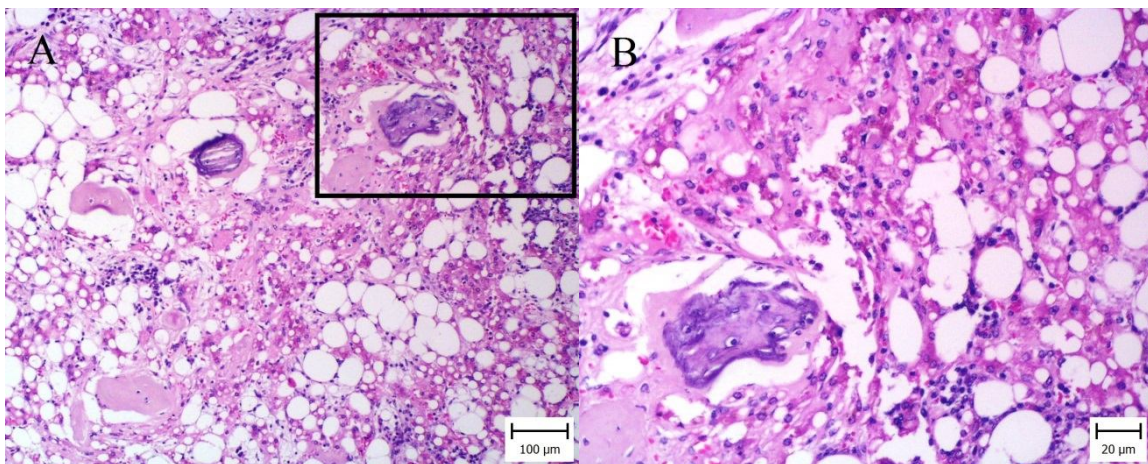


Figure 3. Photomicrographs of Steolipomatous metaplasia in camel liver (H&E). A: Note eosinophilic foci which are related to bone formation and calcification with basophilic area (Bar = 100 μ m). B: High-power magnifications of the indicated area of Figure A. Note osteocytes between adipocytes. Lipidosis in hepatocytes are obvious (Bar = 20 μ m).

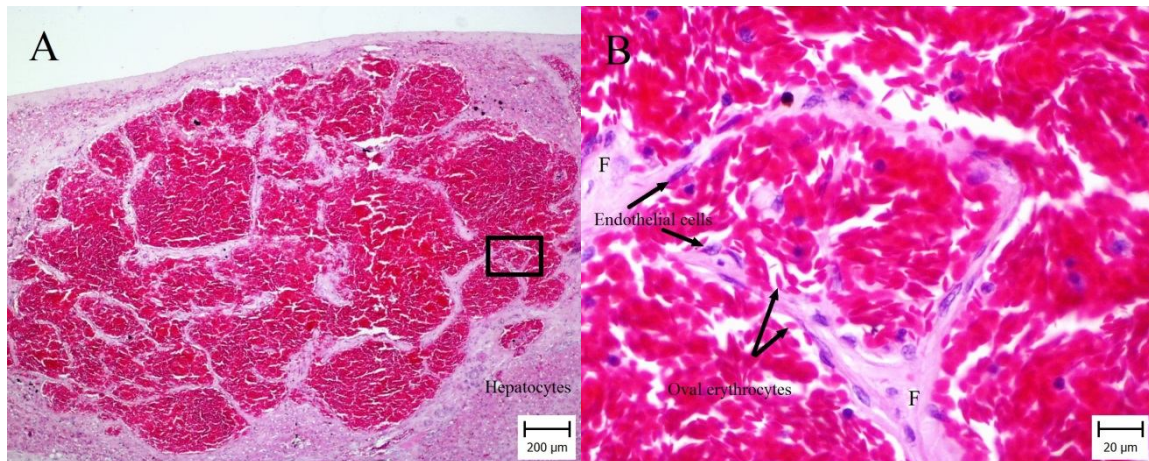


Figure 4. Photomicrographs of hemangioma in camel liver (H&E). **A:** Big cavernous spaces which are encapsulated and filled with blood (Bar = 200μm). **B:** High-power magnifications of the indicated area of Figure A. Note oval erythrocytes of camel and thin connective tissue which were covered by a single layer of endothelial cells (Bar = 20μm).

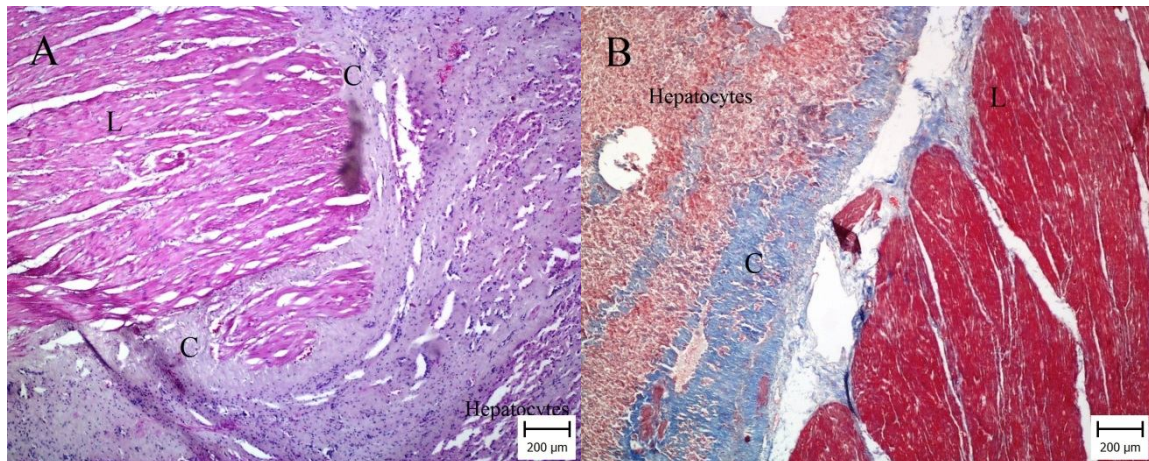


Figure 4. Photomicrographs of leiomyoma in camel liver. **A:** Neoplastic cells (L) are arranged in interlacing fascicles and note thick connective tissue around it (C) (H&E, Bar = 200μm). **B:** Neoplastic cells (L) are red and thick capsule (C) with connective tissue are blue (Masson trichrome staining. Bar = 100 μm).

Leiomyoma was detected in one camel. In macroscopic examination, there was a sunken area in the liver approximately 5 mm in diameter. Histopathologic examination revealed massive homogenous accumulated intense eosinophilic spindle cells with indistinguishable cytoplasmic borders and cigar shaped nuclei (Fig. 5A). The fascicles are densely packed and they are arranged in broad interlacing fascicles. For differentiation of these cells between fibroblast and smooth muscle cells, Masson trichrome staining was carried out. These cells were red in the mentioned staining. Therefore, they were proliferated smooth muscle cells (Fig. 5B). These cells were uniform and the mitoses were

rare. So, this mass was distinguished as leiomyoma. Other lesions were peribiliary fibrosis and hyperplasia of bile ducts.

Discussion

Lipoma: The characteristics of lipoma which have been seen in this study closely resembled that of lipomas that have been described in the liver of human beings and in human beings (Szentpali *et al.*, 2000). These hepatic lesions have been given the term "lipoma" and may be misdiagnosed as a pseudolipoma of the liver. A true hepatic lipoma can be readily distinguished from pseudolipoma on the hepatic capsule by the same criteria as used in human beings: 1) the

absence of fibrous encapsulation, 2) the presence of irregular margins, and 3) the situation of adipocytes in the hepatic parenchyma (Yoshitomi and Boorman, 1993). According to these criteria, the lesions were diagnosed as lipomas.

Although the pathogenesis and exact origin of hepatic lipomas in human beings are uncertain, these lipomatous neoplasms may be explained by the differentiation of progenitor mesenchymal cells into lipocytes. Other hypotheses for lipoma origin are that lipocytes may be differentiated from fibroblasts, pericytes located around capillaries or a perisinusoidal stem cell, which possibly gives rise to the fat-storing Ito cells (Dixon *et al.*, 1994). Although lipoma can arise from any site, there have been few reports dealing with the lipoma of the liver. Lipomatous lesions in dromedary camel have been reported by the zoological society of San Diego since 1964 to 1980 (Stroud *et al.*, 1982). Also, in that study, a case of osteolipomatous metaplasia has been reported in a bacterian camel (*Camelus ferus bactrianus*) which died suddenly in the San Diego zoo. In that case, they hypothesized that the adipose cells in the nodules develop from pluripotent, normally abundant, small connective tissue strands that pass into the lobular parenchyma of the camel liver and bone spicules develop as a further metaplastic change (Stroud *et al.*, 1982). Hepatic lipoma in a Bowhead whale has been reported and it was described as a mass under Glisson's capsule, which histopathologically was composed of mature adipose tissue. The neoplastic cells were large and spherical, and the cytoplasm was so distended by fat that the cell walls were barely visible and the nuclei were elongated (Migaki and Albert, 1982). Lipoma in bacterian camels has been reported from Mongolia (Chen, 1995). In an epidemiological survey on multiple lipomas in the liver of bacterian camels, the relationship between lipomas in bacterian camels grazing on the desert and semidesert grassland has been reported and the incidence rate may reach up to 27%. The iron and copper levels of liver

also have been determined. Based on the results, the lipomas were related to low copper level, which was probably caused by the increase of iron (Zhuo *et al.*, 1995). Nourani and Salimi (2013) reported 3.2% lipomatous lesions in the liver of camels. The origin of cells and the cause is unknown and investigation on this subject is essential.

Hemangioma: Microscopic characteristics closely resembled hepatic cavernous hemangioma described in the liver of human beings. This tumor has to differentiate from telangiectasia whose characteristics are shrunken hepatocytes and dilated blood-filled sinusoids. In this case, there were no hepatocytes between cysts and they were located in the periphery. Cutaneous vascular neoplasia has been reported in cats as a benign solitary tumor without site predilection (Miller *et al.*, 1992). In a large survey, splenic hemangioma was more common in canine visceral hemangioma and only one hepatic hemangioma was reported in cat (Schultheiss, 2004). Hemangioma in hepatic lymph node of a dog has been reported as a circumscribed and not encapsulated with minimal compression of the adjacent tissue with 1 to 4 mm in diameter (Hogenesch and Hahn, 1998). Although hepatic hemangioma has been recorded in guinea pigs (Hammer, 2005), pigs (Tanimoto and ohtsuki, 1992), ferrets (Cross, 1987) and dogs (Rallis *et al.*, 1998), to the best of the authors' knowledge, this is the first report of cavernous hemangioma in camels (*Camelus dromedarius*).

Leiomyoma: The liver of camel shows excess of the thick interlobular connective tissue and thick interlobular septa (Lalla and Drommer, 1997). This report showed the presence of diffuse eosinophilic spindle cells which were similar to connective tissue and the masson trichrome staining supported the entity of these fascicles. There are several sites of smooth muscle in the liver that can give rise to a leiomyoma: the walls of the hepatic and portal veins and the hepatic arteries and arterioles (Esmaeilzadeh *et al.*, 2007). Hepatic leiomyoma has been reported in cattle and it

was thought to have originated from the smooth muscle of the veins (Esmailzadeh *et al.*, 2007). According to the review literature, this is the first report of leiomyoma in camel (*Camelus dromedarius*).

In summary, this paper has described the presence of lipoma, cavernous hemangioma and leiomyoma in the liver of camel (*Camelus dromedarius*). These neoplasms were incidental findings in the abattoir and appear to have no clinical significance but the apparently uncommon occurrence of 3 tumors in *Camelus dromedarius* within a 3 month period is noteworthy. To the best of the author's knowledge, this is the first report of cavernous hemangioma and leiomyoma in the liver of camel (*Camelus dromedarius*).

Acknowledgment

The Authors wish to express their gratitude to the Research Council of Shahid Chamran University for their financial supports and thank Mr. and Mrs. Behdarvand for their technical assistance.

References

- Chen CH (1995) Pathological Studies on Liver Lipoma of Bactrian Camels. *Journal of Gansu agricultural university* **3**, 1-6 [Abstract].
- Cross BM (1987) Hepatic Vascular Neoplasms in a Colony of Ferrets. *Veterinary Pathology* **24**, 94-96.
- Dixon D, Yoshitomi K, Boorman GA, Maronpot RR (1994) "Lipomatous" Lesions of unknown cellular origin in the liver of B6C3F1 mice. *Veterinary Pathology* **31**, 173-182.
- Esmailzadeh S, Rezaie A, Mazaheri Y (2007) Hepatic Leiomyoma in a cow. *Veterinary Record* **161**, 423-424.
- Hammer M, Klopfleisch R, Teifke JP, Löhr CV(2005) Cavernous or capillary haemangioma in two unrelated guinea pigs. *Veterinary Record*, 157(12), 352-353.
- Hogenesch H, Hahn FF (1998) Primary vascular neoplasms of lymph nodes in the dog. *Veterinary pathology* **35**, 74-76.
- Goldschmidt MH, Hendrick MJ (2002) Tumors of the skin and soft tissues. In: *Tumors in Domestic Animals*, 4th edit., Meuten DJ, Iowa State Press, Blackwell Publishing Company, Ames, Iowa, pp.45-117.
- Lalla S, Drommer W (1997) Observations on the fine structure of the liver in the camel (*Camelus dromedaries*). *Anatomia Histologia Embryologia* **26**, 271-275.
- (2002).
- Migakai G, Albert TF (1982) Lipoma of the liver in a bowhead whale (*Balaenamysticetus*). *Veterinary Pathology* **19**, 329-331.
- Miller MA, Ramos JA, Kreeger JM (1992) Cutaneous vascular neoplasia in 15 cats: clinical, morphologic and immunohistochemical studies. *Veterinary Pathology* **29**, 329-336.
- Rallis TS, Tontis D, Adamama-Moraitou KK, Mylonakis ME, Papazoglou L(1998) Hepatic haemangioma associated with ascites in a dog. *Veterinary Record* **142**(25), 700-701.
- Schultheiss PC (2004) A retrospective study of visceral and nonvisceral hemangiosarcoma and hemangioma in domestic animals. *Journal of Veterinary diagnostic investigation* **16**, 522-526.
- Stroud RK, Griner LA, Higgins WY (1982) Osteolipomatous metaplasia in the liver of cameloids. *Veterinary Pathology* **19** (2), 215-217.
- Szentpali K, Petri A, Olah T, Szendrenyi V, Ivanyi B, *et al.*(2000) Lipoma of the liver: a differential – diagnostic problem. *Langenbeck's Archives of Surgery* **385**, 31-33.
- Tanimoto T, Ohtsuki Y(1992) Hepatic hemangioma in a pig. *Veterinary Record* **131**(8), 176-177.
- Yoshitomi K, Boorman GA (1993) A Pseudolipoma on the Diaphragmatic Surface of the Liver in a Female

- B6C3F1 Mouse. *Veterinary Pathology* **30**, 209-211.
- Cullen JM and Brown DL. Hepatobiliary system and exocrine pancreas In: Zachary JF, McGavin MD(2012) *Pathologic basis of Veterinary disease*. 5th ed. Elsevier. PP: 444-5.
- Zhuo M, Zongping L, Debing CH (1995) The discovery of multiple lipomas in the liver of bactrian camels and study on their relationship with trace elements. *Actaveterinaria et zootechnica, sinica* 26(1): 87-92 [Abstract].

تومورهای خوش خیم مزانشیمی کبد در شتر یک کوهانه

آناهیتا رضایی¹، بابک محمدیان¹، کمال الدین حسین زاده²، سحرناز عنبری²

¹ گروه پاتوبیولوژی، دانشکده دامپزشکی، دانشگاه شهید چمران اهواز، اهواز، ایران

² دانش آموخته دکتری حرفه ای دامپزشکی، دانشکده دامپزشکی، دانشگاه شهید چمران اهواز، اهواز، ایران

دریافت مقاله: 1394/10/05 پذیرش نهایی: 1395/04/12

چکیده

تومورهای خوش خیم در کبد نادر می‌باشند و در کبد شتر گزارش نشده است. این مطالعه به شرح مشخصات هیستوپاتولوژی لیپوم، همانژیوم غاری و لیومیوم در کبد شتران می‌پردازد. هفتاد کبد شتر که به منظور مصرف انسانی مورد کشتار قرار گرفتند از تیر تا آبان ماه 1390 از شمال شرقی ایران جمع‌آوری شدند و آن‌ها دارای ضایعات ماکروسکوپی بودند و تمامی کبدها از نظر هیستوپاتولوژی مورد مطالعه قرار گرفتند. بررسی هیستوپاتولوژی موید تغییرات متاپلاستیک و نئوپلاستیک مختلف در کبد شتران بود. لیپوم (همراه با تعداد متعددی سلول‌های بزرگ واکوتله)، همانژیوم غاری (همراه با دریاچه‌های بزرگ مملو از اریتروسیت‌های بیضی شکل) و لیومیوم (همراه با سلول‌های دوکی شکل یک دست، ائوزینوفیلیک و فشرده) به عنوان تومورهای خوش خیم تشخیص داده شدند. شیوع به نسبت بالای این جراحات نئوپلاستی مزانشیمی ممکن است به علت برخی بیماری‌های متابولیکی و یا مسمومیت در شتران باشد که در صحرا زندگی می‌کنند. همچنین برخی تغییرات متاپلاستی نیز می‌تواند مسبب لیپوم باشد بر اساس جستجوهای صورت گرفته این اولین گزارش همانژیوم غاری و لیومیوم در کبد شتران می‌باشد.

واژگان کلیدی: شتر یک کوهانه، کبد، همانژیوم غاری، لیومیوم، لیپوم