

## Clinical and pathological study of experimentally- induced yew (*Taxus baccata*) poisoning in sheep

Mohammadreza Aslani<sup>1\*</sup>, Alireza Taghavi -Razavi-Zadeh<sup>2</sup>, Ahmadreza Movassaghi<sup>3</sup>, Mehrdad Mohri<sup>1</sup>,  
Abolghassem Nabipour<sup>4</sup>, Ali Rezakhani<sup>5</sup>, Samaneh Yaghoobi-Faz<sup>2</sup>, Ali Andalib-Moghadam<sup>2</sup>, Fatemeh Ahmadi<sup>2</sup>

<sup>1</sup>Department of Clinical Sciences and Center of Excellence in Ruminant Abortion and Neonatal Mortality, School of Veterinary Medicine, Ferdowsi University of Mashhad, Mashhad, Iran

<sup>2</sup>Department of Clinical Sciences, School of Veterinary Medicine, Ferdowsi University of Mashhad, Mashhad, Iran

<sup>3</sup>Department of Pathobiology, Center of Excellence in Ruminant Abortion and Neonatal Mortality, School of Veterinary Medicine, Ferdowsi University of Mashhad, Mashhad, Iran

<sup>4</sup>Department of Basic Sciences, Center of Excellence in Ruminant Abortion and Neonatal Mortality, School of Veterinary Medicine, Ferdowsi University of Mashhad, Mashhad, Iran

<sup>5</sup>Department of Clinical Studies, School of Veterinary Medicine, Shiraz University, Shiraz, Iran

Received: June 18, 2011

Accepted: July 19, 2011

### Abstract

Acute yew (*Taxus baccata*) intoxication was induced in 7 adult sheep by oral administration of the plant materials at the dose of 2.5g/kg body weight. Blood samples for hematology and serum biochemistry were collected before and after the induced intoxication. Electrocardiography was performed using a base-apex lead. Intoxicated animals displayed lethargy, depression, bradycardia and varying intensity of heart sounds. The ECGs of intoxicated sheep showed a variety of arrhythmias and abnormalities including multifocal ventricular tachycardia, idioventricular and idiojunctional rhythm and QRS and T widening. Four sheep died within 4-16 hours after yew administration. Significant increase of white blood cells, total neutrophil counts and serum sodium concentration were observed. Post mortem examination and histological evaluation were done with special regards on tissue changes of the myocardium and conduction system. There were hyperemia, focal hemorrhage and multifocal nonsuppurative interstitial myocarditis with mild focal cardiac muscle cell degeneration and necrosis in the affected hearts which appeared more prominent in the right atrium. Histopathological examination of cardiac conduction system also revealed moderate to severe interstitial edema with inflammation of the SA-node, AV-node, the bundle branches and His-bundle in all cases which was most severe in the AV-node and the His-bundle.

Oral administration of dried leaves of *T. baccata*, at the dose of 2.5g/kg can induce acute toxicity, manifested clinically by a variety of cardiac arrhythmia and myocardial lesions including special conduction system in pathology.

**Keywords** Yew, *Taxus baccata*, Sheep, Cardiac arrhythmias, Cardiac conduction system, Plant poisoning

---

\* Corresponding author:  
M.R. Aslani,  
Email: mraslani@um.ac.ir  
Fax: 098-511-8763852

## Introduction

*Taxus* (yew) plants are popular evergreen ornamental shrubs belonging to the family *Taxaceae*. This plant family comprises 3 genera and approximately 15 species that are found in both hemispheres (Lacasse *et al.*, 2007). The most common *taxus* species are *Taxus baccata* (English yew, Common yew), *Taxus brevifolia* (Western yew, Pacific yew), *Taxus Canadensis* (American yew) and *Taxus cuspidate* (Japanese yew) (Wilson *et al.*, 2001). *Taxus baccata* and *Taxus brevifolis* are native in northern part of Iran and because of reddish-brown bark covering the trunk and branches, locally named as Sorkhedar (Aslani, 2005). Iranian medieval physician, Avicenna (980-1037 AD) has used the extract of *T. baccata* named Zarnab as a cardiac remedy (Tekol, 2007).

Yew plants are highly toxic throughout the year, whether fresh or dried and have been implicated in poisonings and fatalities in different animals including cattle (Alden *et al.*, 1977; Thomson and Barker, 1978; Panter *et al.*, 1993), horses (Parkinson, 1996; Cope *et al.*, 2004; Tiwary *et al.*, 2005), sheep and goats (Maxie, 1991; Rae and Binnigton, 1995), moose (Handeland, 2008), dogs (Evans and Cook, 1991; Taksdal, 1994), pigs (Ruha *et al.*, 2002), monkeys (Lacasse *et al.*, 2007) and brown bear (Bacciarini *et al.*, 1999). These plants contain toxic alkaloids (taxins) which are present in all parts of the plant except the scarlet aril (berry) surrounding the seed that is gelatinous and very sweet tasting. The seeds within the aril are also extremely toxic (Wilson and Hooser, 2007). The maximal concentration of taxins in the foliage occurs during the winter season and the older leaves are more toxic than the new ones (Tiwary *et al.*, 2005). It has also been reported that taxins are relatively abundant on *T. baccata* and *T. cuspidate* while minimal amounts are found in *T. brevifolia* (Sufness, 1995; Itokawa, 2003).

Taxin alkaloids are cardiotoxic and death of intoxicated animals is considered to be due to cardiac arrhythmias together with cardiovascular collapse or respiratory failure

(or both) (Hare, 1998; Wilson and Hooser, 2007).

The clinical cases of yew poisoning occur in livestock, most frequently in cattle and horses. These animals are accidentally poisoned when yew trimmings, or wreaths made of yew, are thrown into the pasture or into the feeders, where they are easily accessible to horses, cattle, sheep and / or goats (Thomson and Barker, 1978; Alden *et al.*, 1977; Maxie, 1991).

The objectives of this study were to elucidate the clinical, clinicalpathological and pathological changes in experimental yew poisoning in sheep.

## Materials and methods

### Plant material

Yew (*Taxus baccata*) foliages were collected in May from the Golestan National Park, Golestan Province of Northern Iran. The plant material was dried at room temperature, leaves separated from small branches and finely ground to powder.

### Animals

Seven Baloochi ewes, 3-4 years of age and weighing 35-46 Kg were obtained from the Animal Breeding Center of Mashhad. After 2 week acclimation, the powder of yew was administered orally to sheep as an aqueous suspension in a single LD<sub>min</sub> of 2.5 g/kg body weight (Wilson *et al.*, 2001) using a stomach tube. The animals were observed for any abnormal changes, and vital signs were recorded repeatedly at 4 hours interval after yew administration.

### Electrocardiography

The baseline of the electrocardiograms (ECGs) was recorded using a base-apex lead (Radostits *et al.*, 2007). ECGs were evaluated for heart rate and rhythm, abnormalities of conduction, and amplitude and duration of P, QRS, ST and QT intervals. ECG recorded repeatedly at 4 hours interval after yew administration.

### *Blood sampling, hematology and serum biochemistry*

Venous blood samples with and without anticoagulant were collected for hematology and measurement of serum sodium, potassium, calcium, magnesium, blood urea nitrogen (BUN), creatinine, and troponin I concentrations and serum creatin kinase (CK), aspartate amino transferase (AST), lactate dehydrogenase (LDH), gamma glutamyl transferase (GGT) and alkaline phosphates (AP) activity at baseline (before yew administration) and at the times 4, 8, 12, 24, 36, 48 hours using flame photometry (Elico Model CI 360, India) and automated biochemical analyzer (Biotechnica, Targa 3000, Italy).

### *Post-mortem examination*

Four sheep were necropsied immediately after death and all gross lesions were recorded. For histopathological examination, tissue samples of forestomachs, abomasums, intestines, liver, kidneys, lungs and the different parts of the central nervous system (CNS) were collected, fixed in 10% neutral buffered formalin and processed for routine histology. Tissue sections were stained with Hematoxylin and eosin for light microscopic examination.

For histopathological examination of cardiac special conduction system, 4 hearts of intoxicated sheep and 2 hearts as control from healthy sheep (obtained from a regional slaughterhouse) were used. The hearts were flushed with warm (40°C) normal saline and perfused with 10% buffered formalin solution. For studying the sinoatrial node (SA-node), the upper part of the right atrium along with the cranial vena cava and a part of right auricle was separated and submerged in the same fixative for 96hrs.

For studying the atrioventricular node (AV-node) and atrioventricular bundle, the lower part of the interatrial septum (from the upper part level of the coronary sinus) among with the upper part of the interventricular septum was removed.

The samples were trimmed and processed.

Serial sections at 6µm were made from the samples. The sections preserved and then were selected by the interval of 3, stained with methods of Green Masson's Trichrome and Hematoxyline and eosin.

The experiment was approved by the Animal Welfare Committee of the Veterinary School of the Ferdowsi University of Mashhad.

### *Statistical analysis*

The statistical analyses were carried out using the SPSS software (version 16). Wilcoxon signed rank test was used to compare 48 hours data and repeated measure ANOVA was used to compare 8 hour and base line data. Results were presented as mean ± standard deviation and significance was defined as values of  $P < 0.05$ .

## **Results**

### *Clinical findings*

The severity of clinical signs varied appreciably between individuals. Four sheep died within 4-16 hours after yew administration and 3 sheep survived. One sheep suddenly dropped and died without any clinical sign of intoxication, 4 hours after receiving of the plant material. Clinical signs in other sheep included lethargy, depression, reluctance to move, bruxism, tremor, restlessness and resistance against any manipulation such as blood collection, rumen hypotony which progressed to atony in later stages, dyspnea, hypothermia, sternal or lateral recumbency, arrhythmia and varying intensity of heart sounds. Heart rate increased significantly in early stages and decreased to lowest rate at time 24 h and then elevated to near normal rate of base line at time 48 h (Fig 1). Death occurred without any struggling.

### *ECG findings*

Electrocardiographic studies of intoxicated sheep revealed, sinus tachycardia, ventricular premature beats, multifocal ventricular tachycardia, idioventricular and idiojunctional rhythm with arrest and silent atria, atrial

fibrillation, atrial tachycardia, S-T segment slurring, QRS and T widening, AV dissociation, S-T segment depression, episodes of cardiac pacemaker arrest, R on T phenomenon, inverted T and ventricular fibrillation. Sinus tachycardia was the first

change and developed 30-60 minutes after yew administration. In fatal cases, after 3-4 hours, ventricular tachycardia was observed. ECG abnormalities were also seen up to 48-56 hours after dosing in survived sheep. Some of the ECG changes are shown in Fig 2.

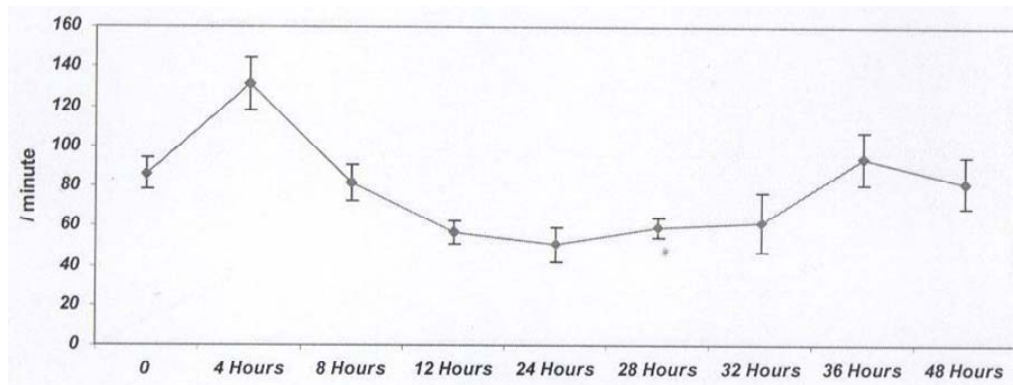


Figure 1. Mean heart rate (beats/min) of sheep experimentally intoxicated with *T. baccata*.

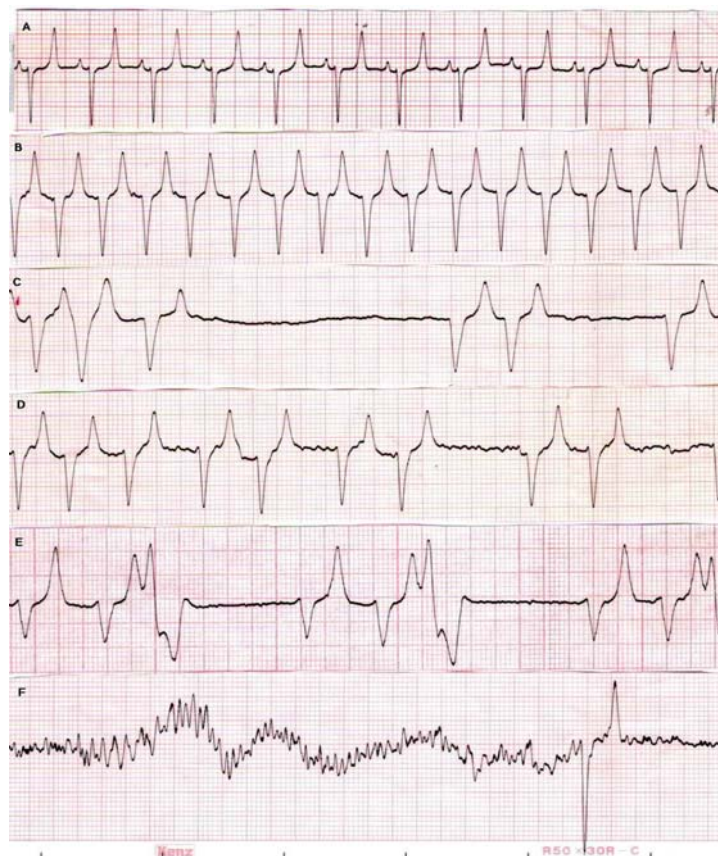


Figure 2. ECG strips obtained from sheep experimentally intoxicated with *T. baccata* using Base apex leads (sensitivity 10 mm/mv and paper speed 25mm/s). A. Normal rhythm, B. Atrial tachycardia, C. Idioventricular rhythm with arrest and silent atria, D. Atrial fibrillation, E. Idioventricular rhythm, ventricular premature beats and R on T phenomenon, F. Ventricular fibrillation.

### Hematology and serum biochemistry

The significant changes in CK, AST, GGT, LDH and AP activity; and serum potassium, calcium, magnesium and creatinine concentrations did not observed. Significant decrease of serum BUN concentration was observed at time 4h. Marked serum potassium elevation (8meq/l) was observed in 2 intoxicated sheep, one fatal case and a survived one, at time

4 and 48h respectively. The significant elevation in the serum sodium concentration, white blood cell counts (WBC) and neutrophil counts were observed at time 4h ( $P<0.05$ ). Two spike in serum troponin I concentration ( $P=0.07$ ) were also observed at times 4 and 38h. These data is shown in [Table 1](#).

**Table 1. Hematological and biochemical values in sheep that intoxicated with yew (*T. baccata*).**

Parameters	Time (hour)						
	0	4	8	12	24	36	48
PCV(%)	31.7±6.1	32.3±5.5	32.33±8.3	30 ±7.9	27.33±8.9	29.7±7.5	30.3±6.5
WBC( $10^9/L$ )	10.6 ±1.9	15.2 ±5.1 <sup>a</sup>	17 ±10.1	11±4.9	9.4±0.9	15.7±9.5	9.3±0.9
Neut( $10^9/L$ )	5.21±1.6	9.7±4.8 <sup>a</sup>	9.4±4.6	6.1±3.1	5.2±0.9	8.7±6.5	6.4±1.7
Lymph( $10^9/L$ )	4.3±1.7	4.1±2.5	6.8±6.5	4.4±2	3.6±1.3	5.5±2.9	4.7±0.51
CK (IU/L)	124.7±12.5	149.3±23.7	120±22.6	190±106.6	204.7±190	225.3±144.6	119.3±8
Troponin I(ng/ml)	0.14±0.1	0.16±0.11	0.35 ±0.2	0.22±0.16	0.147±0.13	0.133±0.09	0.127±0.12
AST I(U/L)	93.1±23.1	89±10	88.2±5.9	81.6±6.8	80.3±9.2	98.4±16.7	96.2±8.5
GGT (IU/L)	47±6.7	47.7±6.7	44±7.2	41.4±6	36.7±1.8	36±6.8	96.2±8.5
ALP (IU/L)	157±63.5	139.3±40.5	145±32.2	138±23.8	149±43.5	153.1±52.6	180.8±70.6
TP (g/L)	7.03±0.96	7.4±0.45	7.31±0.8	7±1.1	6.2±0.88	6.83±0.6	7.21±0.57
Glucose(mmol/L)	5.49±1.64	6.37±3.33	7.18±1.73	5.24±1.88	4.89±3.55	4.64±2.86	6.39 ±2.10
BUN(mmol/L)	7.28±0.99	5.03±0.89 <sup>a</sup>	4.21±1.43	4.03 ±1.20	5.43 ±2.50	5.68±2.96	4.43±2.61
Creatinine( $\mu$ mol/L)	74.26±17.68	67.18±8.84	68.95±3.5	70.72±12.38	86.63±0.88	76.91±4.42	82.21±8.84
Na (mmol/L)	144±2.6	147.1±1.5 <sup>a</sup>	145.7±4.9	147.3±7.3	146±4.6	145.7 ±2.5	149.3±0.6
K (mmol/L)	4.5±0.5	4.3±0.3	4.4±0.2	4.7±1	4.5±0.5	4.6±0.1	5.7 ±1.1
Ca (mmol/L)	2.28±0.17	2.13 ±0.06	2.15 ±0.03	2.18±0.18	1.98±0.15	2.0±0.1	1.7±0.73
Mg (mmol/L)	1.2±0.15	1.3±0.2	1.1±0.15	1.1±0.2	1.3±0.3	1.3±0.4	0.85±0.55

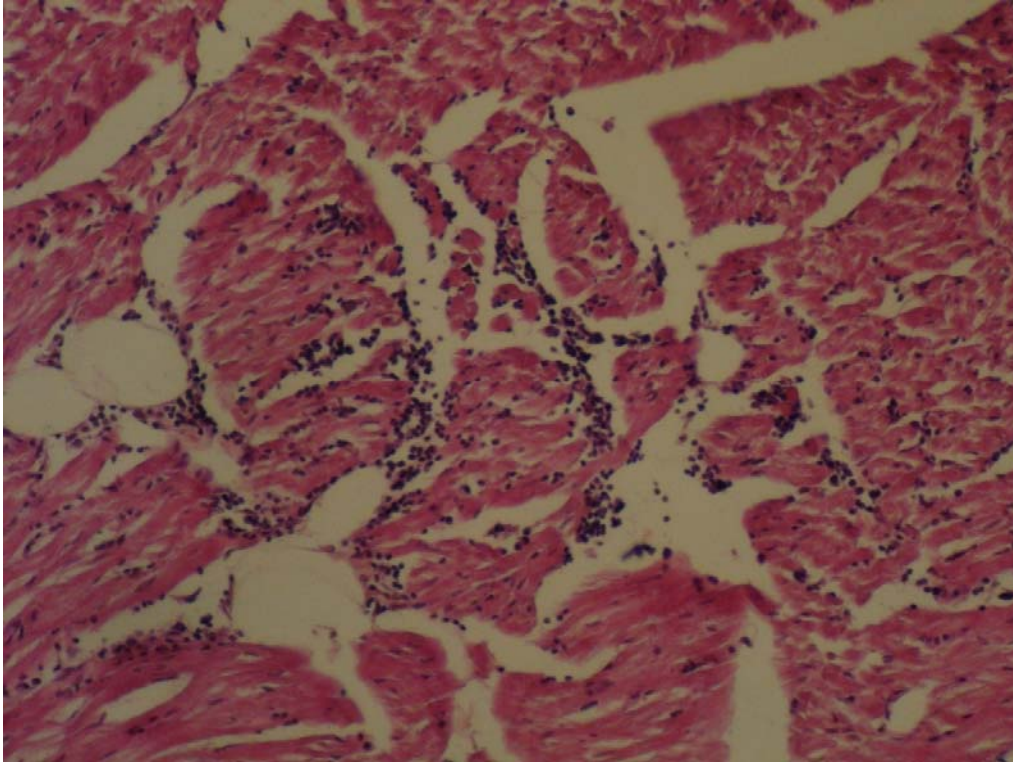
Significant difference with the base line value ( $P<0.05$ ).

### Pathology findings

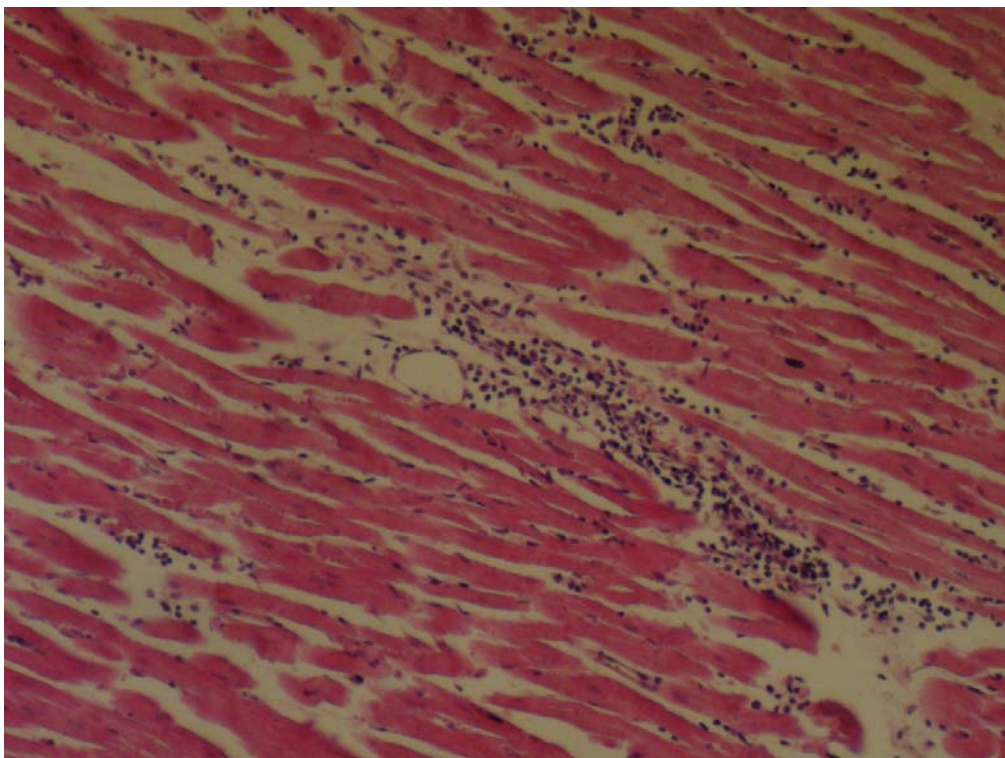
Gross examination showed general vascular dilation, hepatic and splenic congestion; pulmonary edema, some petechial hemorrhages and mottling on the epicardium and endocardium, mild congestion of abomasums and duodenum.

Multifocal nonsuppurative interstitial myocarditis with mild focal cardiac muscle cell degeneration and necrosis as well as hyperemia and focal hemorrhages were

observed in the affected hearts which appeared more prominent in the right atrium. There was mild multifocal to diffuse infiltration of mononuclear inflammatory cells in the interstitial space of the ventricles especially in the left side ([Fig 3](#)). There was some evidence of the contraction band necrosis. There was also mild multifocal nonsuppurative interstitial myocarditis which was more prominent close to swelled Purkinje fibers and in the right atrium ([Fig. 4](#)). The lungs were severely



**Figure 3.** Necrosis of the myocardium in the right atrium associated with infiltration of mononuclear inflammatory cells. Hematoxylin and eosin,  $\times 320$ .



**Figure 4.** Infiltration of mononuclear inflammatory cells in the interstitial space of the left ventricle. Hematoxylin and eosin,  $\times 320$ .

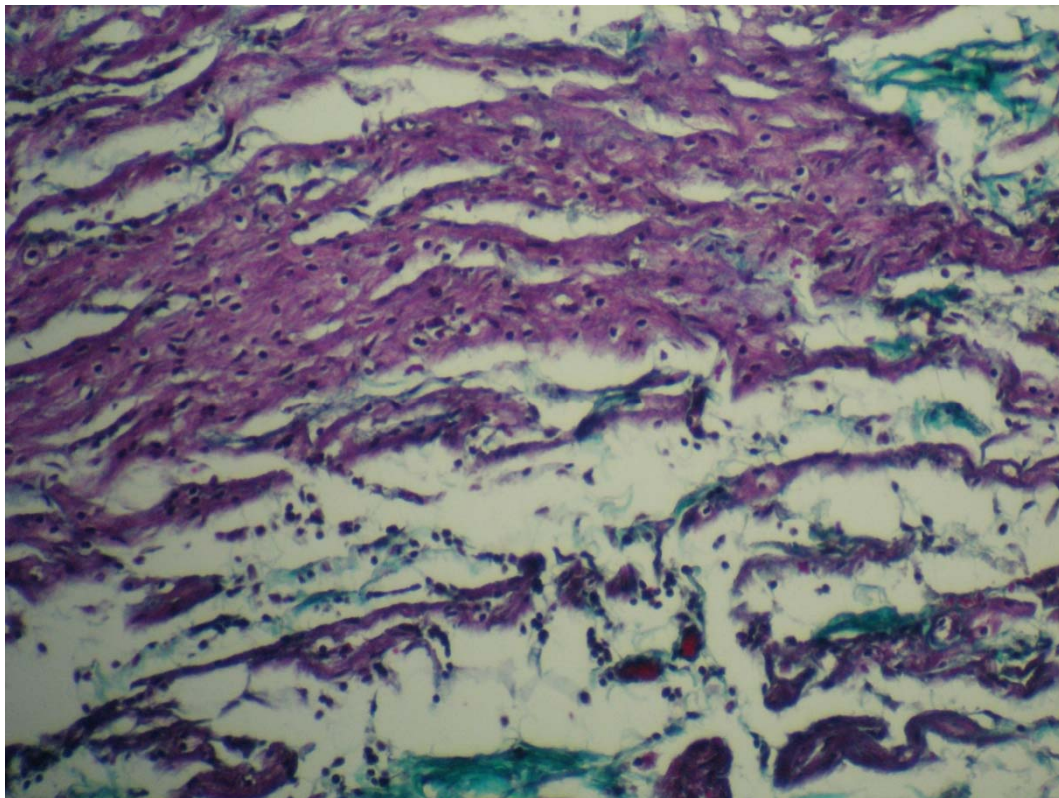
congested. There was moderate congestion in all kidneys with mild renal tubular necrosis in one case. Mild infiltration of mononuclear inflammatory cells was noted in portal areas of the liver with mild to moderate diffuse vacuolar changes in hepatocytes. Brains were congested in all animals and there was severe congestion and hemorrhage in gray matter of the spinal cord in one animal. Abomasums, small and large intestines showed mild congestion. There were not remarkable lesions in the rumen, spleen and urinary bladder.

Histopathological examination of cardiac conduction system revealed moderate to severe interstitial edema with inflammation of the SA-node and the AV-node, the bundle branches and the His-bundle in all cases (Fig 5). The inflammatory reaction occurred most severely in the AV-node and the His-bundle. The infiltrates contained abundant granulocytes, macrophages and lymphocytes. There were also degenerative changes with

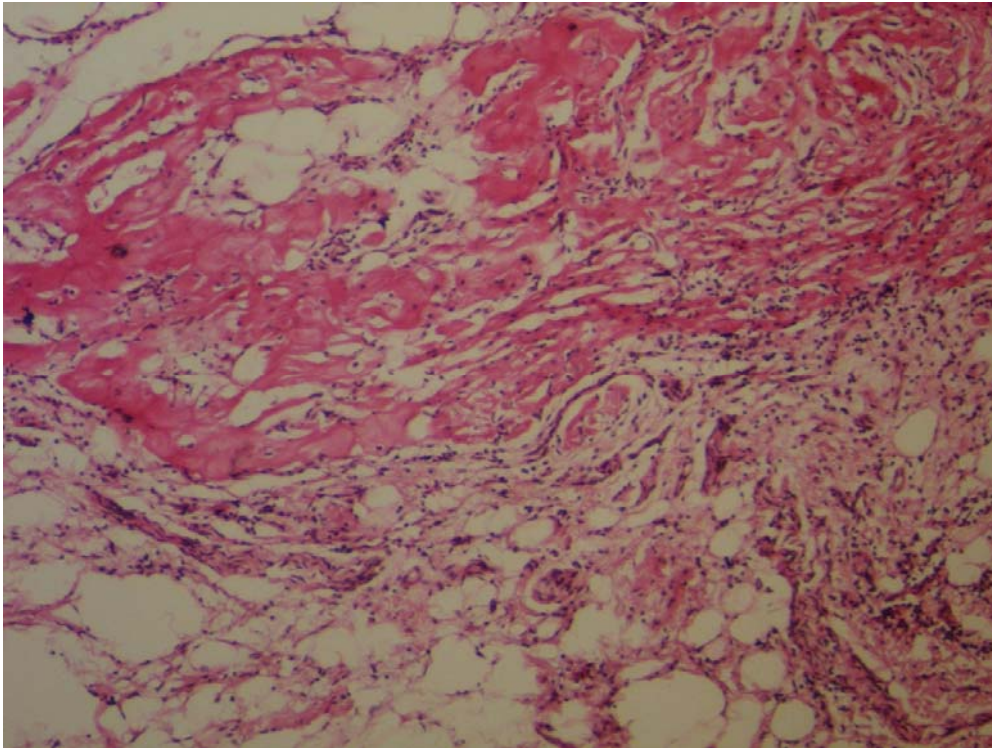
vacuole formation in affected AV-nodes and His-bundles (Fig 6). There was mild to moderate multifocal necrosis of cells in the AV-node of two animals. Inflammation and necrosis in either SA-node or AV-node were in continuation with that in the atrium in these animals. Other two cases showed swelled Purkinje fibers with heavy infiltration of inflammatory cells in interstitial connective tissue and around the nerve fibers.

### Discussion

Yew leaves, as powder given orally, were extremely toxic to sheep. The predominant signs of yew intoxication in sheep were different grades of cardiac conduction disturbances expressed by various cardiac arrhythmias which lead to death in 4 of 7 sheep. No significant abnormality was observed in other organs. Experimental induction of yew poisoning and detailed



**Figure 5.** SA-node shows interstitial edema and mild to moderate infiltration of mononuclear inflammatory cells. Masson's trichrome,  $\times 320$ .



**Figure 6.** AV-node shows interstitial edema and severe infiltration of mixed inflammatory cells. There is also marked degenerative changes in myocytes. Hematoxylin and Eosin,  $\times 160$

course of intoxication has not been reported in domestic animals. Sudden death is the commonest outcome of cardiotoxic effects of yew poisoning. Fatal animal toxicoses associated to yew ingestion have been reported in a wide variety of animals (Wilson and Hooser, 2007). The toxicity of yew for humans has also been known since antiquity. Its occurrence appears to be rare but death from severe cardiac disturbances is the most frequent outcome of intoxication (Yersin *et al.*, 1987; Van Ingen *et al.*, 1992; Willaert *et al.*, 2002; Veltmann *et al.*, 2009). The cardiotoxicity of *T. baccata* is based on pseudoalkaloids, which are found in all parts of the plant except for the red flesh of the berry. The major alkaloids are represented by taxines A and B. Taxine A and B accounts for 1.3% and 30% of the total alkaloid fraction extracted from *T. baccata* respectively. Taxine B is also more potent than other alkaloids and primary cardiotoxic effects of yew are a direct result of the activity of taxine B. (Wilson *et al.*, 2001). Pharmacokinetics of taxines have

not completely elucidated. However, it is believed that taxines are rapidly absorbed from gastrointestinal tract, metabolized through conjugation in the liver, and eliminated as conjugated benzoic acid and hippuric acid by the kidneys (Tiwary *et al.* 2005; Andersen, 2009; Lavoie and Hinchcliff, 2009). Rapid development of cardiac abnormalities following yew administration in sheep is consistent with that opinion.

It is suggested that taxine A and B inhibit the cardiac calcium channel and fast cardiac sodium channel which is resemble to action of class I and IV of antiarrhythmic agents respectively (Tekol and Kameyama, 1987; Tekol and GÖgusten, 1999). The sodium channel blockers bind to the transmembrane sodium channels and decrease the numbers available for depolarization. This creates a delay of sodium entry into the cardiac myocyte during phase 0 of depolarization and as a result, the upslope of depolarization is slowed and QRS complex widens (Holstege *et al.*, 2006). On the other hand, calcium channel



blockers inhibit the voltage sensitive L-type calcium channel within the cell membrane. The inhibition of this channel results a decrease of intracellular calcium within the myocardial cells which slowing of conduction, decreased contractility, and decreased cardiac output. Decreased cardiac output coupled with vasodilative effect of those drugs result in profound hypotension (Holstege *et al.*, 2006).

The interference of taxine alkaloids with potassium ion channels leading to hyperkalemia and absence of P wave in ECG has also been speculated (Andersen, 2009). Hyperkalemia was observed in 2 sheep of this study; however, it seems to be associated to hypotension and acidosis induced by yew poisoning (Yersin, *et al.*, 1987; Cummins *et al.*, 1990; Miller and Curry, 2000) rather than potassium channel blockage. Long QT interval that is a feature of potassium channel blockage (Holstege *et al.*, 2006) was not observed in this study.

The electrocardiographic features of yew intoxication in sheep were predominantly a mixture of calcium and sodium channel blockade, resembled to toxic effects of class I and IV of antiarrhythmic agents (Holstege *et al.*, 2006). Although hyperkalemia was not a consistent finding in serum biochemistry of sheep, there were some evidence of hyperkalemia, such as absence of P waves (Montague *et al.*, 2008), in some of ECG traces. These findings are similar to ECG records of human cases of yew intoxication (Yersin *et al.*, 1987; Van Ingen *et al.*, 1992; Veltmann *et al.*, 2009).

On the other hand, cellular and tissue damage of myocardium, particularly cardiac conduction system may have a role in the development of arrhythmias. Histological changes in the heart have been reported in an intoxicated horse, where multifocal contraction band necrosis of the ventricular wall and the papillary muscles were found (Tiwary *et al.*, 2005; Andersen, 2009). The pattern of contraction band necrosis was not observed in sheep as the same extent that has been reported in the horse (Tiwary *et al.*, 2005).

Gastrointestinal inflammation which has

been observed in yew intoxication of laboratory animals is thought to be caused by irritant effects of a long list of compounds in the yew such as nitriles, ephedrine and essential oils (Tekol, 1991). Inhibition of peristaltic movement of rabbit jejunum with taxin sulfate has also been reported (Tekol and GÖgusten, 1999). Decrease of ruminal movement in sheep of this study was clinically observed during the course of intoxication, but with the except for mucosal congestion there were no significant lesion in the pathology of gastrointestinal tract. Similar findings have been reported in horses that died due to intoxication with *T. baccata* or *T. cuspidate* (Karns, 1983; Tiwary *et al.*, 2005). Gastrointestinal tract lesions are not consistent findings in yew intoxicated animals because of the acute nature of the poisoning.

Elevated activity levels of serum AP, AST and ALT have been observed in an experiment with rats treated with yew extract for 30 days, indicating a toxic effect on the liver (Shanker *et al.*, 2002). Serum biochemistry in the present study did not show any significant changes in AST, AP, LDH and GGT activity, but there was a trend of significant elevation of serum troponin I concentration which is a reliable marker of myocardial damage in sheep as well as humans (Leonardi *et al.*, 2008). Elevation of serum sodium may also be an indication of sodium channel blockage during the course of yew intoxication.

One limitation of this study was that 4 sheep died before the proposal study endpoint of 48 hours, and because of the early drop out of these animals fully evaluation of the relationship between serum biochemical parameters particularly serum troponin I and yew intoxication was not possible.

In the present study, oral administration of dried leaves of *T. baccata*, collected from north of Iran, at the dose of 2.5g/kg showed acute toxicity and death in 4 of 7 sheep. A variety of cardiac arrhythmia was the main manifestation of intoxication and there were multifocal nonsuppurative interstitial myocarditis involving cardiac conduction system. In conclusion, north

Iranian *T. baccata* is highly toxic, causes cardiac arrhythmias and lesions with few serum biochemical changes. Although some aspects of acute yew intoxication were elucidated in this study, induction of subacute or chronic yew intoxication may reveal more details of the yew toxicity.

### Acknowledgement

The authors sincerely acknowledge the Assistant Dean for Research Affairs of Ferdowsi University of Mashhad for the financial support (Project No. 1238).

### References

- Alden C.L., Fosnaugh C.J., Smith J.B., Mohan R. (1977) Japanese yew poisoning of large domestic animals in the Midwest. *Journal of American Veterinary Medical Association* **170**, 314-316.
- Andersen K.B. (2009) Future perspectives of the role of taxines derived from the yew (*Taxus baccata*) in research and therapy. *Journal of Pre-Clinical and Clinical Research* **3**; 1-4.
- Aslani, M.R. (2005) Poisonous Plants of Iran and Their Effects on Animals. Ferdowsi University of Mashhad publication, Mashhad, pp 276-279.
- Bacciarini, L.N., Wenker, C.J., Müller, M., Iten, P. (1999) Yew (*Taxus baccata*) intoxication in a captive brown bear (*Ursus arctos*). *European Journal of Veterinary Pathology* **5**; 29-32.
- Cope, R.B., Camp, C., Lohr, C.V. (2004) Fatal yew (*Taxus sp*) poisoning in Willamette Valley, Oregon, horses. *Veterinary and Human Toxicology* **46**; 279-281.
- Cummins, R.O., Haulman, J., Quan, L., Graves, J.R., Peterson, D., Horan, S. (1990) Near-fatal yew berry intoxication treated with external cardiac pacing and digoxin-specific FAB antibody fragments. *Annals of Emergency Medicine* **19**; 38-43.
- Evans, K.L., Cooke, I.R. (1991) Japanese yew poisoning in a dog. *Journal of American Animal Hospital Association* **27**; 300-302.
- Handeland, K. (2008) Acute yew (*Taxus*) poisoning in moose (*Alces alces*). *Toxicon* **52**; 829-832.
- Hare W.R. (1998) Bovine yew (*Taxus spp.*) poisoning. *Large Animal Practice* **19**; 24-28.
- Holstege, C.P., Eldridge, D.L., Rowden, A.K. (2006) ECG manifestations: the poisoned patient. *Emergency Medicine Clinics of North America* **24**; 159-177.
- Itokawa, H., Lee, K.H. (2003) *Taxus*: The Genus *Taxus*. Tylor & Francis, London; pp 153-156.
- Karns, P.A. (1983) Intoxication in horses due to ingestion of Japanese yew (*Taxus cuspidata*). *Equine Practice* **5**: 12-15.
- Lacasse, C., Gamble, K.C., Poppenga, R.H., Farina, L.L., Landolfi, J., Terio, K. *Taxus sp.* intoxication in three Francois' langurs (*Trachypithecus francoisi*). *Journal of Veterinary Diagnostic Investigation* **19**; 221-224.
- Lavoie, J.P., Hinchcliff, K.W. (2009) Blackwell's Five Minute Veterinary Consult: Equine. 2<sup>nd</sup> Ed, Blackwell, Ames, p 156.
- Leonardi, F., Passeri, B., Fusari, A., Razza, P.D., Beghi, C., Lorusso, R., Corradi, A., Botti, P. (2008) Cardiac troponin I (cTnI) concentration in an ovine model of myocardial ischemia. *Research in Veterinary Science* **85**; 141-144.
- Maxie, G. (1991) Another case of Japanese yew poisoning. *Canadian Veterinary Journal* **32**; 370.
- Miller, M.B., Curry, E.J. (2000) Sodium bicarbonate for *Taxus*-induced dysrhythmia. *Journal of Toxicology and Clinical Toxicology* **38**; 572.
- Montague, B.T., Quелlette, J.R., Buller, G.K. (2008) Retrospective review of the frequency of ECG changes in hyperkalemia.

- Clinical Journal of American Society of Nephrology* **3**; 324-330.
- Panter, K.E., Molyneux, R.J., Smart, R.A., Mitchel, L., Hansen, S. (1993) English yew poisoning in 43 cattle. *Journal of American Veterinary Medical Association* **202**; 1476-1477.
- Parkinson, N. (1996) Yew poisoning in horses. *Canadian Veterinary Journal* **37**; 687.
- Radostits, O.M., Gay, C.C., Hinchcliff, K.W., Constable, P.D. (2007) *Veterinary Medicine*. 10<sup>th</sup> Ed. Saunders & Elsevier, Edinburg, p 408.
- Rae CA, Binnigton BD (1995) Yew poisoning in sheep. *Canadian Veterinary Journal* **36**; 446.
- Ruha, A.M., Tanen, D.A., Graeme, K.A., Curry, S.C., Miller, M.B., Gerkin, R., Reagan, C.G., Brandon, T.A. (2002) Hypertonic sodium bicarbonate for *Taxus* media-induced cardiac toxicity in swine. *Academic Emergency Medicine* **9**; 179-185.
- Shanker, K., Pathak, N.K.R., Trivedi, V.P., Chansuria, J.P.N., Pandey, V.B. (2002) An evaluation of toxicity of *Taxus baccata* Linn. (Talspatra) in experimental animals. *Journal of Ethnopharmacology* **79**; 69-73.
- Sufness, M. (1995) *Taxol: Science and Applications*. CRC Press, Boca Raton, pp 7/8-311/312.
- Taksdal T (1994) Diagnoses from the Norwegian State Veterinary Laboratory. *Norsk Veterinaertidsskrift* 106: 305-306
- Tekol, Y., Kameyama, M. (1987) Elektrophysiologische Untersuchungen über den Wirkungsmechanismus des Eibentoxins Taxin auf das Herz. *Arzneium Forschung* **37**; 428-431.
- Tekol, Y., Gő gusten, B. (1999) Comparative demonstration of the cardioselectivity of taxine and verapamil in the isolated aorta, atrium, and jejunum preparations of rabbits. *Arzneium Forschung* **49**; 673-678.
- Tekol, Y. (2007) The medieval physician Avicenna used a herbal calcium channel blocker, *Taxus baccata* L. *Phytotherapy Research* **21**; 701-702.
- Thomson, G.W., Barker, I.K. (1978) Japanese yew (*Taxus cuspidate*) poisoning in cattle. *Canadian Veterinary Journal* **19**; 320-321.
- Tiwary, A.K., Puschner, B., Kinde, H., Tor, E.R. (2005) Diagnosis of *Taxus* (Yew) poisoning in a horse. *Journal of Veterinary Diagnostic Investigation* **17**; 252-255.
- Van Ingen, G., Visser, R., Reltenburg, H., Van Der Ark, A.M., Voortman, M. (1992) Sudden unexpected death due to *Taxus* poisoning: A case report of five cases, with review of the literature. *Forensic Science International* **56**; 81-87;
- Veltmann, C., Borggreffe, M., Schimpf, R., Wolpert, C. (2009) Yew causes Brugada ECG. *Circulation* **119**; 1836-1837.
- Willaert, W., Claessens, P., Vankelecom, B., Vanderheyden, M. (2002) Intoxication with *Taxus baccata*: Cardiac arrhythmias following yew leaves ingestion. *Journal of Pacing and Clinical Electrophysiology* **25**; 511-512.
- Wilson, C.R., Sauer, J.M., Hooser, S.B. (2001) Taxins: a review of the mechanism and toxicity of yew (*Taxus* spp.) alkaloids. *Toxicol* **39**; 175-185.
- Wilson, C.R., Hooser, S.B. (2007) Toxicity of yew (*Taxus* spp.) alkaloids. In: *Veterinary Toxicology, Basic and Clinical Principles*, Ed Gupta, R.C., Elsevier, Philadelphia, pp 929-935.
- Yersin B, Frey JG, Schaller MD, Nicod P, Perret C (1987) Fatal cardiac arrhythmias and shock following yew leaves ingestion. *Annals of Emergency Medicine* **16**; 1396-1397.

## مطالعه درمانگاهی، آزمایشگاهی و آسیب شناسی مسمومیت تجربی با سرخه دار (*Taxus baccata*) در گوسفند

محمد رضا اصلانی<sup>۱</sup>، علیرضا تقوی رضوی زاده<sup>۱</sup>، احمد رضا موثقی<sup>۲</sup>، مهرداد مهری<sup>۱</sup>، ابوالقاسم نبی پور<sup>۳</sup>، علی رضاخانی<sup>۴</sup>، سمانه یعقوبی فاز<sup>۱</sup>، علی عندلیب مقدم<sup>۱</sup>، فاطمه احمدی<sup>۱</sup>

<sup>۱</sup>گروه علوم درمانگاهی دانشکده دامپزشکی دانشگاه فردوسی مشهد، مشهد، ایران  
<sup>۲</sup>گروه پاتوبیولوژی دانشکده دامپزشکی دانشگاه فردوسی مشهد، مشهد، ایران  
<sup>۳</sup>گروه علوم پایه دانشکده دامپزشکی دانشگاه فردوسی مشهد، مشهد، ایران  
<sup>۴</sup>گروه علوم درمانگاهی دانشکده دامپزشکی دانشگاه شیراز، شیراز، ایران  
<sup>۵</sup>قطب علمی مطالعه سقط جنین و مرگ و میر نوزادان نشخوارکنندگان

پذیرش نهایی: ۹۰/۴/۲۸

دریافت مقاله: ۹۰/۳/۲۸

### چکیده

گیاهان سرخه دار (گونه های تاکسوس) شدیداً سمی بوده و سمیت آنها برای انسان و دام ها از دیرباز شناخته شده است. مطالعه‌ی حاضر به منظور بررسی اثر سمی سرخه‌دار بر گوسفند صورت گرفت. در این مطالعه از ۷ رأس گوسفند ماده نژاد بلوچی با سن ۳-۲ سال و وزن ۳۴-۴۷ کیلوگرم استفاده شد. در روز شروع مطالعه پس از اخذ یک نمونه خون حاوی EDTA (جهت خون شناسی) و یک نمونه خون بدون EDTA (جهت جداسازی سرم)، پودر گیاه سرخه‌دار به میزان ۲/۵ گرم به ازای هر کیلوگرم وزن بدن در آب حل شده و با لوله معدی به گوسفندان تجویز شد. سایر نمونه‌های خون در ساعات ۴، ۸، ۱۲، ۲۴، ۲۸، ۳۲، ۳۶ و ۴۸ پس از تجویز گیاه اخذ شد. همچنین در زمان های ذکر و در فواصل آنها الکتروکاردیوگرام به روش راسی - قاعده ای از دام های مورد آزمایش اخذ گردید. در نمونه‌های خون کامل میزان PCV، پروتئین تام، فیبرینوژن، شمارش کامل و شمارش تفریقی گلبول‌های سفید و در نمونه‌های سرمی میزان AST، GGT، ALP، CK، LDH، تروپونین I، BUN، کراتینین و الکترولیت‌های سدیم، پتاسیم، کلسیم، منیزیم و فسفر اندازه گیری شد. در بررسی داده‌های به دست آمده با نرم افزار SPSS، تغییرات معنی‌داری در تعداد ضربان قلب، تعداد تنفس، تعداد حرکات شکمبه، تعداد کل گلبول‌های سفید خون، تعداد مطلق نوتروفیل‌های بالغ خون، میزان BUN و میزان سدیم سرم نسبت به زمان صفر در نمونه‌های مورد آزمایش مشاهده شد. الکتروکاردیوگرام‌های اخذ شده طیفی از آریتمی‌های قلبی از جمله تاکی کاردی بطنی چند کانونی، ریتم ادیوونتریکیولار و ادیوژانکشنال و پهن شدن امواج QRS و T را نشان داد. چهار رأس از گوسفندان مورد آزمایش به فاصله ۱۶-۳ ساعت پس از تجویز گیاه تلف شدند. کالبد گشایی این دام‌ها با توجه ویژه به میوکارد و سیستم هدایتی آن صورت گرفت. در این موارد پرخونی، خونریزی کانونی، تغییرات دژنراتیو پراکنده و نکروز انعقادی کانونی سلول‌های میوکارد بطن‌ها مشاهده شد. هیستوپاتولوژی سیستم هدایتی قلب نیز ادم متوسط تا شدید همراه با آماس را در گره سینوسی - دهلیزی، گره دهلیزی - بطنی و شاخه‌های باندل و دسته‌ی هیس را نشان داد که تغییرات مذکور در گره دهلیزی - بطنی و دسته‌ی هیس شدیدتر بود.

تجویز خوراکی برگ‌های خشک سرخه‌دار با دز ۲/۵ گرم برای هر کیلوگرم وزن بدن در گوسفند موجب شکل‌گیری مسمومیت حاد شده که از نظر درمانگاهی یا طیفی از آریتمی‌های قلبی و در آسیب شناسی با ضایعات میوکارد و از جمله سیستم هدایتی قلب همراه بود. بیماری توکسوپلاسموز که بوسیله تک یاخته توکسوپلازما گوندی (*T. gondii*) ایجاد می‌شود، بدلیل ایجاد مرگ زودرس جنین، مومیایی شدن، سقط، مرده زایی و مرگ و میر نوزادان، از اهمیت اقتصادی زیادی در دام‌های اهلی و بویژه در گوسفند و بز برخوردار است.

**واژگان کلیدی:** سرخه دار، گوسفند، آریتمی قلبی، سیستم هدایتی قلب، مسمومیت گیاهی، *Taxus baccata*