

## Occurrence of Ventricular Candidiasis in a Lovebird (*Agapornis fischeri*)

Mohsen Nouri <sup>1\*</sup> and Zahra Kamyabi <sup>2</sup>

<sup>1</sup> Private Veterinary Practitioner, Tehran, Iran

<sup>2</sup> Department of Pathobiology, Faculty of Veterinary Medicine, University of Tehran, Tehran, Iran

Received: June 20, 2010

Accepted: August 13, 2010

### Abstract

A young Fisher's lovebird (*Agapornis fischeri*), showed clinical symptoms with general weakness, diarrhea, ruffled feathers and unilateral extrarhinoectasia and died finally. Gross necropsy revealed marked edema, congestion and hemorrhage on the distal part of the gizzard and proximal part of the duodenum. On microscopic examination, a large number of oval budding yeast-like fungi were observed in a stained smear sample from the gizzard and duodenum by the Giemsa method. Histopathologically, there was epithelial necrosis in the proventriculus and gizzard and inflammation of the proximal intestine. The pseudohyphae and budding yeast-like organisms were most numerous on the surface and extended deep into the submucosa and muscularis layer. Severe hemorrhage, vasculitis with invasion of fungal organisms into the vessels' wall associated with infiltration of inflammatory cells were observed. The disease was diagnosed as candidiasis in the middle part of digestive tract.

**Keywords:** lovebird, candidiasis, moniliasis, gizzard, duodenum

---

\* Corresponding author: Mohsen Nouri  
E-mail address: mnouri2@yahoo.com  
P. O. Box 14195-181, Tehran, Iran

## Introduction

Candidiasis, also called moniliasis or thrush, is caused by a yeast-like fungus, *Candida albicans*. Avian candidiasis of the digestive tract is considered to be rare (Carrasco *et al.*, 1998), since it is difficult to diagnose clinically in many cases. According to reviews of avian candidiasis, serious outbreaks have been recorded in chickens and turkeys, and also in cage birds such as budgerigars, lovebirds, pigeons, cockatiels, Amazon parakeets and peacocks (Mayeda, 1961; Panigrahy, 1979; Carrasco *et al.*, 1993; Chute, 1997; Carrasco *et al.*, 1998; Sato *et al.*, 2001). The condition is principally a superficial mycosis of mucous membranes (white pseudomembranes) affecting the upper digestive tract such as mouth, esophagus and crop. These pseudomembranes are easily removed, leaving ulcer-like foci (Chute, 1978; Jones and Hunt, 1983; Sato *et al.*, 2001; Silvanose, 2008). As with other deep-seated mycoses, the diagnosis was usually confirmed by histopathologic examinations (Carrasco *et al.*, 1998). Mechanical impairment of swallowing, poor growth, lethargy and roughness of feathers are commonly reported clinical signs in active cases of candidiasis (Redig, 1978; Sato *et al.*, 2001). In chronic cases tongue rot and enteritis are also observed (Silvanose, 2008).

To the authors' knowledge, there is no published report on candidiasis in the middle digestive tract in lovebird. This case appears to be the first reported case of ventricular candidiasis in a Fisher's lovebird.

## Case Presentation

A young Fisher's lovebird was presented to a private veterinary practitioner with a history of general weakness, diarrhea, progressive emaciation, and ruffled feathers of several days' duration in May, 2008. The nares were also asymmetric. The left nare wasn't rounded normally which extended from the cere area down the beak (unilateral extrarhinoectasia). The bird was medicated with enrofloxacin solution and vitamin complex drop orally in the drinking

water. Despite treatment with enrofloxacin, the bird died four days later.

## Results

Gross necropsy revealed marked edema, congestion and hemorrhage on the distal part of the gizzard and proximal part of the duodenum (Fig. 1). Moderate numbers of ulcer-like lesions were observed on the proventricular epithelium.

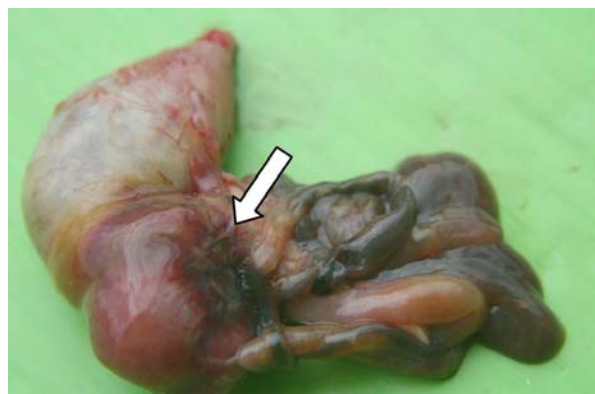

Figure 1: Marked edema, congestion and hemorrhage on the distal part of the gizzard and proximal part of the duodenum (white arrow).

Fresh wet smear samples and imprint smear samples from the gizzard and duodenum were stained by the Giemsa and Gram methods, and examined microscopically. Many oval budding yeast-like fungi were seen. No bacteria and fungi from the liver, heart, spleen, lungs and kidneys were isolated. Collected specimens of the gizzard, proventriculus, liver, spleen, heart, lungs, kidneys, and intestines were preserved in 10 % neutral buffered formalin and sent to the pathology laboratory. Tissue sections were prepared by routine histological methods and stained with hematoxylin and eosin (H & E), and Periodic Acid-Schiff (PAS).

On microscopic examination, there was epithelial necrosis in the proventriculus and gizzard and inflammation of the proximal part of the intestine. There were mycelia of a fungus-like microorganism in cellular debris surrounded by giant cells, macrophages, lymphocytes and fibrous tissue. The organism was recognized by masses of entangled

pseudohyphae and budding yeast-like organisms. The fungi were most numerous on the surface and extended deep into the submucosa and muscularis layer (Fig. 2). Severe hemorrhage, vasculitis with invasion of fungal organisms into the vessels' wall associated with infiltration of inflammatory cells was observed. The inflammatory cells were primarily heterophils, macrophages, and lymphocytes. The fungal organisms stained positively with the Periodic Acid-Schiff technique.

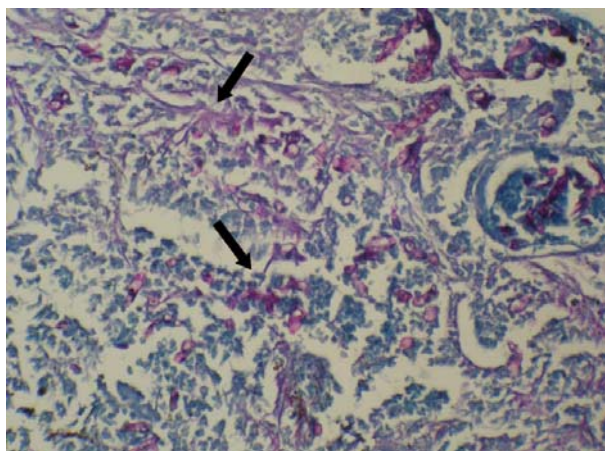


Figure 2: Numerous fungal organisms are evident in the muscular layer of the gizzard. PAS  $\times 640$ .

## Discussion

Infections of *Candida* spp. are found commonly in the oral cavity and gastrointestinal tract of normal animals, and usually induce disease only when the host is rendered vulnerable by some predisposing condition (Robbins and Cotran, 1979; Bangert, 1988; Silvanose, 2008). The infection is generally regarded as an opportunistic infection. Some authors indicate that *C. albicans* is both commensal and pathogenic (Robbins and Cotran, 1979). No viral isolations were done. Therefore, ventricular candidiasis should be explored as a clinical disease. The clinical course of candidiasis is well documented in domestic and captive wild birds (Mayeda, 1961; Crispin and Barnett, 1977; Redig, 1978; Sato *et al.*, 2001; Silvanose, 2008). Slow growth, lethargy, and roughness of feather

coats are the usual clinical signs. Clinical signs that were detected in this bird were nonspecific and included general weakness, diarrhea, progressive emaciation, and ruffled feathers. The condition is principally a superficial mycosis of mucous membranes affecting the mouth, esophagus, crop, and proventriculus (Jones and Hunt, 1983; Sato *et al.*, 2001; Silvanose, 2008). Although the fungal pseudomembranes are recognized commonly in visible parts of the nasal cavity and alimentary tract of domestic and some captive wild birds with candidiasis (Chute, 1978; Redig, 1978; Sato *et al.*, 2001; Tsai *et al.*, 1992), in our experience, no such gross lesion has been recognized in the nasal cavity, mouth, crop and lung. In this case, extrarhinoectasia provided presumably more susceptibility to the disease, since the air passes through choana which probably fungi can access into the digestive system, continually.

Histopathologically, there was epithelial necrosis in the proventriculus and gizzard and inflammation of the proximal part of the intestine. The fungi were most numerous on the surface and extended deep into the submucosa and muscularis layer. The koilin lining of the ventriculus is unique and may possibly have characteristics that are conducive to the growth of *Candida* spp. (Patt and Patt, 1969).

Since ventricular candidiasis was the only lesion seen in this case, the possibility of a toxin produced by the fungus as a cause of death must be considered. Toxins capable of killing mice and rabbits have been isolated from *Candida* spp. (Simonetti and Strippoli, 1973; Chute, 1978). Yeast and fungal infections may constitute a major problem in aviary birds. The predisposing causes in birds were suggested vitamin A deficiency, humid weather, social needs, prolonged antibiotic therapy, over-crowded environment, delayed crop emptying and inadequate sanitation of hand-feeding utensils (Mayeda, 1961; Chute, 1978; Robbins and Cotran, 1979; Jones and Hunt, 1983; Hubbard *et al.*, 1985; Rich, 2003;

*Silvanose*, 2008; Nash, 2010). The lovebird in our study might be under stress because of aforementioned factors. All these reports suggest that candidiasis cannot be explained by infection with *C. albicans* alone. However, candidiasis must consider as a primary pathogen when the bird's resistance was lowered by environmental stress.

*Trichomonas* is one of the most common protozoan diseases in young cage birds (Baker, 1986; Narcisi *et al.*, 1991; Sato *et al.*, 2001). Trichomoniasis in birds usually shows caseous lesions in the upper digestive tract (McDougald, 1991; Sato *et al.*, 2001), which are quite similar to those of candidiasis (Sato *et al.*, 2001; Chute, 1997). However, the organism was not detected in the lesions of the present case and typical lesions of trichomoniasis were not observed histopathologically. Also submucosal inflammatory response is seen in trichomoniasis (Baker, 1986; McDougald, 1991; Narcisi *et al.*, 1991; Sato *et al.*, 2001). The order Mucorales is unique in that the hyphae are nonseptate or rarely septate. Such infections are uncommon and usually associated with an underlying disease condition (Schmidt *et al.*, 2003).

In conclusion, extrarhinoectasia presumably provided the bird more susceptible to the disease. Therefore, candidiasis must consider as a primary pathogen in stressed birds. If the possibility of candidiasis is detected, appropriate management and therapeutic measures can be taken that may aid to eliminate the disease.

## References

- Baker, J.R. (1986) Trichomoniasis, a major cause of vomiting in budgerigars. *Veterinary Record* **118**, 447-449.
- Bangert, R.L., Cho, B.R., Widders, P.R., Stauber, E.H. and Ward, A.C. (1988) A survey of aerobic bacteria and fungi in the feces of healthy psittacine birds. *Avian Disease* **32**, 46-52.
- Carrasco, L., Bautista, M.J., Mulas, J.M. and Jensen, H.E. (1993) Application of Enzyme Immunochemistry for the Diagnosis of Aspergillosis, Candidiasis, and Zygomycosis in Three Lovebirds. *Avian Disease* **37**, 923-927.
- Carrasco, L., Gomez-Villamandos, J.C. and Jensen, H.E. (1998) Systemic candidosis and concomitant aspergillosis and zygomycosis in two Amazon parakeets (*Amazona aestiva*). *Mycoses* **41**, 297-301.
- Chute, H.L. (1978) *Diseases of Poultry*, 7th edn., Iowa State University Press, Ames, Iowa.
- Chute, H.L. (1997) *Diseases of Poultry*, 10th edn., Iowa State University Press, Ames, Iowa.
- Crispin, S.M. and Barnett, K.C. (1977) Ocular candidiasis in ornamental ducks. *Avian Pathology* **7**, 49-59.
- Hubbard, G.B., Schmidt, R.E., Eisenbrandt, D., L., Witt, W.M. and Fletcher, K.C. (1985) Fungal Infections of Venticuli in captive birds. *Journal of Wildlife Disease* **21**, 25-28.
- Jones, T.C.A. and Hunt, R.D. (1983) *Veterinary Pathology*, 5th edn., Lea and Febiger, Philadelphia, Pennsylvania.
- Mayeda, B. (1961) Candidiasis in turkeys and chickens in the Sacramento Valley of California. *Avian Disease* **5**, 232-243.
- McDougald, L.R. (1991) *Diseases of Poultry*, 10th edn., Iowa State University Press, Ames, Iowa.
- Narcisi, E.M., Sevoian, M. and Honigberg, B.M. (1991) Pathologic changes in pigeons infected with a virulent *Trichomonas*

- gallinae strain (Eiberg). *Avian Disease* **35**, 55-61.
- Nash, H. (2010) Candidiasis in birds: Signs, Treatment, and Prevention of Yeast Infections in Birds. <http://www.peteducation.com/article.cfm>.
- Panigrahy, B., Naqi, S.A., Grumbles, L.C. and Hall, C.F. (1979) Candidiasis in Cockatiel Nestlings and Mucormycosis in a Pigeon. *Avian Disease* **23**, 757-760.
- Patt, D.I. and patt, G.R. (1969) *Comparative Vertebrate Histology*, Harper and Row, New York.
- Redig, P. (1978) *Zoo and Wild Animal Medicine*, W. B. Saunders, Philadelphia, Pennsylvania.
- Rich, G.A. (2003) Syndromes and Conditions of Parrotlets, Pionus Parrots, Poicephalus, and Mynah Birds. *Seminars in Avian and Exotic Pet Medicine* **12**, 144-148.
- Robbins, S.L. and Cotran, R.S. (1979) *Pathologic Basis of Disease*, 2nd edn., W. B. Saunders Company, Philadelphia, Pennsylvania.
- Sato, Y., Aoyagi, T., Kobayashi, T. and Inoue, J. (2001) Occurrences of candidiasis in a Fischer's love bird and a Budgerigar. *Journal of Veterinary Medical Science* **63**, 939-941.
- Schmidt, R.E., Reavill, D.R. and Phalen, D.N. (2003) *Pathology of pet and aviary bird*, Wiley-Blackwell, Ames, Iowa.
- Silvanose, C.H. (2008) *Avian Medicine*, 2nd edn., Mosby, London.
- Simonetti, W. and Strippoli, V. (1973) Pathogenicity of the Y form to M form in experimentally induced *Candida albicans* infections. *Mycopathology and Mycology Applied* **51**, 19-28.
- Tsai, S.S., Park, J.H., Hirai, K. and Itakura, C. (1992) Aspergillosis and Candidiasis in psittacine and passeriforme birds with particular reference to nasal lesions. *Avian Pathology*, **21**, 699-709.

## رخداد کاندیدیازیس سنگدان در یک طوطی کوتوله فیشری

محسن نوری<sup>۱</sup>، زهرا کامیابی<sup>۲</sup>

دامپزشک بخش خصوصی، تهران، ایران  
گروه پاتوبیولوژی، دانشکده دامپزشکی دانشگاه تهران، تهران، ایران

پذیرش نهایی: ۱۹/۵/۲۲

دریافت مقاله: ۱۹/۳/۳۰

### چکیده

یک مرغ عشق فیشری نابالغ نشانه‌های بالینی همچون ضعف عمومی، اسهال، ژولیدگی پرها و اتساع سوراخ خارجی بینی را از خود نشان داد و سپس تلف شد. یافته‌های پاتولوژی ادم، احتقان و خونریزی شدیدی را در ناحیه پایینی سنگدان و ناحیه بالایی دوازدهه نشان داد. در رنگ آمیزی گیمسا، آتاری از قارچ‌های مخمری شکل در حال جوانه زدن از نمونه اسمیر تهیه شده از دوازدهه و سنگدان مشاهده شد. در نمای ریزینی، نکروز سطح پوششی سنگدان و پیش معده به همراه التهاب و آماس بخش بالایی دوازدهه مشاهده شد. هایفه‌های کاذب و ارگانیسم‌های شبه مخمری در حال جوانه زدن در سطح و عمق تا لایه‌های عضلانی و زیرمخاط حضور داشتند. خونریزی شدید، التهاب عروق به همراه تهاجم ارگانیسم‌های قارچی به دیواره عروق و ارتشاح سلول‌های آماسی قابل مشاهده بود. این بیماری تحت عنوان کاندیدیازیس در ناحیه میانی دستگاه گوارش تشخیص داده شد.

**واژگان کلیدی:** مرغ عشق، کاندیدیازیس، مونیلیازیس، سنگدان، دوازدهه