



## Radiological and Anatomical Features of the Skull Bones of Adult Husky Dogs

Saman Ahani<sup>a</sup>, Siamak Alizadeh<sup>b</sup>, Mohammad Reza Hosseinchi<sup>c</sup>

<sup>a</sup> Doctor of Veterinary Medicine, Karaj Branch, Islamic Azad University, Karaj, Iran.

<sup>b</sup> Department of Clinical Sciences, Naghadeh Branch, Islamic Azad University, Naghadeh, Iran.

<sup>c</sup> Department of Basic Sciences, Urmia Branch, Islamic Azad University, Urmia, Iran.

### ABSTRACT

Considering the role of skull bones in preserving vital organs, paying close attention to the shape and size of the skull is of great importance when various conditions, such as head trauma, are suspected. However, in order to confirm the suspicion radiologically, examiners need to have detailed information on the normal skull characteristics of each breed. This study aimed to evaluate the radiological and anatomical features of the skull in adult Husky dogs. The current descriptive cross-sectional study examined eight adult Husky dogs (four males and four females) that died due to different conditions, excluding those of the head. After the preparation of the skulls, radiographs were obtained on different views. In addition, the bones were examined in terms of morphological characteristics. Morphometric indices were also measured and the results were recorded. Based on the results of this study, the skull of Husky dogs consists of 11 cranial bones (Ossa cranii), and 21 facial bones (Ossa faciei). Three parameters, including the height and the length of tympanic bullae as well as the orbital index, were greater in females compared to males. However, the differences were not significant. Other parameters were greater in male dogs. The whole skull length and maximum width of the skull showed significant differences between the two genders ( $p \leq 0.05$ ). The precise standards obtained in the current study can be used in interpreting the results to determine whether the presenting characteristics are abnormal or breed-dependent.

### Keywords

Radiology, Anatomy, Dog, Husky, Skull

Number of Figures: 12  
Number of Tables: 1  
Number of References: 27  
Number of Pages: 12

### Abbreviations

CT: Computed Tomography

TBH: Greatest height of the tympanic bulla

TBL: tympanic bulla length

WSL: Whole skull length

MWS: Maximum width of the skull

## Introduction

A variety of diseases, ranging from congenital to acquired ones, can affect the shape and size of the skull in dogs. Considering the importance of organs encased in the skull, such as the brain, changes in the architecture of this region are highly probable to be clinically significant [1]. This obligates examiners to pay close attention to the shape and size of the skull. However, owing to anatomical breed variations in dogs, it is not feasible to precisely realize whether the presenting shape of the skull is abnormal or breed-dependent unless there are thorough measurements of specific characteristics of each breed to serve as standards when needed [2]. Although different studies have examined skull morphology in Tarsus Çatalburun [3], Saarloos wolfdog [4], grey wolf [5], Lynx [6], red fox [7], vulpes [8], or golden jackals [9], no published article has studied that of Husky dogs.

Husky is known as a medium-sized, thickly furred, double-coated dog. It has erect triangular ears and distinctive markings on the head and has inherited the well-developed frontal sinuses of wolves, which is a useful way of distinguishing their skull from coyotes and foxes [10].

When skull examination is considered, CT is normally the modality of choice and helps operators to best appreciate subtle changes, such as small fractures [11]. This is mainly because of omitting the superimposition of the complex anatomy of the skull in CT [12]. However, despite its merits, CT is not usually available in all medical centers. Therefore, considering the ubiquity of radiology machines, radiography usually remains the only available choice in many medical centers at the time of this study.

The current research was conducted to investigate the radiological and anatomical features of the skull bones of adult Husky dogs.

## Results

### *Morphological results*

The skull of a Husky dog is composed of two parts: ossa cranii and ossa faciei. A total of 32 bones, including 11 cranial bones (three odd and four even bones) and 21 facial bones were assessed. Ossa cranii consisted of occipital, sphenoid, ethmoid, interparietal, parietal, frontal, and temporal bones. Facial bones consisted of maxilla, incisive, palatine, pterygoid, nasal, lacrimal, zygomatic, turbinate, mandible, vomer, and hyoid bones (Figure 1).

### *Cranial bones*

**Occipital bone:** The whole nuchal surface of the skull was composed of occipital bone. This bone par-

ticipates in the formation of the cranial surface and regions of the skull and contains a condyloid canal. Two short jugular processes were positioned on the sides of the condyles and hypoglossal canal. Muscular tubercles were also present. The intraparietal bone was completely joined with the nuchal bone and formed the interparietal process. The nuchal crest was relatively eminent and muscular prints were observable. The mastoid foramen was located on the caudal surface of the bone. The foramen magnum was relatively big and circular (Figure 1).

**Sphenoid bone:** There was more than one ethmoid foramen on the sphenoid bone. Round foramen was located on the alar canal and in the dorsal and internal parts of the alar canal. Oval foramen was observed in the caudal alar foramen. Spinous foramen was jointed with oval foramen.

**Ethmoid bone:** This bone was composed of three regions: the cribriform plate, crista galli, and ethmoidal fossa. Two ethmoidal foramina were seen on the sides of the plates and the optic canal. Cribriform plate had small foramina. A perpendicular plate was located between the nasal crest and crista galli. Lateral masses were positioned in the sides of the nose and composed of bone screws.

**Interparietal bone:** This bone was observed in the interparietal process jointed with the occipital bone (Figure 2).

**Parietal bone:** The results showed that this bone formed the major part of the skull. It has squamous, nasal, orbital, and temporal parts, as well as the zygomatic process. However, it did not contain supraorbital foramen. The zygomatic process was small and the frontal process was not jointed with the zygomatic bone. Two ethmoid foramina were observable in the frontal bone and on the edge of the sphenoid bone.

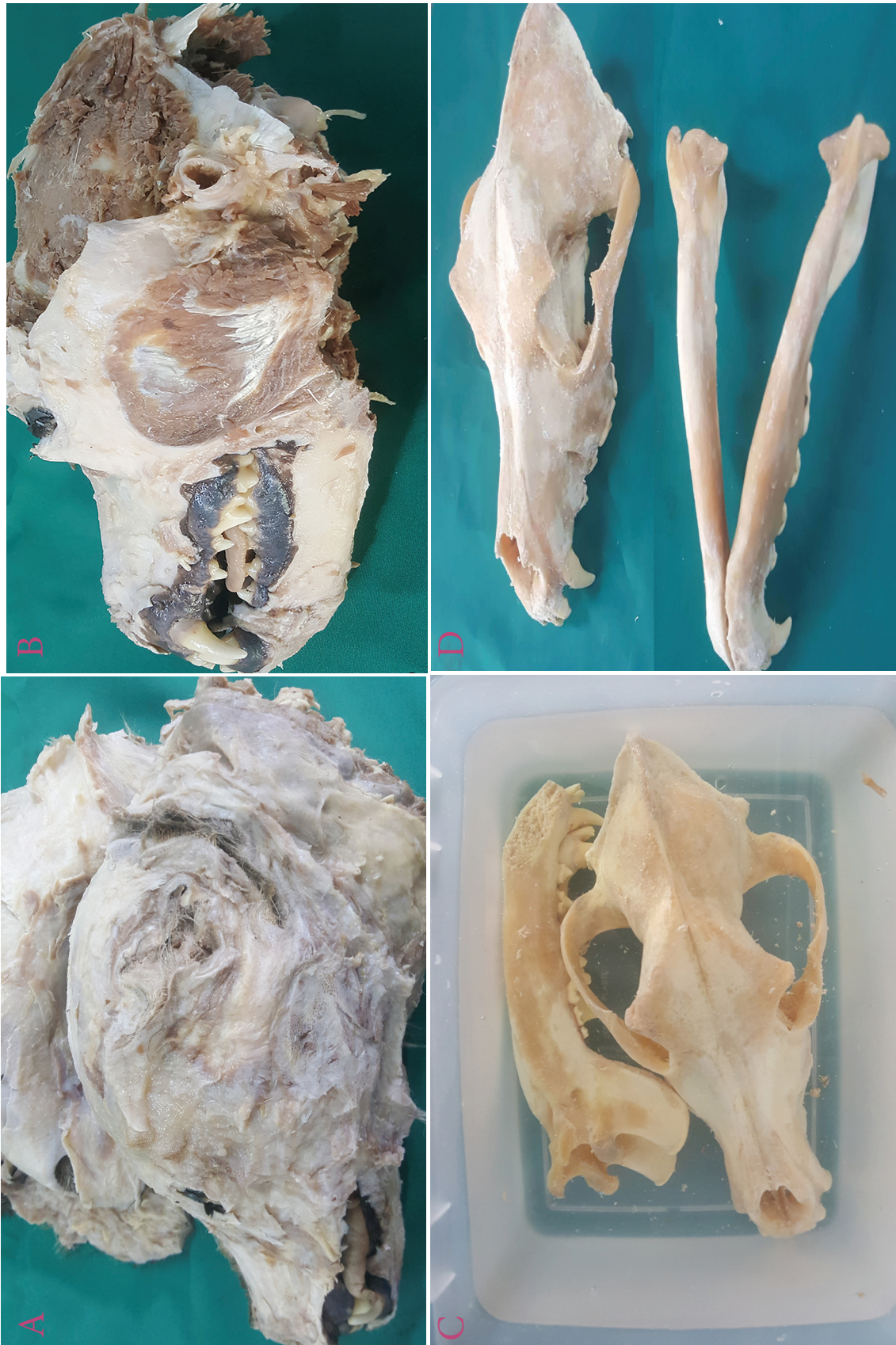**Frontal bone:** It took part in the formation of orbits and had no special breed traits.

**Temporal bone:** This bone is composed of three parts; the tympanic part is located ventrally and comprises tympanic bullae. The squamous part possessed a zygomatic process which was jointed to the zygomatic bone and formed the zygomatic arc. No articular tubercle was found on this part. The mastoid process was located dorsally on the petrous part of the temporal bone.

### *Facial bones*

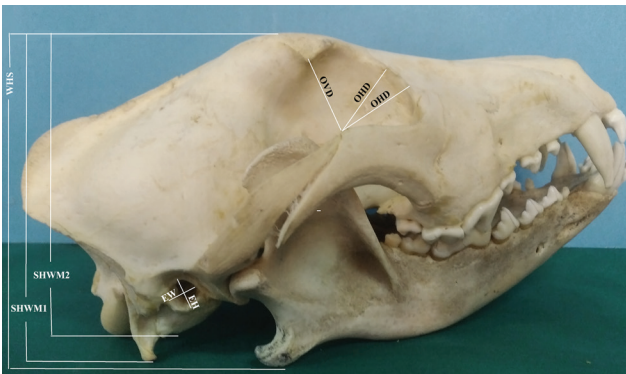
**Maxillary bone:** On this bone, the facial crest and facial tuber were not detectable. The infraorbital foramen was located in the upper section of the third premolar teeth. Maxilla had frontal processes connected to the frontal bone. The alveolar process had cavities for premolar and molar teeth. The palatine process was jointed with the median palatine suture. Palatine bone





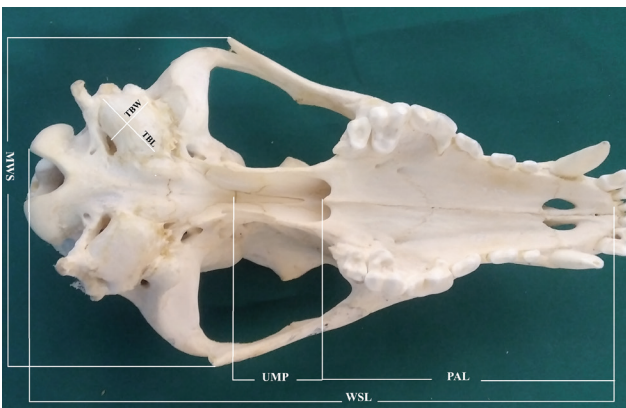
**Figure 1.** Oblique lateral view of adult male husky dog skull. Parietal bone (P), Temporal bone (T), Frontal bone (F), Premaxilla bone (pM), Lacrimal bone (L), Maxilla bone (M), Zygomatic bone (Z), Zygomatic process of temporal bone (ZpT), Temporal process of zygomatic bone (TpZ), Zygomatic process of frontal bone (ZpF), Coronoid process (crp), Condylod process (cnp), Angular process (ap), Ramus of mandible (rM), Body of mandible (bM), External acoustic meatus (eam), Jugular process (jp), Occipital condyle (Oc), Mastoid foramen (maf), external sagittal crest (esc), Incisive teeth (iT), Canine tooth (cT), Premolar teeth (pT1-4), Molar teeth (mT1-3).





**Figure 2.** Ventral view of adult female husky dog skull. Foramen magnum (fm), Jugular process (jp), Occipital condyle (Oc), tympanic bulla (tb), Basilar part of occipital bone (bO), zygomatic arch (Za), Basisphenoid bone (bs), Presphenoid bone (pS), Perpendicular part of palatine bone (pP), Horizontal part of palatine bone (hP), palatine process of maxilla (pM), Incisive teeth (iT1-3), Canine tooth (cT), Premolar teeth (pT1-4), Molar teeth (mT1-2).

and palatine process of the maxilla and also transverse palatine suture were observed. The ventral surface of the palatine process and palatine groove were seen within the major palatine foramen (Figure 3).



**Figure 3.** Dorsal view of adult male husky dog skull. Parietal bone (P), Temporal bone (T), Frontal bone (F), Premaxilla bone (pM), Nasal bone (N), Maxilla bone (M), Zygomatic bone (Z), Zygomatic process of temporal bone (ZpT), zygomatic arch (Za), Zygomatic process of frontal bone (ZpF), external sagittal crest (esc).

**Incisive bone:** The body of incisive bone was formed as a thin palate with three alveoli for upper incisive teeth. Processes nasalis was observed jointed with nasal bone. The nasal process was well extended. The palatine process was formed as thin plates in the rostral part of the hard palate. Incisive sutures and palatine fissures were also observable in this region.

**Palatine bone:** It was formed by 33% of the length of the hard palate and formed the caudal part of this bone. The vertical plate of the bone participated in the formation of the lateral wall of the nasal foramen. The vertical palate was curved in the most ventral part toward the pterygoid process of the palatine bone.

**Pterygoid bone:** This bone was located lateral to

the caudal foramen of the nasal bone. It terminated in the hock part of the hamulus.

**Nasal bone:** This bone formed the major part of the nasal cavity and its terminal part was concave in shape. Between nasal cavities were intranasal suture, nasal bone, and incisive bones.

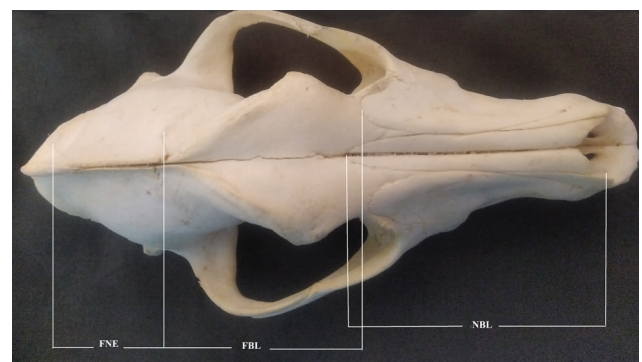**Lacrimal bone:** This bone was located in the frontal part of the orbital part. The bone was in contact with the frontal, palatine, maxilla, and zygomatic bones.

**Zygomatic bone:** This bone was positioned between the lacrimal bone and the maxilla. The bone participated in the formation of orbit parts. The temporal process of the zygomatic bone was jointed with the zygomatic process of the temporal bone, forming the zygomatic arch.

**Vomer bone:** The bone was positioned in the bottom of the nasal cavity as the septal sulcus. The bone was located in the distance with the nasopharyngeal meatus.

**Turbinate bones:** They were in the form of helix. Different parts of these bones were attached to their adjacent walls laterally.

**Mandible bone:** The Mandible was the largest facial bone and jointed with temporal condyles. Its ventral part was convex in shape. The alveolar border of the incisive part was composed of three alveoli for incisive teeth and one alveolus for canine teeth. The molar part had seven cavities for molar and premolar teeth. The external part of the mandible and its border had more than a mental foramen. In the perpendicular section, the mandibular canal was seen. Masseteric fossi were also observed as depressions on the ramus of the mandible. Mandibular foramen was terminated in mandibular canal. The articular extremity on the perpendicular section of the mandible had a coronoid process, condylar process, and mandibular notch. The angle of the mandible had an angular process (Figure 4).



**Figure 4.** Lateral view of adult male husky dog mandible. Coronoid process (crp), Condylar process (cnp), Angular process (ap), Ramus of mandible (rM), Body of mandible (bM), Mental foramen (mf) (arrow). Incisive teeth (iT), Canine teeth (cT), Premolar teeth (pT1-4), and Molar teeth (mT1-3).

Hyoid bone: This bone was jointed with the styloid process of the temporal bone. It had basihyoid, thyrohyoid, ceratohyoid, epihyoid, and stylohyoid parts.

The results in Table 1 show that TBH, TBL, and orbital indices were higher in female dogs compared to male dogs; however, the differences were not significant. All other parameters were higher in male dogs, among which WSL and MWS had significant differences ( $p \leq 0.05$ ).

### Radiological results

Graphs taken in the dorsoventral position showed that the ethmoidal fossa, frontal sinus, brain cavity, external auditory canal, and tympanic bulla were detectable. Occipital bone was observable ventral to the nuchal bone. Ethmoid bone was located between the cranial cavity and nasal region, yet their foramina were not detectable. The bone was fused with pre-sphenoid, vomer, and palatine bones. In dorsoventral graphs, teeth, nasal bone, incisive bone, maxilla, mandible processes, condyloid process, zygomatic arch, frontal bone, tympanic bulla, and occipital bone were observed (Figure 5).

On the oblique open-mouth view, the frontal bone appeared convex in shape, especially in the cranial region. The supra-orbital groove was not detectable. The nasal bone was jointed with incisive bone in the rostral region and formed a nasal cavity. The anterior extremity of the bone was concave. The bone was connected with occipital bone in the cranial region, with parietal bone in the upper region, and with sphenoid bone in the lower part. According to the radiographs, squamous and petrous parts of the temporal bone were not detectable. Upper and lower teeth, maxilla, pre-maxilla, mandible zygomatic arch, frontal, parietal, intraparietal, tympanic bulla, and occipital bones were observable (Figure 6). In the alveolar border, the incisive part contained three alveoli for incisive teeth and one alveolus for canine tooth. The molar part had seven cavities for pre-molar and molar teeth. Mental foramen was observable, but the

**Table 1.**

Skull measurements of the male and female husky dog (Mean  $\pm$  Standard deviation)

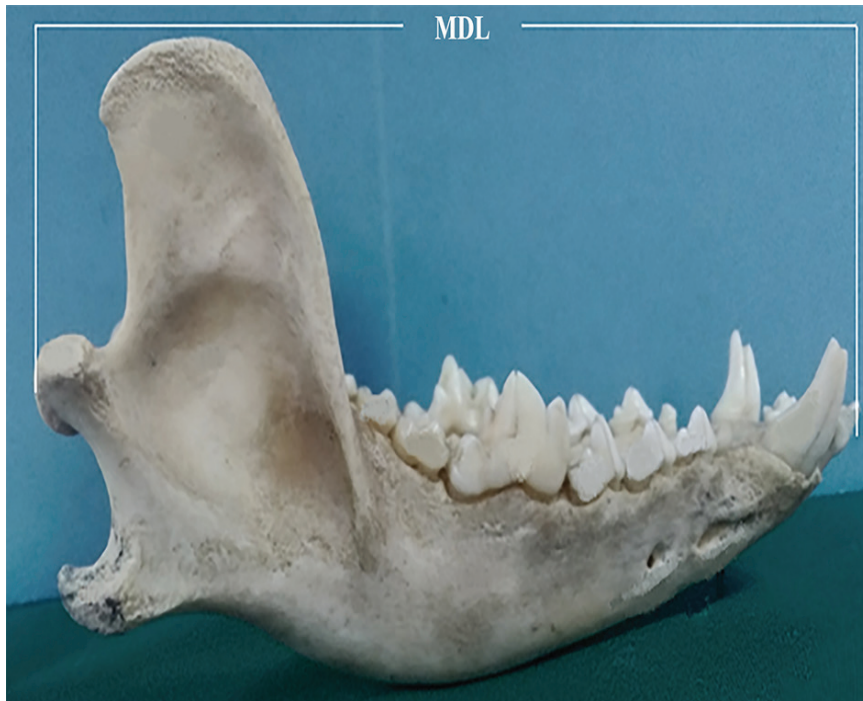Parameters (mm)	Male, n= 4	Female, n= 4	Total, n= 8
WSH 1	98.42 $\pm$ 0.63	95.87 $\pm$ 0.79	97.14 $\pm$ 0.77
WSL 2	214.74 $\pm$ 1.21	203.37 $\pm$ 1.76*	209.05 $\pm$ 1.50
SHWM1 3	75.29 $\pm$ 0.62	71.32 $\pm$ 0.59	73.30 $\pm$ 0.64
SHWM2 4	81.15 $\pm$ 0.63	78.41 $\pm$ 0.72	79.78 $\pm$ 0.71
MWS 5	115.52 $\pm$ 0.69	107.20 $\pm$ 0.84*	111.36 $\pm$ 0.75
FBL 6	73.32 $\pm$ 0.39	70.23 $\pm$ 0.59	71.77 $\pm$ 0.51
NBL 7	84.82 $\pm$ 0.76	79.27 $\pm$ 0/72	82.04 $\pm$ 0/73
FNE 8	52.05 $\pm$ 0.32	49.16 $\pm$ 0/53	50.60 $\pm$ 0/51
MDL 9	158.87 $\pm$ 1.97	152.66 $\pm$ 1.51	155.76 $\pm$ 1.13
MSL 10	33.49 $\pm$ 0.25	32.14 $\pm$ 0.29	32.81 $\pm$ 0.26
PAL 11	47.96 $\pm$ 0.534	45.08 $\pm$ 1.024	46.52 $\pm$ 0.849
UMP 12	32.2 $\pm$ 0.192	31.2 $\pm$ 0.288	31.70 $\pm$ 0.241
TBL 13	22.38 $\pm$ 0.19	22.41 $\pm$ 0.22#	22.39 $\pm$ 0.23
TBW 14	16.55 $\pm$ 0.38	15.32 $\pm$ 0.30	15.93 $\pm$ 0.41
TBH 15	16.67 $\pm$ 0.20	16.70 $\pm$ 0.27#	16.68 $\pm$ 0.25
EAPH 16	6.19 $\pm$ 0.11	5.96 $\pm$ 0.08	6.07 $\pm$ 0.09
EAPW 17	6.72 $\pm$ 0.11	6.64 $\pm$ 0.09	6.68 $\pm$ 0.13
OVID 18	26.23 $\pm$ 0.18	25.95 $\pm$ 0.17	26.09 $\pm$ 0.15
OHD1 19	23.89 $\pm$ 0.18	23.76 $\pm$ 0.27	23.82 $\pm$ 0.26
OHD2 20	23.84 $\pm$ 0.29	22.12 $\pm$ 0.22	22.97 $\pm$ 0.31
Orbital index (%)	89.07 $\pm$ 4.27	90.32 $\pm$ 7.72#	89.67 $\pm$ 5.11
Cephalic index (%)	53.79 $\pm$ 2.89	52.85 $\pm$ 6.55	53.26 $\pm$ 5.01

$\chi^2(3)=1532, p < 0.001$

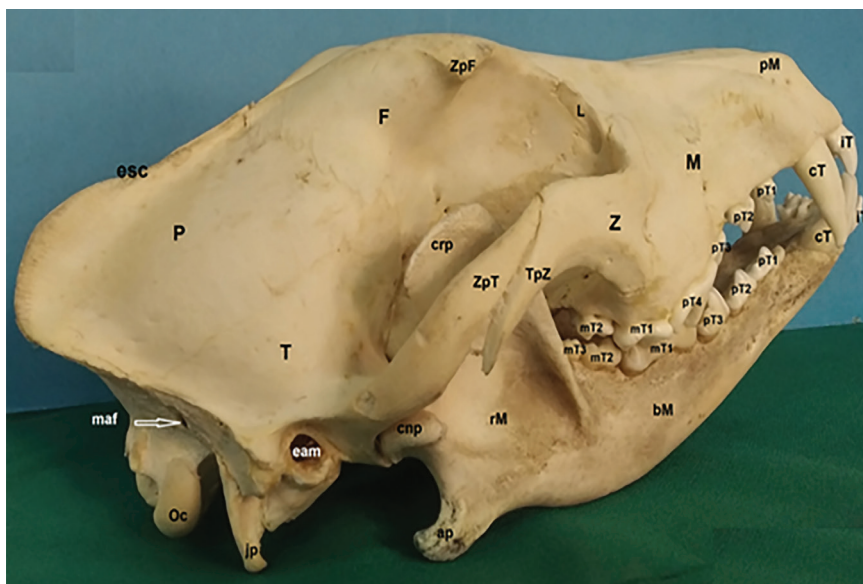
<sup>1</sup> Whole skull height, <sup>2</sup> Whole skull length, <sup>3</sup> Skull height without the mandible: the height of skull from the most dorsal point of frontal bone to the most ventral point of sphenoid bone, <sup>4</sup> Skull height without the mandible: the highest point of frontal bone to the lowest point of Jugular processes, <sup>5</sup> Maximum width of the skull, <sup>6</sup> Total length of frontal bone, <sup>7</sup> Total length of the nasal bone, <sup>8</sup> Length of parietal bone, <sup>9</sup> Length of the mandibular bone, <sup>10</sup> Mandibular symphyseal length, <sup>11</sup> Length of palate, <sup>12</sup> Length of the perpendicular plate of the palatine, <sup>13</sup> Tympanic bulla length, <sup>14</sup> Width of the tympanic bulla, <sup>15</sup> Greatest height of the tympanic bulla, <sup>16</sup> Height of the external auditory opening, <sup>17</sup> Width of the external auditory opening, <sup>18</sup> Orbital height/vertical diameter, <sup>19</sup> Orbital width/horizontal diameter: from the point of zygomatic arch, directed rostrally at 90° to the rim of the orbit, <sup>20</sup> Orbital width/horizontal diameter: from the point of the zygomatic arch, directed rostrally in a straight line to the rim of the orbit at the lacrimal fossa.

Superscript \* shows statistically significant difference between male and female parameters. Superscript # shows values which were higher in females with no statistically significant differences ( $P \leq 0.05$ ).

masseteric fossa was not detectable. Coronoid processes, condylar process, mandibular notch, and angle of the mandible with angular process were detectable (Figure 7).

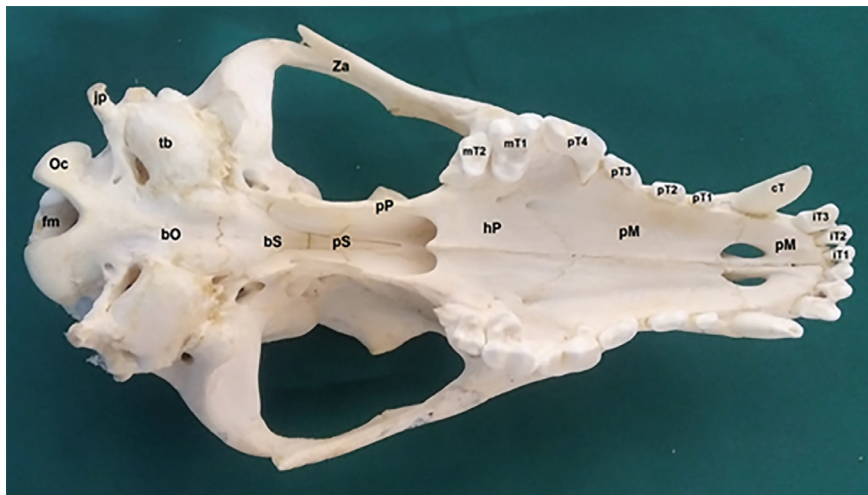

**Figure 5.** Dorso-ventral view (A) and ventro-dorsal view (B) of adult husky dog skull. 1: Incisor teeth, 2: Canine tooth of the lower jaw, 3: Canine tooth of the upper jaw, 4: Horizontal ramus of mandible, 5: Vomer bone, 6: Fourth premolar tooth of the upper jaw, 7: First molar tooth of lower jaw, 8: Nasal cavity, 9: Ethmoidal bone, 10: Frontal bone, 11: Zygomatic arch, 12: Coronoid process of mandible, 13: Parietal bone, 14: Mandibular condyle, 15: Brain cavity, 16: External auditory canal, 17: Tympanic bulla, 18: Occipital condyle.



**Figure 6.** Dorso-ventral view (A) and ventro-dorsal view (B) of adult husky dog skull. 1: Incisor teeth, 2: Canine tooth of the lower jaw, 3: Canine tooth of the upper jaw, 4: Horizontal ramus of mandible, 5: Vomer bone, 6: Fourth premolar tooth of the upper jaw, 7: First molar tooth of lower jaw, 8: Nasal cavity, 9: Ethmoidal bone, 10: Frontal bone, 11: Zygomatic arch, 12: Coronoid process of mandible, 13: Parietal bone, 14: Mandibular condyle, 15: Brain cavity, 16: External auditory canal, 17: Tympanic bulla, 18: Occipital condyle.





**Figure 7.**

Oblique-lateral view of the mandible of a husky dog. 1: Incisor teeth, 2: Inferior canine tooth, 3: Inferior premolar 1, 4: Inferior premolar 2, 5: Inferior premolar 3, 6: Inferior premolar 4, 7: Inferior molar 1, 8: Inferior molar 2, 9: Inferior molar 3, 10: Mental foramina, 11: Horizontal ramus of mandible, 12: Vertical ramus of mandible, 13: Coronoid process, 14: Condylar process and 15: Angular process.

## Discussion

This study was conducted to evaluate the radiological and anatomical features of the skull bones in adult Husky dogs. Several studies have reported measures, locations, and shapes of skull bones in other species, such as wolves, foxes, and Aksaray Malakli dogs [4, 13, 14].

Previous studies on the skull morphometry of German shepherds showed that the length of the skull is 14.38 cm, while it is 16.22 cm in the Nigerian local dog, both of which are smaller than that of Husky (25.65 cm). In another study conducted on the Kangal dog, the skull was reported to be 25.87 cm in length which is roughly the same size as Husky in the current study [15].

The current research revealed that the skull width of Huskies was 11.13 cm which was larger than that of the Nigerian local dog (8.49 cm), but smaller than that of the Kangal breed dog (13 cm) [15, 16]. These variations indicate the normal breed variants in different breeds of dogs.

The head index in our study was calculated to be  $53.26\% \pm 5.01\%$ , whereas the corresponding values for the Russian Dolicocephalic Collie, Wolfhound, Mesaticephalic German Shepherd, and Brachycephalic Boston Terrier breeds were 48%, 56%, 58%, and 81%, respectively. As a result, head index in Husky dog was closer to the Wolfhound's [17, 18]. The Niger dog's orbital index was 80.87. More precisely, orbital indices of males were higher (81.57) than females (80.35) [16]. The orbital indices of huskies, on the other hand, were lower in males (89.07) than in females (89.67).

Couturier et al. (2005) reported that the nuchal

crest in medium-sized dogs was slightly prominent and had no tubercles, while the results of the current study revealed that the nuchal crest was quite prominent in the Husky dog, beneath which were two distinct tubercles (muscular print). The mastoid foramen was located on the caudal surface of this bone [19].

Andreis et al. (2016), in a study on mesaticephalic dogs, reported only one small irregular foramen on the cribriform plate of the ethmoid bone, while there were two distinct holes on the cribriform plate of the ethmoid bone of Husky dogs. The cribriform plate itself had numerous small foramina with round edges being located next to the alar canal [20].

Our results are in agreement with the findings of Hermanson et al. (2018), stating that the temporal bone of medium-sized dogs has squamous, tympanic, and petrous parts in addition to a zygomatic process. This process joins with the temporal process of the zygomatic bone to form the zygomatic arch. The tympanic bulla was very large and a small muscular process was extended to its front. Based on our findings in the Husky breed, the mastoid process, as well as the muscular process of the temporal bone, were atrophied and the styloid process was also very small [21].

In 2020, Watson reported tuberosities of the maxillary bone, such as facial crest, in small- and large-sized dogs, and outlined their characteristics. However, according to the radiological findings of our study, the maxilla of Husky dogs did not have a facial crest and facial tuber. The infraorbital foramen was shown to be located dorsal to the third premolar tooth [22]. The radiological findings were confirmed in anatomical studies. This bone only had a frontal appendage which was attached to the frontal bone.

Some diagnostic imaging studies showed that the ethmoid bone in dogs has recognizable foramen [23, 24]. The results of the current study revealed that the ethmoid bone was located between the cranial cavity and nose and no foramen was recognizable. In addition, it was found that the ethmoid bone was fused to the caudal part of the presphenoid. It was also rostroventrally merged with vomer and palatine, and rostradorsally with frontal bones.

It has been stated that different factors, such as nutrition, influence the skull morphology; high-quality diets may help bones grow to a larger extent [25]. According to the owners, cases in this study were fed on a mixed diet, including chicken and skeleton. The authors did not manage to find other studies investigating the radiological and anatomical features of the skull bone in adult Husky dogs fed on different types of diets. Therefore, no comparative conclusion could be made in this regard.

The results showed that the cephalic index was 53 in both genders. The findings were parallel with several studies on the cephalic index of other species and breeds. Urošević et al. (2021) reported a skull index of 64 in Yugoslav shepherd dogs [26]. Moreover, Gál et al. (2022) reported a value of  $53.13 \pm 3.35$  in grey wolf which was in agreement with our findings [9]. Another study also reported the values of 52.52 and 52.53 in red foxes which were close to our findings [7].

In conclusion, this study was conducted to investigate the radiological and anatomical features of the skull bones in adult Husky dogs. The results showed both similarities and differences between Husky and other breeds of dogs. The findings of the current study can be used in making diagnostic and clinical deci-

sions to distinguish the normal and abnormal size and shape of the skull bones of adult Husky dogs.

## Materials & Methods

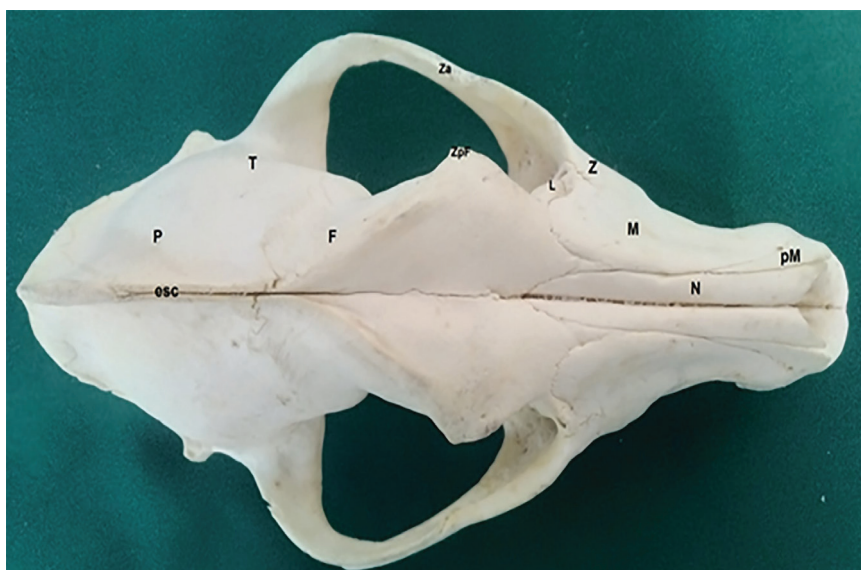### Animals

In the current descriptive cross-sectional study, eight adult husky dogs (four males and four females), with an average age of  $6.40 \pm 1.50$  years, and a mean weight of  $23.37 \pm 3.65$  kg were studied. In order to collect the skulls, the objectives of this study were explained to the officials of veterinary hospitals. Following their agreements, Husky dogs, dead or euthanized due to different disorders, were sent to the center where the current study was held. None of the cases died due to diseases related to the head. The approximate age of each dog was confirmed using the dental formula [27].

### Description of the method

Radiographs of the skulls were obtained on dorsoventral, ventrodorsal, and left and right lateral recumbency. The focal film distance was 100 cm, and the applied kVp and mAs were 55 and 4, respectively. The radiographs were taken using a digital device (Ralco-S.r.l DR, Italy). The detector was a SCI flat panel type with a size of  $24 \times 30$  cm, and the software used to process images and measure the structures was Varian and Drgem.

In order to prepare the skulls, the skin and muscles of the head and neck were removed using dissection tools. Skull bones were then flushed with water, soaked in KOH for 5 days, and whitened using  $H_2O_2$  (Figure 8). The skull was dried by sunlight for 7 days. Morphometric parameters were measured by a caliper and the mean was reported [15, 16]. Whole skull height was considered as the distance between the most dorsal surface of the frontal bone and the most ventral surface of the mandible bone. Skull height without the mandible was considered as the height of the skull from the most dorsal point of the frontal bone to the most ventral point of the sphenoid bone in the foramen magnum. Skull heights without the mandible were measured from the highest point of the frontal bone to the lowest point of the jugular processes. Height of the external auditory opening and width of the external auditory opening were calculated as the distance between the dorsal and ventral regions of the open-



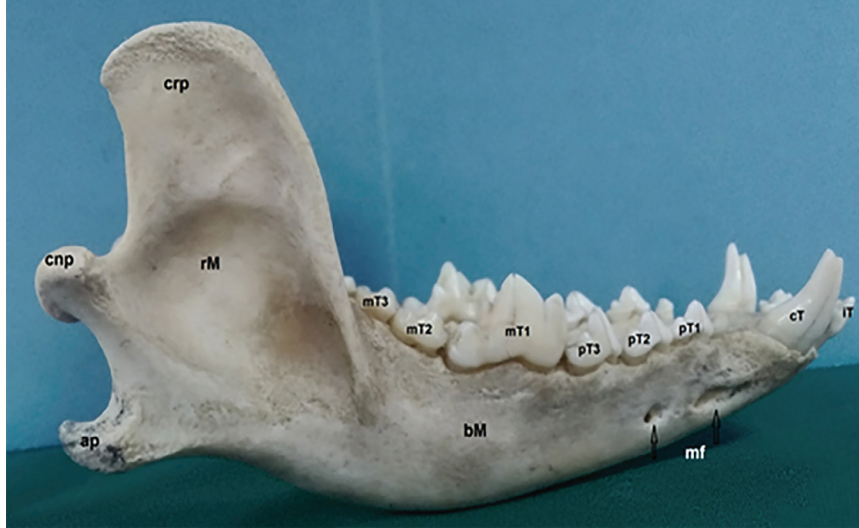
**Figure 8.**

Skull preparation. A: The Skull was bleached using 3%  $H_2O_2$  for 24-48 hours B: The skull was left to be dried.

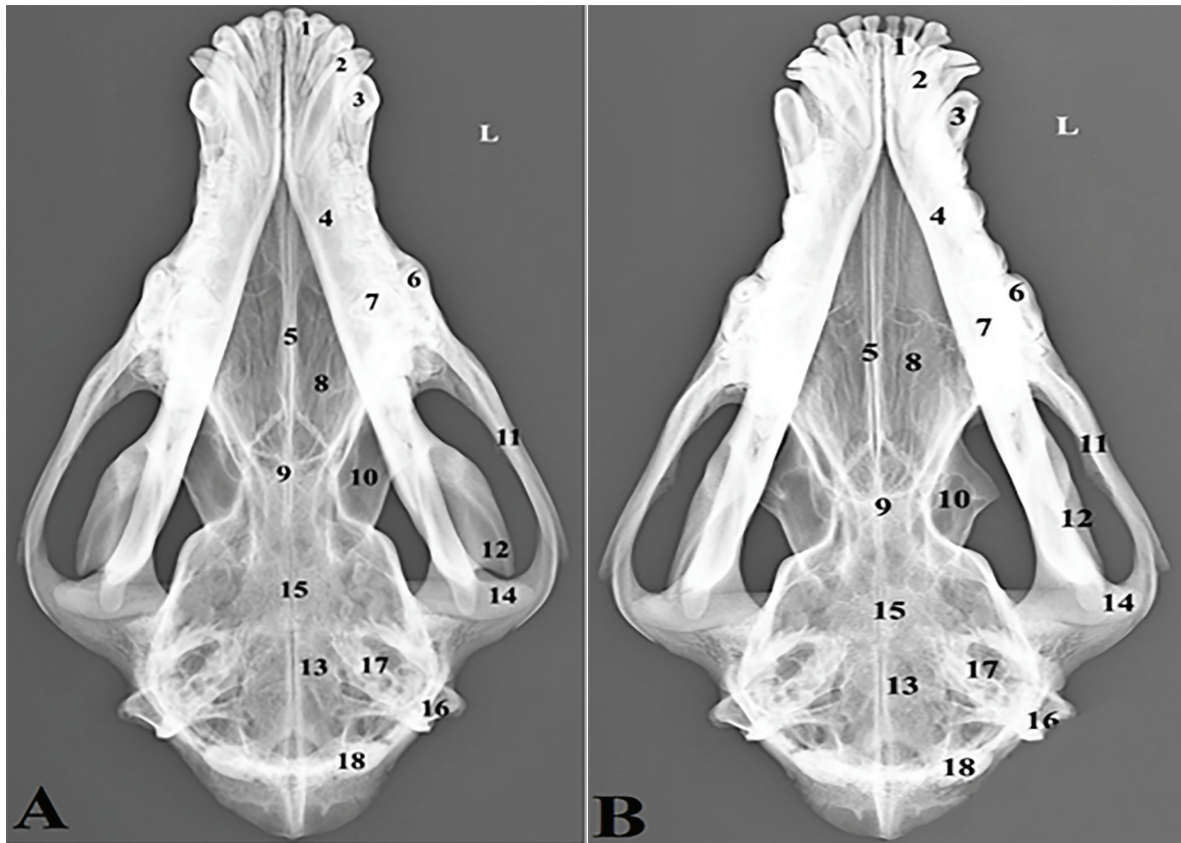


ing and the distance between the two regions, respectively. Orbital height/vertical diameter was measured from the ventral region of the orbit. Orbital width/horizontal diameter was calculated from the point of the zygomatic arch directed rostrally at 90° to the rim of the orbit. Orbital width/horizontal diameter was considered from the point of the zygomatic arch directed rostrally in a straight line to the

rim of the orbit at the lacrimal fossa. The orbital index was calculated as the width to the height of the orbit and reported as a percent. The cephalic index was reported as the width to the length of the skull in percent (Figure 9). The maximum width of the skull was considered as the width of the skull from one zygomatic bone to the other. The whole skull length was considered as the distance of the rostral part



**Figure 9.** Lateral view of the adult male husky dog skull. Whole skull height (WSH), Skull height without the mandible (SHWM1), Skull heights without the mandible (SHWM2), Height of the external auditory opening (EH), Width of the external auditory opening (EW), Orbital height/vertical diameter (OVD), and Orbital width/horizontal diameter (OHD).



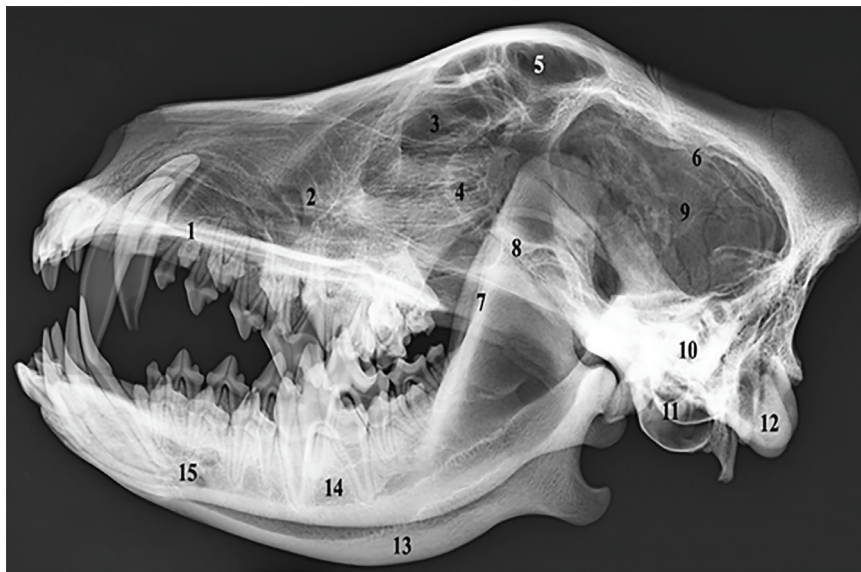
**Figure 10.** Ventral view of the adult male husky dog skull. Maximum width of the skull (MWS), Whole skull length (WSL), Length of the palate (PAL), Length of the perpendicular plate of the palatine (UMP), Tympanic bulla length (TBL), and Width of the tympanic bulla (TBW).

of incisive alveoli to the most caudal region of the occipital bone. The length of the palate was evaluated in the median line from the palatine bone to the caudal foramen. The length of the perpendicular plate of the palatine bone is considered the most caudal part of the caudal bone foramen to the suture of the vertical plate of the palatine bone. The greatest height of the tympanic bulla, tympanic bulla length, and width of the tympanic bulla were also measured (Figure 10). The total length of the frontal bone was measured as the anterior section of bone to the suture region of this bone. The overall length of the nasal bone was assessed as the terminal part of the frontal bone to the rostral part of the nasal bone. The length of the parietal bone was considered as the length of the frontoparietal suture to nuchal

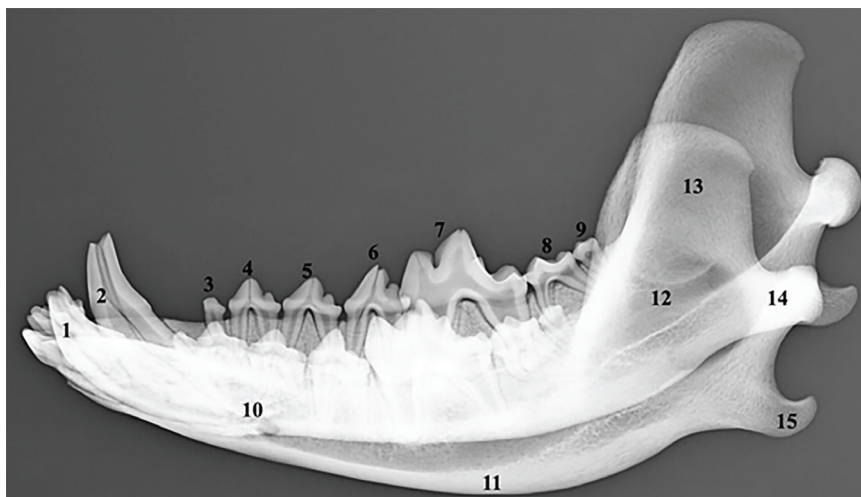
eminence (Figure 11). The length of the mandibular bone was evaluated as the length of the mandible to the caudal part of the condyloid. The mandibular symphyseal length was evaluated as the symphyseal length of the mandible, originating from the rostral to the cranial part of the region (Figure 12).

**Statistical Analysis**

Data were analyzed using SPSS v.24 and expressed as mean ± SD. The student t-test and ANOVA were used to compare the means. P-value < 0.05 was considered statistically significant.



**Figure 11.** Dorsal view of the adult male husky dog skull. The total length of frontal bone (FBL), length of the nasal bone (NBL), and Length of parietal bone (FNE).



**Figure 12.** Oblique lateral view of the adult male husky dog mandible. Length of the mandibular bone (MDL).



## Authors' Contributions

SA and MRH conceived and planned the experiments. SA and MRH, ALA contributed to sample preparation. SA, MRH contributed to the interpretation of the results. SA and SA took the lead in writing the manuscript. All authors provided critical feedback and helped shape the research, analysis and manuscript.

## Acknowledgements

The authors thank the Faculty of Veterinary Medicine, Urmia Branch, Islamic Azad University, Urmia, Iran, for all of the facilities.

## Conflict of interest

The authors declare that there is no conflict of interest.

## References

1. Dasilveira EE, Dasilvalisboaneto AF, CarlosSabinoPereira H, Ferreira JS, DosSantos AC, Siviero F. Canine skull digitalization and three-dimensional printing as an educational tool for anatomical study. *Journal Of Veterinary Medical Education*. 2021;48(6):649-55. DOI: 10.3138/jvme-2019-0132
2. Bannasch DL, Baes CF, Leeb T. Genetic variants affecting skeletal morphology in domestic dogs. *Trends in genetics*. 2020;36(8):598-609. DOI: 10.1016/j.tig.2020.05.005
3. Ograk Y, Urosevic M, Drobnjak D. Tarsus Çatalburun Breed of Turkish Hunting Dog (Turkish Pointer). *Agriculture, Zemun-Belgrade (Serbia)*. 2012;6(1):22-24. UDC: 639.1.081.31
4. Geiger M, Evin A, Sánchez-Villagra MR, Gascho D, Mainini C, Zollikofer CP. Neomorphosis and heterochrony of skull shape in dog domestication. *Scientific Reports*. 2017;7(1):1-9. DOI: 10.1038/s41598-017-12582-2
5. Krofel M, Hatlauf J, Bogdanowicz W, Campbell L, Godinho R, Jhala Y. Towards resolving taxonomic uncertainties in wolf, dog and jackal lineages of Africa, Eurasia and Australasia. *Journal of Zoology*. 2022;316(3):155-68. DOI: 10.1111/jzo.12946
6. Gál E, Bartosiewicz L, Kiss V. A fifth–sixth century CE lynx (*Lynx lynx* L., 1758) skeleton from Hungary: Cranial morphology and zoological interpretations. *International Journal of Osteoarchaeology*. 2022;32(4):41-49. DOI: 10.1002/oa.3101
7. Hadžiomerović N, Gündemir O, Kovačević S. Mandible size and shape of the red fox (*Vulpes vulpes*) and golden jackal (*Canis aureus*). *Adv Anim Vet Sci*. 2022;10(2):364-8. DOI: 10.17582/journal.aavs/2022/10.2.364.368
8. Martín-Serra A, Nanova O, Varón-González C, Ortega G, Figuero B. Phenotypic integration and modularity drives skull shape divergence in the Arctic fox (*Vulpes lagopus*) from the Commander Islands. *Biology letters*. 2019;15(9):406-12. DOI: 10.1098/rsbl.2019.0406
9. Srinivas Y, Jhala Y. Morphometric variation in wolves and golden jackal in India (Mammalia, Carnivora). *Biodiversity Data Journal*. 2021;27(9):48-62. DOI: 10.3897/BDJ.9.e67677
10. Wan M, Hejjas K, Ronai Z, Elek Z, Sasvari-Szekely M, Champagne FA. DRD 4 and TH gene polymorphisms are associated with activity, impulsivity and inattention in Siberian Husky dogs. *Animal genetics*. 2013;44(6):717-27. DOI: 10.1111/age.12058
11. Rohleder JJ, Jones J, Duncan R, Larson MM, Waldron DL, Tromblee T. Comparative performance of radiography and computed tomography in the diagnosis of middle ear disease in 31 dogs, *Vet Radiol Ultrasound*. 2016;47(1):45-52. DOI: 10.1111/j.1740-8261.2005.00104.x
12. Wisner E, Zwingerberger A. *Atlas of small animal CT and MRI*. 1st ed. Iowa, USA: Wiley Blackwell; 2015.
13. Widyananta BJ, Saleh CP, Noviana D, Rahmiati DU, Ulum MF, Soehartono RH. *Atlas of Normal Radiography in the Dogs and Cats*. PT Penerbit: IPB Press; 2017.
14. İlgün R, Özüdoğru Z, Karabulut O, Can M. Macroanatomical and morphometric study on the skull bones of Aksaray Malakli dogs. *Folia Morphologica*. 2022;81(1):157-63. DOI: 10.5603/FM.a2021.0011
15. Onar V, Pazvant S. Skull typology of adult male Kangal dogs. *Anatomia, histologia, embryologia*. 2001;30(1):41-8. DOI: 10.1046/j.1439-0264.2001.00292.x
16. Igado OO. Skull typology and morphometrics of the Nigerian local dog (*Canis lupus familiaris*). *Niger J Physiol Sci*. 2017;32(2):153-8. PMID: 29485635
17. Onar V, Çakırlar C, Janeczek M, Kızıltan Z. Skull Typology of Byzantine Dogs from the Theodosius Harbour at Yenikapı, Istanbul. *Anat. Histol. Embryol*. 2012;41(1): 341-52. DOI: 10.1111/j.1439-0264.2012.01143.x
18. Evans HE, Christensen C. *Miller's Anatomy of the Dog: The skeletal system (skull)*. 3rd ed. Philadelphia, W.B: Saunders Press; 1993.
19. Couturier L, Degueurce C, Ruel Y, Dennis R, Begon D. Anatomical study of cranial nerve emergence and skull foramina in the dog using magnetic resonance imaging and computed tomography. *Veterinary Radiology & Ultrasound*. 2005;46(5):375-83. DOI: 10.1111/j.1740-8261.2005.00068.x
20. Andreis ME, DiGiancamillo M, Faustini M, Veronesi MC, Modena SC. Dog craniometry: a cadaveric study. *Università degli Studi di Milano*. 2016;6(1):23-33. DOI: 10.13130/2283-3927/7082
21. Hermanson JW, Evans HE, DeLahunta A. *Miller and Evans'*

- anatomy of the dog. Health Sciences: Elsevier; 2018.
22. Watson E. Veterinary forensic radiology and imaging. Forensic Sciences: CRC Press; 2020.
23. DePaolo MH, Arzi B, Pollard RE, Kass PH, Verstraete FJ. Craniomaxillofacial trauma in dogs—Association between fracture location, morphology and etiology. *Frontiers Vet. Sci.* 2020;242(7):1-15. DOI: 10.3389/fvets.2020.00242
24. Dunand L, Belluzzi E, Bongartz A, Caraty J. Application of a bilateral temporal fascia free graft in a dog with multifragmented frontal sinus and nasal bone fracture. *Veterinary Surgery.* 2022;32(1):127-44. DOI: 10.1111/vsu.13804
25. Chirchir H. Trabecular bone in domestic dogs and wolves: Implications for understanding human self-domestication. *The Anatomical Record.* 2021;304(1):31-41. DOI: 10.1002/ar.24510
26. Urošević MM, Drobnjak D, Stojic P, Urošević MB. Craniological parameters of Yugoslav shepherd dog Sharplanina. *Mediterranean Agricultural Sciences.* 2017;30(3):269-74. DOI: 10.24925/turjaf.v8i7.1571-1576.3452
27. Gracis M. Dental anatomy and physiology. *BSAVA manual of canine and feline dentistry and Oral surgery*: BSAVA; 2018.

#### COPYRIGHTS

©2024 The author(s). This is an open access article distributed under the terms of the Creative Commons Attribution (CC BY 4.0), which permits unrestricted use, distribution, and reproduction in any medium, as long as the original authors and source are cited. No permission is required from the authors or the publishers.



#### How to cite this article

Ahani S, Alizadeh S, Hosseinchi MR. Radiological and Anatomical Features of the Skull Bones of Adult Husky Dogs. *Iran J Vet Sci Technol.*2024; 16(1): 33-44.

DOI: [https://doi.org/ 10.22067/ijvst.2024.82573.1255](https://doi.org/10.22067/ijvst.2024.82573.1255)

URL: [https://ijvst.um.ac.ir/article\\_44886.html](https://ijvst.um.ac.ir/article_44886.html)