



Effect of *Aloe vera* and *Salvia officinalis* extract supplemented diet on hematology, histopathology, and hypoxia resistance in rainbow trout

Ali Akbar Tafi^a, Saeid Meshkini^b, Amir Tukmechi^c, Mojtaba Alishahi^d, Farzaneh Noori^e

^a Department of Fisheries, Faculty of Natural Resources, Urmia University, Urmia, Iran ^b Department of Food Hygiene and Quality Control, Faculty of Veterinary Medicine, Urmia University, Urmia, Iran ^c Department of Microbiology, Faculty of Veterinary Medicine, Urmia University, Urmia, Iran. ^d Department of Clinical Science, Faculty of Veterinary Medicine, Shahid Chamran University of Ahvaz, Ahvaz, Iran. ^e Department of Aquaculture, Artemia & Aquaculture Institute, Urmia University, Urmia, Iran.

ABSTRACT

This study investigated the effects of *Aloe vera* and *Salvia officinalis* extracts on hematological and haemato-biochemical parameters, histopathology, and resistance against hypoxia stress in *Oncorhynchus mykiss*. The rainbow trout (10 ± 0.1 g) were fed seven different diets supplemented with 0% (control), 0.5%, 1% and 1.5% of *A. vera* or *S. officinalis* extract for 30 days. The feeding in all treatments was continued for 2 weeks using control diet. The fish blood samples were collected on days 30th and 45th, and total red blood cells, hematocrit and hemoglobin were measured. The glucose and cortisol of serum were examined just before and one hour after hypoxia stress (3 mg L^{-1}) at days 30th and 45th. The gill tissue samples were taken from all treatments for histopathological study at the end of experimental period. The *S. officinalis* (0.5%) treated group showed a significant increase ($p < 0.05$) in red blood cells, hematocrits and hemoglobin compared to control group. While the *A. vera* (1 and 1.5%) treatments revealed significant increase in hematocrit and hemoglobin concentration compared to the control group ($p < 0.05$). Moreover the glucose and cortisol levels of serum were increased significantly only in *S. officinalis* (0.5%) treated group after hypoxia stress on days 30th and 45th compared to the control group ($p < 0.05$). No serious histopathological changes were observed in any treatments and control group. Based on the results obtained, dietary *S. officinalis* (0.5%) hydroethanolic extract improved the haematological and haemato-biochemical parameters and increased the rainbow trout resistance against hypoxia stress.

Keywords

Oncorhynchus mykiss, Herbal Extracts, Environmental Stresses, Hematology, Histopathology

Abbreviations

RBC: red blood cell
S. officinalis: *Salvia officinalis*
O. mykiss: *Oncorhynchus mykiss*
A. vera: *Aloe vera*

Introduction

Rainbow trout (*Oncorhynchus mykiss*) is a very popular coldwater species in world aquaculture industry. Sustainable development in rainbow trout culture depends on the special attention on health status of this fish [1]. Therefore, a new approach to immunotherapy is actively used to treat or protect fish when exposed to stresses. In this regard, extensive research has been carried out to test various immunostimulants including medicinal plants which they have found to be effective in fish [2]. It has been found that medicinal herbs enhance the immune system against stressors and especially various bacteria [3, 4]. Modulation of the immune response using medicinal plant products as a therapeutic measure has become the focus of extensive scientific investigation [5]. Two common themes running through recent research is the immunomodulatory properties of Aloe vera [6] and Sage, *Salvia officinalis* [7].

A. vera (synonym: *Aloe barbadensis* Miller) belonging to the family Liliaceae is widely distributed in the tropical and subtropical regions of the world, and the genus *Aloe* contains over 400 different species and *Aloe barbadensis* Miller is considered to be the most biologically active [8]. *S. officinalis* L. (sage, garden sage, or common sage) from the family Lamiaceae, is a worldwide cultivated aromatic herb. It is native to the Mediterranean region and is currently cultivated in various countries [9]. These plants, with their medicinal potency, originated from their bioactive content, play an important role in preventing diseases and enhancing the ability of the aquatic immune system [10]. Many researchers have pointed to the importance and role of these plants in enhancing growth indices [11] and immune responses [12] and modifying the histopathological lesions of some fish species [13].

Although researchers have reported in many cases the role of medicinal plants (such as *A. vera* and *S. officinalis*), and despite of the effect of their natural bioactive content in development of fish prevention and safety, they should not be ignored by their potential adverse effects. Therefore, besides the use of medicinal plants in aquatics, it is important to study their effect on the vital tissues of fish [14].

Histopathological changes have been widely used as biomarkers in the evaluation of the health of fish exposed to contaminants, chemical and natural materials both in the laboratory [14] and field studies [15]. The gills, which participate in many important functions in fish, such as respiration, osmoregulation, and excretion, remain in close contact with the external environment, are particularly sensitive to changes in the quality of water, and are considered the primary target of the contaminants. So, in herbal extracts

studies, the histopathological assays would be useful to evaluate the effect of plant extracts on gill tissue.

The objective of the present study was to evaluate the effects of *A. vera* and *S. officinalis* ethanolic extract on various haematological and histopathological parameters and stress indices in *O. mykiss* to develop an alternative drug to enhance fish resistance against hypoxia in aquaculture.

Results

The chemical composition of herbal extracts was determined by GC/MS and presented in Table 1. The main components were n-Hexadecanoic acid (15.22%), Cineol (10.35%), Oleic acid (12.28%) followed by Octacosane (10.71%) for *A. vera*; and 1,6,10-Dodecatriene, 7,11-dimethyl-3-methylene-, (E)- (15.51%), α -Sesquiphellandrene (12.26%), Cineol (12.21) followed by 1-Naphthaleneacetic acid, methyl ester (10.10%) for *S. officinalis*. Cineol is a monoterpenoid and exists in both *A. vera* and *S. officinalis* extracts in this study (Table 1).

Data of Hematological parameters of trial and control groups are compared statistically in Table 2. According to the results of Table 2, the fish treated with *S. officinalis* (0.5%) revealed the highest value of total RBC, hematocrit, and hemoglobin in both 30 and 45 sampling days, showing a significant difference compared to the control group. Moreover at day 45 the fish fed with diets supplemented with, *S. officinalis* (0.5%) exhibited significantly higher hematocrit and hemoglobin values compared to the control group. At day 30 *A. vera* (1 and 1.5%) treatments were significantly different in comparison to the control group just in terms of hematocrit percentage. Also, *A. vera* (1%) and *A. vera* (0.5 and 1%) treatments were significantly different with the control group in cases of hematocrit and hemoglobin values, respectively (Table 2).

Glucose and cortisol levels of serum samples of fish in all groups were measured on days 30 and 45, prior and one hour after exposure to hypoxia stress (3 mg/L⁻¹), and the results are shown in Table 3. There was no significant differences between the glucose and cortisol levels of fish in all treatments and control groups before stress at day 30th and 45th. Also, no treatment showed any difference with the control group in case of glucose and cortisol levels after stress at day 45. The *S. officinalis* (0.5%) treatment showed a significant difference in serum glucose and cortisol levels after exposure to hypoxia stress on day 30 compared to the control (Table 3).

Cumulative mortality of fish at the end of 6 hours of hypoxia stress on days 30 and 45 are illustrated and compared in Figure 1 and 2, respectively. The *S. officinalis* (0.5%) treatment showed significantly lower

Table 1The main chemical composition of *A. vera* and *S. officinalis* extracts

<i>S. officinalis</i>		<i>A. vera</i>	
Component	%	Component	%
Cineol	12.21	p-Xylene	2.25
Bicyclo[3.1.0]hexan-3-one, 4-methyl-1-(1-methylethyl)-, [1S-(1à,4á,5à)]-	2.14	1,5-Heptadien-4-one, 3,3,6-trimethyl-	2.41
Bicyclo[2.2.1]heptan-2-one, 1,7,7-trimethyl-, (ñ)-	4.71	Oleic acid	12.28
Borneol	5.29	1-Heptanol,2-propyl-	2.32
Bicyclo[7.2.0]undec-4-ene, 4,11,11-trimethyl-8-methylene-	4.75	Tetradecanoic acid	2.28
1,6,10-Dodecatriene, 7,11-dimethyl-3-methylene-, (E)-	15.51	n-Hexadecanoic acid	15.22
Germacrene D	2.22	Squalene	5.37
á-Sesquiphellandrene	12.26	Hentriacontane	5.99
1-Naphthalenol, 4-methoxy-	9.55	Octacosane	10.71
1H-Cycloprop[e]azulen-4-ol, decahydro-1,1,4,7-tetramethyl-, [1ar-(1aà,4á,4á,7à,7á,7bà)]-	5.38	1,2-Benzenedicarboxylic acid, diisooctyl ester	9.50
Butanoic acid, 3-methyl-, 1-ethenyl-1,5-dimethyl-4-hexenyl ester	3.27	Eicosane	4.87
1-Naphthaleneacetic acid, methyl ester	10.10	Heptacosane	5.19
1-Naphthalenepropanol, à-ethenyldecahydro-à,5,5,8a-tetramethyl-2-methylene-, [1S-[1à(R*),4aá,8aà]]-	3.39	Acemannan	5.97
Squalene	2.22	Cineol	10.35

Table 2

Hematological parameters of different groups in day 30 and 45

Treatments	Blood Index					
	Total RBC (10 ⁶ Cell/ μ l)		Hematocrit (%)		Hemoglobin (g/dl ⁻¹)	
	Day 30	Day 45	Day 30	Day 45	Day 30	Day 45
Control	1.28 \pm 0.13 ^a	1.33 \pm 0.13 ^a	41.22 \pm 1.09 ^a	41.11 \pm 0.78 ^a	7.77 \pm 0.68 ^a	6.78 \pm 0.52 ^a
<i>S. officinalis</i> (0.5%)	1.78 \pm 0.39 ^b	1.50 \pm 0.22 ^a	45.00 \pm 0.71 ^e	44.89 \pm 0.78 ^d	8.87 \pm 0.31 ^b	8.74 \pm 0.28 ^c
<i>S. officinalis</i> (1%)	1.47 \pm 0.41 ^{ab}	1.45 \pm 0.15 ^a	44.00 \pm 0.87 ^d	43.22 \pm 0.97 ^{cd}	8.51 \pm 0.39 ^{ab}	8.42 \pm 0.41 ^{bc}
<i>S. officinalis</i> (1.5%)	1.38 \pm 0.19 ^a	1.42 \pm 0.19 ^a	43.22 \pm 1.30 ^{cd}	43.55 \pm 1.33 ^{cd}	8.37 \pm 0.46 ^{ab}	8.36 \pm 0.46 ^{bc}
<i>A. vera</i> (0.5%)	1.41 \pm 0.20 ^{ab}	1.39 \pm 0.17 ^a	42.44 \pm 1.33 ^{abc}	42.11 \pm 1.76 ^{abc}	8.04 \pm 1.00 ^{ab}	7.87 \pm 1.01 ^b
<i>A. vera</i> (1%)	1.30 \pm 0.18 ^a	1.44 \pm 0.28 ^a	43.67 \pm 0.71 ^{cde}	43.11 \pm 1.05 ^{bc}	8.20 \pm 0.41 ^{ab}	8.33 \pm 0.43 ^{bc}
<i>A. vera</i> (1.5%)	1.33 \pm 0.14 ^a	1.40 \pm 0.14 ^a	43.00 \pm 0.87 ^{bcd}	42.44 \pm 1.51 ^{abc}	8.00 \pm 0.51 ^{ab}	7.67 \pm 0.49 ^{ab}

Data were subjected to analysis of variance (SPSS, One-Way ANOVA) followed by Tukey's test. The different superscript alphabets in the same column show significantly different groups at $p < 0.05$.

mortality compared to the control group and exhibited the least mortality among other treatments on days 30 and 45.

The histopathological results of gill tissue were shown

some light focal and moderate multifocal lesions in the treatment groups. The lesions are exhibited in Figures 3 and 4. The intensity of the lesions in different groups is shown in Table 4.

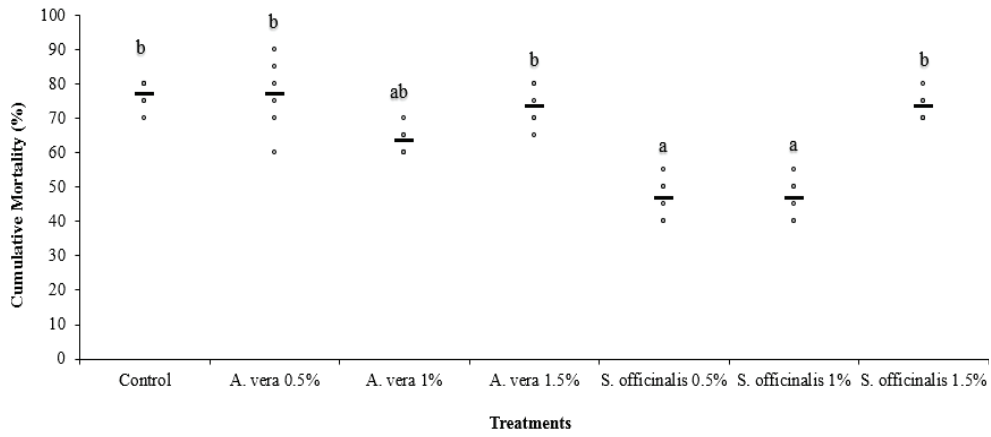


Figure 1. Cumulative mortality of fish at the end of 6 hours expose to hypoxia stress at day 30. The different alphabets show significantly different groups ($p < 0.05$).

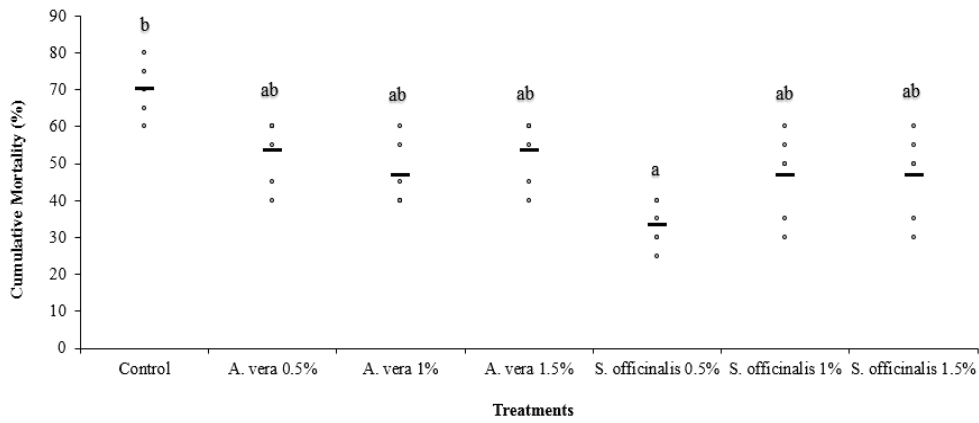


Figure 2. Cumulative mortality of fish at the end of 6 hours expose to hypoxia stress at day 45. The different alphabets show significantly different groups ($p < 0.05$).

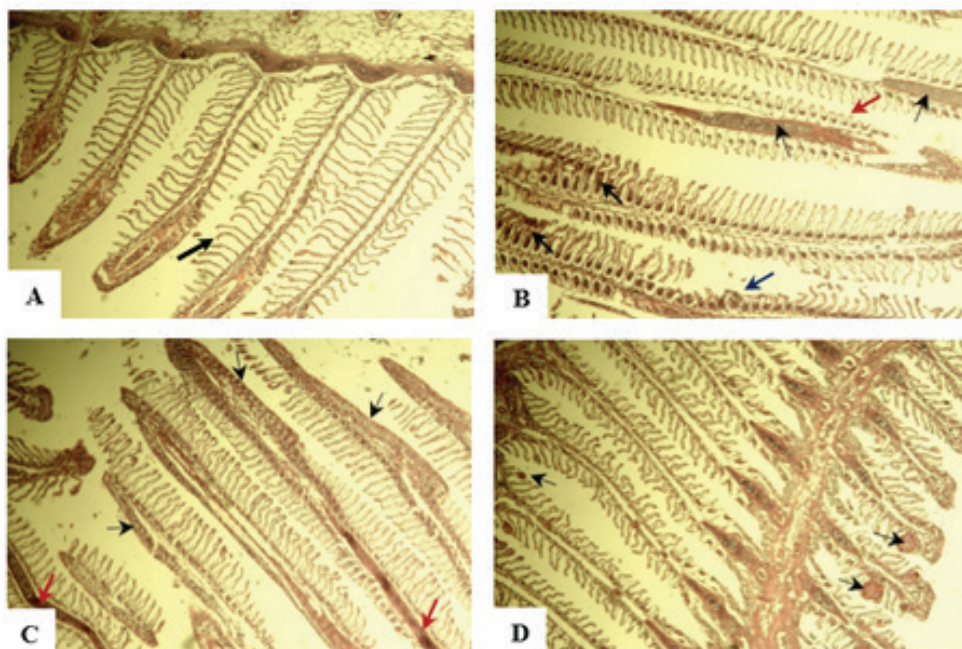


Figure 3. Photomicrograph of the gill tissue of the control and A. vera groups at day 30 (H & E. $\times 100$).

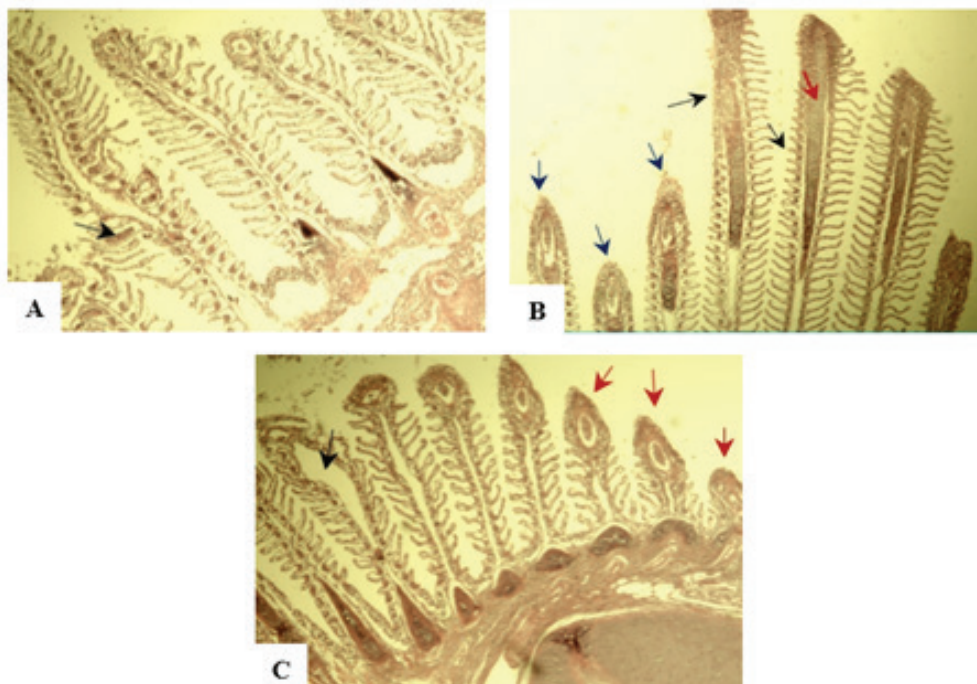


Figure 4.
Photomicrograph of the gill tissue of *S. officinalis* groups at day 30 (H & E. $\times 100$).

Discussion

The *A. vera* and *S. officinalis* have been used in traditional medicine. These medicinal plants have good potential to be used as alternative growth promoter, antimicrobial, anti-stressor, and immunostimulator in fish [16, 17] and other animals such as poultry [18]. The beneficial properties of *A. vera* and *S. officinalis* are due to the presence of effective compounds in these plants (Table 1). Natural biogenic compounds of these medicinal plants were analyzed in the present study and some natural compounds such as Cineol, 1-Heptanol, 2-propyl-, (4,7-Dinitronaphthalen-1-yl)-(4-methoxyphenyl) diazene, 1,2-Benzenedicarboxylic acid, diisooctyl ester followed by Squalene in *A. vera* and Cineol, Borneol, 1-Naphthaleneacetic acid, methyl ester, -Naphthalenol, 4-methoxy-1 and 1,6,10-Dodecatriene, 7,11-dimethyl-3-methylene-, (E)- in *S. officinalis* were identified as antimicrobial and immunostimulator agents in fish [19]. The Cineol is a monoterpenoid with anti-diabetic, antiviral, antispasmodic, vermicide, poison antidote, antimicrobial, antifungal, free radical scavenging, antioxidant, neuroprotective and immune-stimulating effects that exists in both extracts in this study. This bio-active substance that affects some blood factors, make fish resistant to the environmental stress [19].

The current study demonstrated that inclusion of *A. vera* and *S. officinalis* extracts in *O. mykiss* diet markedly enhance hematological parameters. The results (Table 2) of total RBC count in *S. officinalis*

(0.5%) treatment at day 30, hematocrit in *S. officinalis* (0.5%, 1% and 1.5%) treatments at days 30 and 45 and hemoglobin concentration in *S. officinalis* (0.5%) treatment at days 30 and 45 revealed significant differences compared to the control group ($p < 0.05$).

The *A. vera* (1% and 1.5%) treatments enhanced hematocrit at day 30 while hemoglobin concentration increased significantly in *A. vera* (0.5% and 1%) treatments compared to the control group at day 45 of the experiment (Table 2). Haghghi et al. (2014) reported no significant differences in total red blood cells, hematocrit and hemoglobin concentration between *A. vera* (1% of diet) treated group and the control group after eight weeks of feeding in the rainbow trout ($p < 0.05$) [20]. Some differences between their results and the results obtained by the current study might be related to the difference in fish age or extracts' composition. This difference can be attributed to the several environmental factors such as climatic, seasonal and geographical or ontogenesis variations, plant harvest time, error in the analysis of extracts and the time between extraction and analysis of compounds' constituents. No significant differences were observed in the red blood cell count between fish treated with any rate of *A. vera* and the control group (Table 2). These results are in consistent with the results obtained by other researchers [16, 21] who reported that common carp, *Cyprinus carpio* and rainbow trout treated with dietary *A. vera* supplementation had no significant differences in RBCs count [16, 21].

Some plasma chemicals may be useful indicators

Table 3

Glucose and cortisol of serum in day 30th and 45th, before and after hypoxic stress

Treatments	Glucose (mg dl ⁻¹)						Cortisol (ng ml ⁻¹)					
	Day 30			Day 45			Day 30			Day 45		
	Before Stress	After Stress	Before Stress	After Stress	Before Stress	After Stress	Before Stress	After Stress	Before Stress	After Stress	Before Stress	After Stress
Control	8.96 ± 1.20 ^a	12.07 ± 0.92 ^a	9.28 ± 0.60 ^a	12.75 ± 0.57 ^a	12.36 ± 1.06 ^a	19.50 ± 1.68 ^a	12.50 ± 0.85 ^a	19.80 ± 1.43 ^a	12.36 ± 1.06 ^a	19.50 ± 1.68 ^a	12.50 ± 0.85 ^a	19.80 ± 1.43 ^a
<i>S. officinalis</i> (0.5%)	9.32 ± 0.40 ^a	15.15 ± 0.57 ^b	9.26 ± 0.29 ^a	13.33 ± 0.23 ^a	12.84 ± 1.19 ^a	28.84 ± 2.80 ^b	12.76 ± 2.00 ^a	21.94 ± 2.45 ^a	12.84 ± 1.19 ^a	28.84 ± 2.80 ^b	12.76 ± 2.00 ^a	21.94 ± 2.45 ^a
<i>S. officinalis</i> (1%)	8.50 ± 0.72 ^a	12.83 ± 1.71 ^{ab}	8.28 ± 1.08 ^a	12.53 ± 1.44 ^a	12.40 ± 0.47 ^a	24.17 ± 3.13 ^{ab}	12.10 ± 0.74 ^a	20.03 ± 1.21 ^a	12.40 ± 0.47 ^a	24.17 ± 3.13 ^{ab}	12.10 ± 0.74 ^a	20.03 ± 1.21 ^a
<i>S. officinalis</i> (1.5%)	8.90 ± 0.22 ^a	12.92 ± 1.02 ^{ab}	8.55 ± 0.44 ^a	13.45 ± 0.71 ^a	12.61 ± 1.42 ^a	24.48 ± 3.58 ^{ab}	12.45 ± 0.23 ^a	20.65 ± 3.24 ^a	12.61 ± 1.42 ^a	24.48 ± 3.58 ^{ab}	12.45 ± 0.23 ^a	20.65 ± 3.24 ^a
<i>A. vera</i> (0.5%)	9.13 ± 0.11 ^a	12.41 ± 0.48 ^a	8.76 ± 0.61 ^a	13.26 ± 0.48 ^a	12.47 ± 0.22 ^a	21.76 ± 3.74 ^{ab}	12.22 ± 0.87 ^a	20.61 ± 1.83 ^a	12.47 ± 0.22 ^a	21.76 ± 3.74 ^{ab}	12.22 ± 0.87 ^a	20.61 ± 1.83 ^a
<i>A. vera</i> (1%)	8.78 ± 0.25 ^a	12.60 ± 0.48 ^a	8.98 ± 0.63 ^a	12.99 ± 0.58 ^a	12.35 ± 0.62 ^a	22.31 ± 3.52 ^{ab}	12.20 ± 0.94 ^a	20.69 ± 1.81 ^a	12.35 ± 0.62 ^a	22.31 ± 3.52 ^{ab}	12.20 ± 0.94 ^a	20.69 ± 1.81 ^a

Data were subjected to analysis of variance (SPSS, One-Way ANOVA) followed by Tukey's test. The different superscript alphabets in the same column show significantly different groups at $p < 0.05$.

Table 4Pathology scores of gill of fish given oral administration of *A. vera* and *S. officinalis* extract

Variables	Controls	Treatments					
		<i>A. vera</i> 0.5%	<i>A. vera</i> 1%	<i>A. vera</i> 1.5%	<i>S. officinalis</i> 0.5%	<i>S. officina- lis</i> 1%	<i>S. officinalis</i> 1.5%
Atrophy of secondary lamellas	- ^a	+ ^b	-	-	-	-	-
Degeneration and necrosis of lamellas	-	+	++ ^c	-	-	++	-
Hyperemia	-	++	++	-	-	++	-
Clubbed secondary lamellas	-	-	-	++	+	-	-
Stunted gill filaments	-	-	-	-	-	++	++
Subepithelial space edema	-	-	-	-	-	-	+

a: No lesions, b: Light, focal lesions, c: Moderate, multifocal lesions

to evaluate the health and/or stress condition of the fishes [22]. Since stress has been reported to elevate plasma cortisol and glucose levels [23], many researchers consider as a “rule of thumb” that fishes undergoing stressful situations exhibit plasmatic increases of cortisol and glucose. Cortisol is the principal glucocorticoid secreted by the interrenal tissue (steroidogenic cells) located in the head-kidney of teleost fish. This hormone is released by the activation of the hypothalamus-pituitary-interrenal axis (HPI axis). When fish are exposed to stress, the hypothalamus releases corticotropin-releasing factor (CRF) polypeptide into the blood circulation. This factor affects the anterior pituitary gland and adrenocorticotrophic hormone (ACTH) releases into the blood circulation which ultimately activates the release of cortisol by the interrenal tissue [24]. Cortisol hormone function is to promote glycogenolysis and gluconeogenesis processes in fish. Another function of cortisol hormone is to induce the chromaffin cells to release catecholamines that further increases glycogenolysis and modulates the cardiovascular and respiratory functions. The goal of this chain of processes is to eventually produce enough glucose to provide the energy needed to cope with stress [24].

Two hours after the beginning of hypoxia stress period, *A. vera* had no significant effect on glucose and cortisol levels at any rate in this study (Table 3) and cumulative mortality of fishes in *A. vera* treatments did not significantly ($p < 0.05$) differ compared to the control group (Figures 1 and 2). Zanuzzo et al. (2012) reported that addition of *A. vera* (0.02, 0.2 and 2 mg/ml⁻¹) in the transport water did not affect the level of blood glucose of *Brycon amazonicus* [6]. Taiwo et al. (2005) demonstrated that Nile Tilapia, *Oreochromis niloticus* juveniles exposed to water containing 50, 100

and 150 mg/L⁻¹ of the aqueous extract of *A. vera* leaves exhibited erratic swimming patterns, rapid opercular movements, skin depigmentation and died within 24-96 h [25]. Gross and histologic tissue lesions in the test fish include skin depigmentation, pale and shriveled gills, dull, opaque and sunken eyes, stunting and clubbing of gill filaments, vacuolar degeneration and necrosis of gill epithelial cells, hyaline degeneration and necrosis of myofibrils, calcification of vasa, hepatocellular vacuolar degeneration and necrosis. These authors explained that these complications might be emergent of high doses of applied *A. vera*. None of these complications were observed in the current study.

In most fishes, cortisol reaches the highest concentration 1 hour after being stressed and returns to basal levels after 6 hours [26]. Two hours after the beginning of hypoxia stress period, the glucose and cortisol levels in *S. officinalis* (0.5%) group was significantly higher than the control group at days 30 and 45 ($p < 0.05$), while other treatments didn't show the same effect. Moreover, *S. officinalis* (0.5%) group revealed significantly higher glucose levels compared to all rates of *A. vera* group at days 30 ($p < 0.05$) (Table 3). The increase of glucose level in the fish blood helps to satisfy the increased energy demand during stress, allowing the fish to react to stressors [6]. Hyperglycemia has been associated with stressful conditions such as hypoxia, capture, transport and crowding [27].

Cumulative fish mortality in *S. officinalis* (0.5% and 1%) treatment were significantly lower than the control group ($p < 0.05$) at the end of 6 hours hypoxia stress period at day 30 (Figures 1 and 2). The mortality rate was significantly lower only in *S. officinalis* (0.5%) treatment at day 45 compared to the control ($p < 0.05$) (Figure 2). Decreased mortality in *S. officinalis* treat-

ments is due to increase in total RBC, hematocrit, hemoglobin, glucose and cortisol levels which enhance the fish resistance towards hypoxia stress.

Taiwo et al. (2005) reported the *A. vera* as a toxic agent for tilapia and *O. niloticus* L. gills, but they consumed water containing the extract of raw *A. vera* leaves in static water, whereas in the current study hydroalcoholic *A. vera* and *S. officinalis* extracts supplemented diets were used for the rainbow trout [25]. Many researchers reported that *A. vera* and *S. officinalis* have benefits for histopathology of the liver [28], gonads [29] skin and gastrointestinal tract [17] of fish. In the current study various focal and multifocal changes including atrophy of secondary lamellas, degeneration and necrosis of lamellas, hyperemia, clubbed secondary lamellas, stunted gill filaments and subepithelial space edema were observed in gills of treated fish with different plant extract concentrations (Figures 3 and 4). All lesions observed in the treatment groups in this study were either light or moderate and the comparison of lesions represented no significant differences between treatments (Table 4).

The results found in this study suggest that *A. vera* and *S. officinalis*, two medicinal plants extensively used for humans [5], are two promising natural products for aquaculture and should be more investigated as modulators of the hematological parameters and anti-stress agents in fish farming, since their use in the rainbow trout fingerlings improved its hematological and biochemical responses against hypoxia stress.

Material and methods

Plant extraction

Aerial organs of *A. vera* and *S. officinalis* were collected from local areas in Khuzestan Province of Iran and identified in the Department of Botany, Faculty of Agriculture, Urmia University, Iran. After identification, the plants were washed in running tap water to remove debris and dust particles and then rinsed in distilled water. Plant samples were air-dried and ground. Twenty grams of ground powders from each plant was soaked in 100 ml solvent (a mixture of ethanol: distilled water 50:50%) for 15 min with occasional shaking at 60 °C. After they were dissolved, the materials were filtered through Buchner funnel and Whatman No. 1 filter paper. Then, the filtrates were evaporated using rotary evaporator and concentrated.

Identification of extracts' components by GC/MS

The GC/MS analyses were performed on a Thermo Finnegan capillary gas chromatograph directly coupled to the mass spectrometer system (model GC TRACE; TRACE MS plus) using HP-5MS non-polar fused silica capillary column (30 m × 0.250 mm, 0.25 µm film thickness). Temperature profile was as follows: at first, the temperature of the oven was fixed at 40°C for 2 min, and then increased to 160 °C with the temperature rate of 3 °C min⁻¹, and finally increased to 280 °C at 5 °C min⁻¹ for 2 min. The carrier gas was helium at a flow rate of 1 ml min⁻¹, and ionization energy

was 70 eV [30].

Fish and husbandry conditions

In this study, 900 fish with a mean weight of 10 ± 0.1 g were obtained from a local farm in Urmia, Iran and transferred to "Artemia and Aquaculture Research Institute" of Urmia University. The fish were disinfected with 3% sodium chloride for 5 min and acclimatized to the laboratory conditions for a week. Fish were randomly distributed into 21 PVC tanks filled with 150 liters of dechlorinated fresh flow (3.5 L m⁻¹) water of a deep well. Water temperature and dissolved oxygen were 14 ± 1 °C and 8.5 mg L⁻¹, respectively.

Diet preparation and feeding trial

Extruded commercial fish feed (Faradaneh Co., Shahrekord, Iran) was used during the study with 90% dry matter, 38% crude protein, 16% crude lipid, 10% ash, 3% fiber and 1.20% phosphorous in its composition. Each herbal extract (*A. vera* and *S. officinalis*) was sprayed on the commercial diets at 0.5, 1, and 1.5% of diets separately. Pellets were dried at room temperature and were stored at 4°C for further use. Each diet was fed to triplicate tanks three times daily for a period of 30 days. After feeding trial, diets were replaced by a normal pelleted diet without any plant extract until day 45.

Assessment of hematological parameters

Fifteen fish from each treatment were anesthetized by immersion in a clove powder (200 mg L⁻¹) solution, and blood samples were collected from the caudal vein of fish [31], at days 30 and 45. The blood samples were mixed with heparin to determine red blood cells (RBC) count, hematocrit, and hemoglobin. The RBCs were counted under a light microscope using Neubauer hemocytometer after dilution with phosphate-saline. The cells were identified on the basis of morphology and cell ultra-structure as documented in a previous study [32]. The hematocrit percentage was determined through the microhematocrit method, and hemoglobin concentration was determined using cyanomethemoglobin method [33].

Histopathology procedures

Immediately after feeding for the trial period (day 30), the fish were anesthetized with immersion in a solution containing clove powder (200 mg L⁻¹) [31] and then sacrificed by cervical section. The gill samples were excised, rinsed in physiological saline, and fixed in aqueous Bouin's fluid for 6, 8 and 12 hours, respectively. The tissues were dehydrated in an ethyl alcohol series of ascending concentrations, embedded in paraffin and sectioned at 5 µm. The tissue sections were stained with hematoxylin-eosin (HE) and were examined by a light microscope [34].

The presence of histological alterations for gill was evaluated semi-quantitatively by the degree of tissue change that is based on the severity of the lesions. For degree of tissue change the alterations in each organ were classified in progressive stages of damage to the tissue: stage I alterations, which do not alter the normal functioning of the tissue; stage II, which are mild-severe the normal functioning of the tissue; and stage III, which are more severe and cause irreparable damage. A value of the degree of tissue change for each treatment was calculated by the below formula:

$$\text{Degree of Tissue Change} = (1 \times \text{stage I}) + (10 \times \text{stage II}) + (100 \times \text{stage III})$$

(Where I, II and III correspond to the number of alterations of stages I, II and III, respectively).

Degree of tissue change values between 0 and 10 indicate normal functioning of the organ; values between 11 and 20 indicate

slight damage to the organ; values between 21 and 50 indicate moderate changes in the organ; values between 50 and 100 indicate severe lesions and values above 100 indicate irreversible damage to the organ [34].

Hypoxia stress and biochemical indices assay

In hypoxia stress, dissolved oxygen decreased to 3 mg L⁻¹ in stress tanks (each tank contained 40-liter water) via infusion of nitrogen gas into water at days 30 and 45; then 30 fish of each treatment (10 fish from each replication) were exposed to hypoxia stress (3 mg L⁻¹) for 6 hours and mortality was recorded each hour. Then, fish of each group were placed in tanks containing 40 L of aerated flow-through well water. All fishes were monitored for 1 h and dead fish were removed and added to mortality data. Then, the mortality rate was recorded for each group.

The blood samples were collected from selected fish of each treatment (from the caudal vein after euthanasia of fish by clove powder 200 mg L⁻¹) [31] exactly before and one hour after hypoxia stress and transferred into Eppendorf tubes and allowed to clot at room temperature for 1 h. Then, samples were kept at 4 °C for 5 h. The serum was separated by centrifugation (1500 g for 5 min at 4 °C) and used for the glucose and cortisol levels estimation. The glucose and cortisol were quantified by electrochemiluminescence method using Mindray biochemical auto analyzer (BS - 400), with kits supplied by Mindray biomedical electronics Co. Ltd Shenzhen, China.

Statistical analysis

All data were subjected to analysis of variance (SPSS v20, One-Way ANOVA) followed by Tukey's test ($p < 0.05$). Figures and tables were drawn with office 2013.

Acknowledgment

This work was supported by the Office of Vice Chancellor for Research, Urmia University, Iran, for PH.D thesis.

Author Contributions

Conceived and designed the experiments: A.A.T., S.M. Performed the experiments: A.A.T., A.T. M.A., F.N. Analyzed the data: A.A.T. Wrote the paper: A.A.T

Conflict of Interest

The authors declare no conflict of interest.

References

1. Castro SBR, Leal CAG, Freire FR, Carvalho DA, Oliveira DF, Figueiredo HCP. Antibacterial activity of plant extracts from Brazil against fish pathogenic bacteria. *Brazilian Journal of Microbiology*, 2008; 39(4): 756-760.
2. Maqsood S, Samoon MH, Singh P. Immunostimulatory and growth promoting effect of dietary levamisole in *Cyprinus carpio* fingerlings against the challenge of *Aeromonas hydrophila*. *Turkish Journal of Fisheries and Aquatic Sciences*, 2009; 9: 111-120.
3. Ahmad MH, Mesallamy AMD, Samir F, Zahran F. Effect of cinnamon (*Cinnamomum zeylanicum*) on growth performance, feed utilization, whole body composition, and resistance in Nile tilapia to *Aeromonas hydrophila*. *Journal of Applied Aquaculture*, 2011; 23: 289-298.
4. Subeena Begum S, Navaraj PS. Synergistic effect of plant extract supplemented diets on immunity and resistance to *Aeromonas hydrophila* in *Mystus*. *IOSR Journal of Pharmacy and Biological Sciences*, 2012; 2(4): 30-36.
5. Galina J, Yin G, Ardo L, Jeney Z. The use of immunostimulating herbs in fish. An overview of research. *Fish Physiology and Biochemistry*, 2009; 35: 669-676.
6. Zanuzzo FS, Biller-Takahashi JD, Urbinati EC. Effect of Aloe vera extract on the improvement of the respiratory activity of leukocytes of *matrinxa* during the transport stress. *Revista Brasileira de Zootecnia*, 2012; 41(10): 2299-2302.
7. Milenkovic MT, Bozic DD, Slavkovska VN, Lakusic BS. Synergistic Effects of *Salvia officinalis* L. Essential Oils and Antibiotics against Methicillin-resistant *Staphylococcus aureus*. *Archives of Biological Sciences Belgrade*, 2015; 67(3): 949-956.
8. Mahdavi M, Hajimoradloo A, Ghorbani R. Effect of Aloe vera extract on growth parameters of common carp (*Cyprinus carpio*). *World Journal of Medical Sciences*, 2013; 9(1): 55-60.
9. Khalil R, Li ZG. Antimicrobial activity of essential oil of *Salvia officinalis* L. collected in Syria. *African Journal of Biotechnology*, 2011; 10(42): 8397-8402.
10. Khare R, Upmanyu N, Jha M. Exploring the Potential Effect of Methanolic Extract of *Salvia officinalis* Against UV Exposed Skin Aging: In vivo and In vitro Model. *Current Aging Science*, 2019; 12: 1874-6098/19. DOI:10.2174/1874609812666190808140549
11. Yilmaz E, Coban D, Kirim B, Güler M. Effects of Extracts of Feed Additives Including Rosemary (*Rosmarinus officinalis*) and Aloe Vera (*Aloe barbadensis*) on the Growth Performance and Feed Utility of Nile Tilapia (*Oreochromis niloticus*). *Turkish Journal of Agriculture - Food Science and Technology*, 2019; 7(6): 866-870.
12. Tafi AA, Meshkini S, Tukmechi A, Alishahi M, Noori F. Immunological and Antistreptococcal Effects of *Salvia officinalis* and Aloe vera Extracts Supplemented Feed in Rainbow Trout (*Oncorhynchus mykiss*). *Journal of Kafkas Universitesi Veteriner Fakultesi Dergisi*, 2019; 24 (3): 365-370. DOI: 10.9775/kvfd.2017.18973
13. de Oliveira JR, Vilela PGDF, Almeida RBA, de Oliveira FE, Carvalho CAT, Camargo SEA, et al. Antimicrobial activity of noncytotoxic concentrations of *Salvia officinalis* extract against bacterial and fungal species from the oral cavity. *General Dentistry*, 2019; 67(1): 22-26. PMID: 30644826
14. Jabeen G, Manzoor F, Javid A, Azmat H, Arshad M, Fatima S. Evaluation of Fish Health Status and Histopathology in Gills and Liver Due to Metal Contaminated Sediments Exposure. *Bulletin of Environmental Contamination and Toxicology*, 2018; 100(4): 492-501.
15. Zorriehzakra MJ, Hj Mohd Daud H, Sharifpour I, Soltani M, Mehrabi MR, Kies F, et al. Histopathology survey of rainbow trout (*Oncorhynchus mykiss*) fry mortality syndrome in coldwater hatcheries and reared farms in Iran. *Journal of Survey in Fisheries Sciences*, 2018; 4(2): 58-72.
16. Alishahi M, Ranjbar MM, Ghorbanpour M, Peyghan R, Mesbah M, Razi Jalali M. Effects of dietary Aloe vera on some specific and none specific immunity in the common carp (*Cyprinus carpio*). *Iranian Journal of Veterinary Research*, 2010; 4: 189-195.
17. Heidarieh M, Mirvaghefi AR, Sepahi A, Sheikhzadeh N, Shahbazfar AA, Akbari, M. Effects of Dietary Aloe Vera on Growth Performance, Skin and Gastrointestinal Morphology

- gy in Rainbow Trout (*Oncorhynchus mykiss*). Turkish Journal of Fisheries and Aquatic Sciences, 2013; 13: 367-373.
18. Bolu SA, Babalola TO, Elelu, N, Ahmed RN, Oyetunde SA, Ademola PF, Jid-dah SA. Effects of supplemental Aloe vera gel in drinking water on some performance histology, hematology, serum constituents and growth of tur-key poults challenged with *Escherichia coli*. Wudpecker Journal of Agricul-tural Research, 2013; 2: 223-229.
 19. Zomorodian K, Ghadiri P, Saharkhiz MJ. Antimicrobial activity of seven essential oils from Iranian aromatic plants against common causes of oral infections. Jundishapur Journal of Mi-crobiology, 2015; 8(2): 1-6.
 20. Haghighi M, Sharif Rohani M, Sama-di M, Tavol M, Eslami M, Yusefi, R. Study of effects Aloe vera extract sup-plemented feed on hematological and immunological indices of rainbow trout (*Oncorhynchus mykiss*). Inter-national Journal of Advanced Biolog-ical and Biomedical Research, 2014; 2(6): 2143-2154.
 21. Farahi A., Kasiri M, Sudagar M, Solei-mani Iraei M, Zorriehzahra SMJ. Ef-fect of dietary supplementation of *Melissa Officinalis* and Aloe Vera on haematological traits, lipid oxidation of carcass and performance in rain-bow trout (*Oncorhynchus Mykiss*). Online journal of animal and feed re-search, 2012; 1: 1-5.
 22. Haukenes AH, Barton BA, Bolligs H. Cortisol responses of pallid sturgeon and yellow perch following challenge with lipopolysaccharide. Journal of Fish Biology, 2008; 72: 780-784.
 23. Tea J, Alderman SL, Gilmour KM. So-cial stress increases plasma cortisol and reduces forebrain cell prolifera-tion in subordinate male zebrafish (*Danio rerio*). Journal of Experi-mental Biology, 2018; 194894. doi: 10.1242/jeb.194894.
 24. Martinez-Porchas M, Martinez-Cor-dova LR, Ramos-Enriquez R. Cortisol and Glucose: Reliable indicators of fish stress. Pan-American Journal of Aquatic Sciences, 2009; 4(2): 158-178.
 25. Taiwo VO, Olukunle OA, Ozor IC, Oyejobi AT. Consumption of aque-ous extract of raw Aloe vera Leaves: histopathological and biochemical studies in rat and tilapia. African Jour-nal of Biomedical Research, 2005; 8: 169-178.
 26. Iwama GK, Afonso LOB, Vijayan MM. Stress in fishes. In: Evans, DH; Clai-borne, JB; (Eds.), The Physiology of fishes. 3th edition, 2006; Taylor and Francis, New York, USA, PP. 319-342.
 27. Hoshiba MA, Goncalves FD, Urbinati EC. Physiological stress responses of matrinxa (*Brycon amazonicus*) after chasing. Acta Amazonica, 2009; 39: 445-452.
 28. Zodape GV. Effect of Aloe vera juice on toxicity induced by arsenic in *Labeo rohita* (Hamilton). Journal of Applied and Natural Science, 2010; 2(2): 300-304.
 29. Kushwaha MP. Effects of Aloe vera (*Lil-iaceae*) on Gonad development in Nile tilapia, *Oreochromis niloticus* (L.) during intensive aquaculture. Interna-tional Journal of Fisheries and Aquatic Studies, 2013; 1(2): 56-60.
 30. Hussein HJ, Hameed IH, Hadi MY. Using gas chromatography-mass spectrometry (GC-MS) technique for analysis of bioactive compounds of methanolic leaves extract of *Lepidium sativum*. Research Journal of Phar-macy and Technology, 2017; 10(11): 3981-3989.
 31. Meshkini S, Tapy AA, Tokmechi A, Farhangpajou F. Effect of Chitosan on hematological parameters and stress resistance in rainbow trout (*Oncorhynchus mykiss*). Veterinary Re-search Forum, 2012; 3(1): 49-54.
 32. Jalali MA, Ahmadifar E, Sudagar M, Azari Takami G. Growth efficiency, body composition, survival and he-matological changes in great sturgeon (*Huso huso* Linnaeus, 1758) juveniles fed diets supplemented with different levels of Ergosan. Aquaculture Re-search, 2009; 40(7): 804-809.
 33. Davis KA, Maney DL, Maerz JC. The use of leukocyte profile to measure stress in vertebrates: a review ecolog-ists. Functional Ecology, 2008; 22: 760-772.
 34. Camargo MMP, Martinez CBR. His-topathology of gills, kidney and liver of a neotropical fish caged in an ur-ban stream. Neotropical Ichthyology, 2007; 5(3): 327-336.

تأثیر جیره غذایی حاوی عصاره آلوئه ورا و مریم گلی بر خون‌شناسی، آسیب‌شناسی بافتی و مقاومت در برابر شرایط کم‌اکسیژنی در قزل‌آلای رنگین کمان

علی اکبر طافی^۱، سعید مشکینی^۲، امیر توکمه چی^۳، مجتبی علیشاهی^۴، فرزانه نوری^۵

۱ گروه شیلات، دانشکده منابع طبیعی، دانشگاه ارومیه، ارومیه، ایران
۲ گروه بهداشت و کنترل مواد غذایی، دانشکده دامپزشکی، دانشگاه ارومیه، ارومیه، ایران
۳ گروه میکروبیولوژی، دانشکده دامپزشکی، دانشگاه ارومیه، ارومیه، ایران
۴ گروه علوم بالینی، دانشکده دامپزشکی، دانشگاه شهید چمران اهواز، اهواز، ایران
۵ گروه تکثیر و پرورش آبزیان، پژوهشکده آرتمیا و آبزی پروری، دانشگاه ارومیه، ارومیه، ایران

چکیده

این مطالعه به بررسی آثار عصاره‌های آلوئه ورا و مریم‌گلی روی شاخص‌های خون‌شناسی و بیوشیمیایی، آسیب‌شناسی بافتی و مقاومت در برابر تنش کم‌اکسیژنی در قزل‌آلای رنگین‌کمان پرداخته است. هفت تیمار از قزل‌آلای رنگین‌کمان (10 ± 0.1 g) با مقادیر ۰ (گروه شاهد)، ۰.۵٪، ۱٪ و ۱.۵٪ از عصاره‌های آلوئه ورا و مریم‌گلی به صورت ترکیب با غذای آنها به مدت ۳۰ روز تغذیه شدند و سپس به مدت دو هفته دیگر تغذیه همه ماهیان با غذای گروه شاهد ادامه یافت. در روزهای ۳۰ و ۴۵ گلوکز و کورتیزول سرم قبل و یک ساعت بعد از کل گلبول‌های قرمز، هماتوکریت و هموگلوبین اندازه‌گیری شد. در روزهای ۳۰ و ۴۵ گلوکز و کورتیزول سرم قبل و یک ساعت بعد از اعمال تنش کم‌اکسیژنی (mg L^{-1}) اندازه‌گیری شد. در انتهای آزمایش نمونه‌های بافت آبشش همه تیمارها برای آسیب‌شناسی بافتی تهیه شد. تیمار مریم‌گلی ۰.۵٪ افزایش معنی‌دار ($p < 0.05$) در تعداد گلبول‌های قرمز، هماتوکریت و هموگلوبین را در مقایسه با گروه شاهد نشان داد. در حالیکه تیمارهای آلوئه ورا ۱٪ و ۱.۵٪ در مقایسه با گروه شاهد افزایش معنی‌دار ($p < 0.05$) هماتوکریت و غلظت هموگلوبین را نشان دادند. پس از اعمال تنش کم‌اکسیژنی در روزهای ۳۰ و ۴۵، سطوح گلوکز و کورتیزول سرم فقط در تیمار مریم‌گلی ۰.۵٪ در مقایسه با گروه شاهد بطور معنی‌داری ($p < 0.05$) افزایش یافت. در تیمارها و گروه کنترل تغییرات آسیب‌شناسی بافتی جدی مشاهده نشد. بر اساس نتایج به دست آمده، تجویز خوراکی ۰.۵٪ عصاره آبی اتانولی مریم‌گلی موجب بهبود شاخص‌های خونی و بیوشیمیایی خون شده و مقاومت قزل‌آلای رنگین‌کمان را در برابر تنش کم‌اکسیژنی افزایش می‌دهد.

واژگان کلیدی

قزل‌آلای رنگین‌کمان، عصاره‌های گیاهی، تنش‌های محیطی، خون‌شناسی، آسیب‌شناسی بافتی