



## Sperm cells in peritoneal fluid of a ram with obstructive urolithiasis: First report

Ghader Jalilzadeh-Amin<sup>a</sup>, Bahram Dalir-Naghadeh<sup>a</sup>, Seyed Mohammad Hashemi-Asl<sup>b</sup>  
Yaser Nozohour<sup>a</sup>

<sup>a</sup> Department of Internal Medicine and Clinical Pathology, Faculty of Veterinary Medicine, Urmia University, Urmia, Iran.

<sup>b</sup> Department of Surgery and Diagnostic Imaging, Faculty of Veterinary Medicine, Urmia University, Urmia, Iran.

### ABSTRACT

Detection of sperm in the peritoneal fluid of animals is unusual and has not been reported in the literature. In this report, we describe the presence of sperm cells in the peritoneal fluid of a two-year-old ram. The ram was presented with dyspnea, reduced rumen contractions, a mild degree of dehydration, cyanotic mucosa, difficulty in standing, and anuria. Ancillary diagnostics, including ultrasonography, radiography, complete blood cell count, and abdominocentesis were performed. In the peripheral blood sample, no blood parasites were observed, although thrombocytosis with toxic neutrophilia, and atypical lymphocytes were seen in the blood smear. In radiographs, urolithiasis was confirmed just on the sigmoid flexure position. Ultrasound examination revealed a distended bladder and large amounts of free fluid within the peritoneal cavity. The electrocardiogram analysis showed the absence of P waves, bradycardia, wide QRS complexes, ST-segment elevation, and tented T waves. In the peritoneal fluid smears, a large number of spermatozoa, and increased inflammatory cells were observed. It was concluded that the trauma or rupture in colliculus seminalis, ductus deferens, or the urethra with urinary stones resulted in leakage of spermatozoa to the peritoneal cavity. To our knowledge, this is the first report of the presence of spermatozoa in the peritoneal fluid of large animals.

### Keywords

*Spermatozoa, peritoneal effusion, sheep, urogenital, urolithiasis*

Number of Figures: 2  
Number of Tables: 0  
Number of References: 13  
Number of Pages: 5

### Abbreviations

BCS: Body condition score  
EDTA: Ethylenediaminetetraacetic Acid  
WBC: White Blood Cell  
Hct: Hematocrit  
ECG: Electrocardiogram

## Case Description

In autumn 2021, a 2-year-old ram (Ghezel breed) from a sheep herd was referred to the veterinary teaching hospital of the School of Veterinary Medicine, Urmia University, Iran. The main complaints of the owner were the complete and sudden loss of appetite, painful and difficult urination, and urine dribbling in the past three days. The owner of the animal had used dexamethasone at an unknown dose before referring to the hospital.

The body condition was good (BCS: 3). The physical examination revealed a heart rate of 62 bpm, rectal temperature of 36.9 C°, arrhythmia heard on cardiac auscultation, dyspnea, cyanotic mucosa, and reduced rumen contractions. Attempts to take a urine sample were unsuccessful.

In the peripheral blood sample taken from the ear vein, no blood parasites were observed. Blood samples were collected from the jugular vein in vacuum tubes with 10% EDTA for a complete blood cell count. The results of the blood sample were as follows: WBC 14300 / $\mu$ l, segmented neutrophils 8400 / $\mu$ l, lymphocyte 1500 / $\mu$ l, monocyte = 1000/ $\mu$ l, Hct 33%, and thrombocytosis with toxic neutrophilia and atypical lymphocyte were seen on the blood smear. Urinary stones were observed only in radiographs, and due to the lack of access to the stones inside the urinary tract, identification of these stones was impossible.

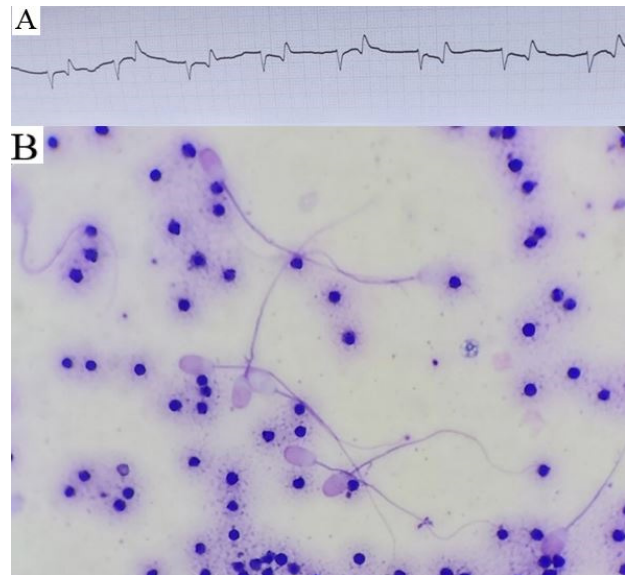
An ECG was recorded using a base-apex lead. A portable single-channel electrocardiograph (Nihon Kodhen, Japan) was used for recording. The lead selector was positioned on lead I, and the ECG was recorded with the paper speed of 25 mm sec<sup>-1</sup> and sensitivity of 10 mm = 1 mV.

The electrocardiogram analysis revealed an absence of atrial electrical activity (no discernible P waves), bradycardia (ventricular rate  $\approx$  60 bpm), and ST segment depression. These ECG changes might be attributable to hyperkalemia (Figure. 1-A).

Transabdominal ultrasound examination revealed the thickness of the bladder and proximal urethra wall, distended bladder with urine, and large amounts of free fluid within the peritoneal cavity. Ultrasound-guided abdominocentesis was carried out, and smears prepared from the recovered fluid revealed numerous inflammatory cells and abundant numbers of spermatozoa (Figure 1-B).

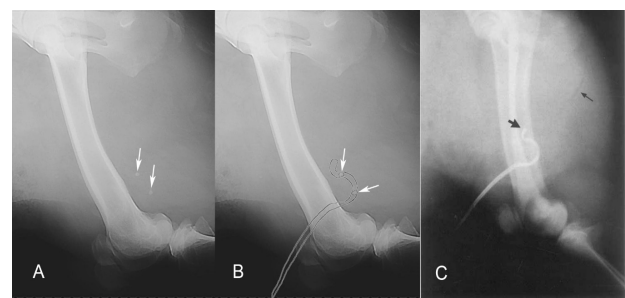
Radiographs were carried out from the pelvis and abdominal cavity in order to seek a more de-

tailed examination of the urinary tract and urethral path. Radiographs showed two radiopaque round calculi with dimensions of 4.2 mm lodged in the sigmoid flexure. Details of the radiographic findings are presented in Figure 2.



**Figure 1.**

A: ECG recorded from a 2-year-old ram with obstructive urolithiasis. Bradycardia, absence of P waves, wide QRS complexes, and depression of ST segment are seen in the figure. These findings might indicate increased serum potassium concentration, which is one of the most common laboratory abnormalities with uroperitoneum. Base-apex lead 25 mm/s, 10 mm=1 Mv. B: In the peritoneal fluid cytology (Wright-Giemsa stain; 100 $\times$ ), a large number of atypical cells containing basophilic granules and a large number of sperm were observed.



**Figure 2.**

A: lateral plain Radiography in a ram suspected to urethral calculi. Two radiopaque round matter with dimensions of 4.2 mm (stone) are seen (with arrow) just on the sigmoid flexure position. B: The same radiograph A in which the urethral track was drawn according to radiograph C.1 Radiopaque materials (stones) are marked with dotted lines and located (with an arrow) at the sigmoid flexure of the urethra. C: Radiograph 3. Positive contrast urethrography in a Nubian goat [1].

## Discussion

The Presence of spermatozoa in the peritoneal fluid has been extremely rarely reported, with only one case report of a 52-year-old man [2-3]. To the best of our knowledge, this report of sperm cells in peritoneal fluid from a ram is the first documented case in the veterinary medicine field.

The total number of WBCs, segmented neutrophils, and monocytes was more than the reference range. The maximum range for these parameters in sheep was reported as 8000/ $\mu$ l, 6000/ $\mu$ l, and 750/ $\mu$ l respectively. Neutrophilia or neutrophilic leukocytosis with the presence of toxic neutrophils was seen in this case. Extreme neutrophilia, exceeding upper reference limits, is usually seen in inflammation. In the acute stage of the inflammatory response, neutrophilia occurred with an increase along with a left shift and toxic changes. Although, the number of lymphocytes was lower than the normal range. Lymphopenia may occur with stress conditions, most commonly as a response to glucocorticoid secretion or corticosteroid administration, acute viral or bacterial infections, and endotoxemia. Atypical lymphocytes may be seen in response to antigenic stimulation because toxic neutrophils concurrently were detected in leucogram, which may appear as a response to infectious agents' antigens [4,5].

Various pathologic conditions cause fluid accumulation (effusion) in the peritoneal cavity [6 -9]. In cases with protein-losing enteropathy or nephropathy, lymphatic obstruction, and portal hypertension, transudates resulting from excess diffusion of water or lymph from the vascular space are a result of abnormalities of hydraulic or oncotic pressure [10]. Although inflammatory processes are caused by bacteria, some viruses, protozoa, parasites, neoplasms, foreign bodies, or uroperitoneum increase vascular permeability so that plasma exits the vasculature, often along with leukocytes [11, 12]. Effusions may be caused by a rupture of visceral organs, including those resulting from urinary tract rupture, biliary leakage, and gastrointestinal rupture. In early phases of the uroperitoneum, peritoneal effusion will have the character of urine as very low TP and total nucleated cell count, but with time and irritation to the peritoneum will take on characteristics of exudates with increased TP and total nucleated cell count, which may be diluted by high volumes of urine leakage [12]. Additional but less common effusions include lymphorrhage from lymphatic leakage in which multiple pathophysiological processes alter the character of the peritoneal fluid [12].

The precise mechanism by which sperm enters the peritoneal cavity in male animals and humans

remains unknown. In a report from a human with sperm in peritoneal fluid, specimen contamination during sample collection and processing, bladder rupture with retrograde ejaculation, sperm entering into the abdominal cavity, and incidental injury of vas deferens during paracentesis were considered as potential explanations for this observation. But none of these explanations could be plausible in our case. We aspirated peritoneal fluid from two different regions too far from the genital tract. In addition, sampling was performed using percutaneous ultrasound-guided abdominocentesis to avoid accidental puncture of intraabdominal structures; therefore, it seems unlikely that the peritoneal sample was contaminated with spermatozoa from vas deference or another storage site of spermatozoa.

The patient's history and clinical signs, along with ultrasonographic and radiographic findings, were consistent with obstructive urolithiasis and blockage of the urethra with stones and hydroperitoneum. However, the presence of spermatozoa within the peritoneal fluid is an abnormal finding and has not been reported so far from male animals following urolithiasis or any other disease. Uroperitoneum usually occurs secondary to rupture of the bladder; however, in our case, ultrasonography confirmed a distended and likely unruptured bladder.

In the male reproductive system, only the vas deferens (inside the scrotum or spermatic cord) is located inside the abdomen after originating from the epididymis and before entering the pelvic area and connecting with the pelvic urethra. This duct, together with the epididymis and its ampoule, is the main storage of sperm. Therefore, its rupture, along with the spermatic cord may cause sperm to enter the peritoneal cavity. Attributing the rupture of the urethra (in the pelvic part or its flexure) as the origin of the entry of sperm into the peritoneal fluid is not consistent with its anatomical position because only a small part of the urethra is inside the pelvis, and the other parts do not have a direct connection with the abdominal cavity to drain the sperm into the abdominal cavity [13]. On the other hand, with the possibility of pelvic urethral rupture, the entry of sperm from these parts into the peritoneal fluid is not easily conceivable because it is unlikely that the urethra has a sufficient population of sperm (sperm enters the urethra from its reservoir during ejaculation) unless there is an abnormal situation that causes a large number of sperm to enter the urethra or bladder by itself. Searching for sperm in urine was not possible. Otherwise, it could have helped to clarify this issue. It is also difficult to imagine the simultaneous occurrence of several unlikely possibilities without providing evidence. Likely, trauma or rupture in colliculus seminalis or ductus deferens and

pelvic urethral may be the origin of sperm leakage in the peritoneal cavity.

We assume that the lodging and passage of stones from colliculus seminalis and proximal or intrapelvic urethra damaged its wall (necrosis and rupture), and leakage of urine and spermatozoa to the peritoneal cavity occurred. In the geographic region covered in this report, the breeding season in sheep flocks starts in late summer and extends to the autumn. It is probable that due to the coincidence of mating season and increased pressure in the urethra following stone lodging, retrograde ejaculation resulted in leakage of urine and spermatozoa from the proximal urethra into the peritoneal cavity. However, due to the owner's disagreement to perform exploratory laparotomy or necropsy, we could not determine the exact origin of the injury or the leakage. If the animal's general condition is stable, surgery and removal of stones can be the correct method in dealing with similar cases.

It was concluded that trauma in the ductus deferens and or the perforation with urinary stones in the colliculus seminalis area or the pelvic segment of the urethra is the most likely cause of the appearance of spermatozoa in the peritoneal fluid.

## Acknowledgements

We thank Prof. Siamak Asri-Rezaei and all the technical staff of the Veterinary Hospital of Urmia

## Conflicts of Interest

The authors declare that there is no conflict of interest.

## Authors' Contributions

G.J., B.D., S.H., and Y.N. contributed to the sample preparation. G.J., B.D., S.H., and Y.N. contributed to the interpretation of the results. G.J. took the lead in writing the manuscript. All authors provided critical feedback and helped shape the research, analysis, and manuscript.

## References

- Palmer JL, Dykes NL, Love K, Fubini SL. Contrast radiography of the lower urinary tract in the management of obstructive urolithiasis in small ruminants and swine. *Veterinary Radiology & Ultrasound*.1998; 39(3):175-80. doi:10.1111/j.1740-8261.1998.tb00335.x.
- Olteanu H, Harrington A, Kroft SH. Sperm in peritoneal fluid from a man with ascites: a case report. *Cases J*. 2009; 2(1):1-3. doi:10.1186/1757-1626-2-192.
- Shen Q, Behera TR, Chen M, Wu M. Sperm in peritoneal effluent in a man undergoing peritoneal dialysis. *Nephrol*. 2019; 24(1):134. doi:10.1111/nep.13264.
- Leukogram Abnormalities in Animals. By: R. Darren Wood. In: MSD MANUAL Veterinary Manual. Access: <https://msdvetmanual.com/circulatory-system/leukocyte-disorders/leukogram-abnormalities-in-animals>.
- Hematology Reference Ranges. By: Susan E. Fielder. In: MSD MANUAL Veterinary Manual. Access: <https://www.msdvetmanual.com/special-subjects/reference-guides/hematology-reference-ranges>.
- Al-Rukibat RK; Bani Ismail ZA; Al-Majali AM; Al-Zghoul MB. Peritoneal fluid analysis in adult, nonpregnant Awassi sheep. *Veterinary Clinical Pathology*. 2006; 35(2): 215–218. doi:10.1111/j.1939-165x.2006.tb00117.x
- Adamu SS, Egwu GO, Malgwi TJ. Biochemical changes in the peritoneal fluid following rumenotomy in goats. *Vet Res Comm*. 1991; 15:363–367.
- Wilson AD, Hirsch VW, Osborne AD. Abdominocentesis in cattle: technique and criteria for diagnosis of peritonitis. *Can Vet J*. 1985;26: 74–80.
- Roussel AJ Jr, Ward DS. Ruptured urinary bladder in a heifer. *J Am Vet Med Assoc*. 1985;186:1310–1311.
- Corrigan R. *Fundamentals of Veterinary Clinical Pathology*, 2nd edition. *Can Vet J*. 2011 Feb;52(2):161. PMID: PMC3022453.
- Wilson DG, MacWilliams PS: An evaluation of the clinical pathologic findings in experimentally induced urinary bladder rupture in pre-ruminant calves, *Can J Vet Res*. 1998; 62:140–143.
- Christine B, Pugh DG. *Diseases of the gastrointestinal system*. In: *Sheep and Goat Medicine*. Philadelphia, PA: WB Saunders; 2002:71–72.
- Frandsen D, Wilke W, Lee F, et al. *Anatomy and Physiology of Farm Animals 7th edition* Publisher Wiley-Blackwell; 2009.

**COPYRIGHTS**

©2023 The author(s). This is an open access article distributed under the terms of the Creative Commons Attribution (CC BY 4.0), which permits unrestricted use, distribution, and reproduction in any medium, as long as the original authors and source are cited. No permission is required from the authors or the publishers.

**How to cite this article**

Ghader Jalilzadeh-Amin, Bahram Dalir-Naghadeh, Seyed Mohammad Hashemi-Asl, Yaser Nozohour. Sperm cells in peritoneal fluid of a ram with obstructive urolithiasis: First report. Iran J Vet Sci Technol. 2023; 15(4): 68-72.

DOI: <https://doi.org/10.22067/ijvst.2023.83689.1284>

URL: [https://ijvst.um.ac.ir/article\\_44408.html](https://ijvst.um.ac.ir/article_44408.html)