



Cimetidine-induced Male Reproductive Defects in Piroxicam-induced Gastric Ulcerated Wistar Rats and Their Amelioration by Melatonin

Afisu Basiru^a, Oluwatobi Chukwuebuka Adetunji^a, Ganiu Jimoh Akorede^b, Abdulfatai Aremu^b, Abdullahi Olaide Ishola^a, Aishat Omobolanle Olatunji^b

^a Department of Veterinary Physiology and Biochemistry, Faculty of Veterinary Medicine, University of Ilorin, Nigeria .

^b Department of Veterinary Physiology and Biochemistry, Faculty of Veterinary Medicine, University of Ilorin, Nigeria.

ABSTRACT

Cimetidine is a known reproductive toxicant due to its adverse effects on testicular function. Melatonin is an antioxidant that has a role in mitigating any disorders that could affect spermatogenesis. Therefore, this study evaluated the ameliorative potential of melatonin on the adverse reproductive effects of cimetidine in piroxicam-induced gastric ulcerated male rats. Thirty rats were randomly divided into six groups (n=5), including normal control (distilled water), ulcerated and non-treated, ulcerated and treated with cimetidine (200mg/kg day), ulcerated and treated with cimetidine and melatonin (10mg/kg), treated with cimetidine and melatonin without ulceration, and ulcerated rats treated with only melatonin. All treatments were done orally per day for 14 days. On the 15th day, rats were sacrificed, and blood samples were collected for hormone and antioxidant assays. Then, the sperm parameters were analyzed according to standard procedures. Co-administration of melatonin to piroxicam-ulcerated rats treated with cimetidine showed a significant increase ($p < 0.05$) in sperm count and epididymal glutathione peroxidase compared to piroxicam-ulcerated rats treated with only cimetidine. Melatonin increases the serum level of Testosterone, FSH, and LH. Melatonin ameliorates the adverse reproductive effects of cimetidine through its antioxidant properties. Therefore, co-administration of melatonin with cimetidine in male ulcer patients is recommended.

Keywords

Antioxidants, Cimetidine, Gastric ulcer, Melatonin, Sperm parameters.

Number of Figures: 4
Number of Tables: 2
Number of References: 36
Number of Pages: 9

Abbreviations

GU: Gastric ulceration
FDA: Federal Drug Agency
DHT: Dihydrotestosterone

NF: Nuclear Factor
COX-2: Cyclooxygenase-2
NO: Nitric oxide

Introduction

Gastric ulceration (GU) is the most prevalent gastrointestinal tract condition common among men and animals, with a global mortality rate of 1 out of every 1,000 complications every year [1]. It is a disruption or wound on the epithelial lining of the gastrointestinal tract. It is a benign injury to the mucosal wall of the intestine caused by the action of excessive stomach acid and pepsin on the mucosal epithelium, which can be acute or chronic in duration [2]. Helicobacter pylori infection and the use of nonsteroidal anti-inflammatory drugs are the most common predisposing factors for GUs [3].

Cimetidine is an FDA-approved drug that reduces gastric acid secretion, relieving symptoms such as peptic ulcers, gastroesophageal reflux, and hypersecretory disorders [4]. It works as an H₂ receptor antagonist, blocking the action of histamine and inhibiting gastric acid secretion.

In addition to its primary action in reducing gastric acid secretion, cimetidine competitively blocks dihydrotestosterone (DHT) receptors in various tissues, such as the pituitary gland, hypothalamus, and accessory glands, including the prostate and seminal vesicles, thereby impacting male hormone function and causing side effects such as loss of libido and impotence [5]. Cimetidine affects testicular function, reduces testicular weight, alters tubular structure, and causes the loss of germ cells [6]. It primarily targets peritubular cells and induces apoptosis. It can also cause testicular vascular atrophy and damage the testicular microvasculature.

Furthermore, cimetidine interferes with the nuclear factor (NF)- κ B pathway, impacting inflammation, immune responses, and apoptosis [7]. It affects the expression of cyclooxygenase (COX)-2 and inducible nitric oxide (NO) synthase (iNOS), which are involved in the inflammatory process and produce NO and reactive oxygen species, which in turn cause cell death and lipid peroxidation [8].

Melatonin is a hormone produced in the pineal glands of all mammals and is chemically named N-acetyl-5-methoxytryptamine. It is responsible for regulating the circadian rhythm sleep-wake cycle of mammals. Melatonin plays various additional roles, including its ability to mitigate inflammation, inhibit cell proliferation, and promote apoptosis. Furthermore, it modulates the immune system and plays a pivotal role in regulating glucose levels [9].

Melatonin functions in the release of gonadotropins from the anterior pituitary gland and gonads [10]. The antioxidant capacity of melatonin is crucial for preserving testicular function and preventing conditions that impair spermatogenesis. This is due to its ability to reduce the concentration of free radicals (ROS and NO), which can result in oxidative stress and destruction of the testicular epithelium, which is responsible for spermatogenesis. It serves as an antioxidant to improve sperm cell motility and membrane integrity. It also serves as a scavenger for the presence of ROS and NO in spermatocytes [9, 11]. This study was designed to evaluate the corrective potential of melatonin on the adverse reproductive effects of cimetidine in piroxicam-induced gastric ulcerated male rats.

Abbreviations - cont'd

iNOS: Inducible Nitric Oxide synthase
 ROS: Reactive Oxygen Species
 UERC/FVM: University Ethical Review Committee/Faculty of Veterinary Medicine
 DW: Distilled water
 ML: Melatonin
 U: Ulcerated
 UCM: Ulcerated treated with Cimetidine
 UCM+ML: Ulcerated treated with Cimetidine and Melatonin
 UML: Ulcerated and treated with melatonin
 CM+ML: treated with cimetidine and melatonin
 SOD: Superoxide Dismutase
 CAT: Catalase, GPx: Glutathione Peroxidase
 ALP: Alkaline Phosphatase
 LDH: Lactose Dehydrogenase
 ELISA: Enzyme-Linked Immunosorbent Assay
 H&E: Hematoxylin and Eosin
 ANOVA: Analysis of Variance
 BW: Body weight
 MBW: Mean Body Weight
 ASM: Abnormal Sperm Morphology
 StAR: Steroidogenic Acute Regulatory Protein Factor
 SF1: Steroidogenic factor 1.

Results

Body weight and relative organ weight

Melatonin increases the percentage of body weight. A higher percentage increase in BW was observed in the rats treated with melatonin (UCM+ML, CM+ML, and UML). The highest increase was found in the UML group (Table 1). Figure 1 shows the effects of melatonin coadministration on the relative organ weights of piroxicam-treated male Wistar rats. There was no significant difference in the relative weight of the right testis, left testis, epididymis, prostate gland, pituitary gland, or seminal vesicles among the experimental groups.

Sperm parameters

Melatonin improves the sperm parameters of piroxicam-ulcerated rats treated with cimetidine.

Cimetidine treatment of piroxicam-treated rats resulted in a significant ($p < 0.05$) reduction in sperm count and motility compared with those of ulcerat-

Melatonin protects against repro-toxicity by cimetidine

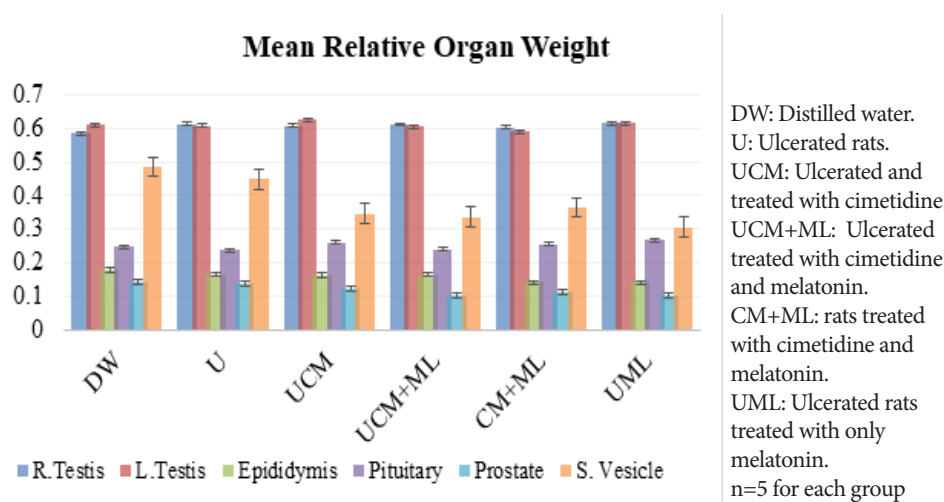
Table 1.

Melatonin increased the percentage of body weight

GROUPS	MBW day 1 (g)	MBW day 8 (g)	%MBW day 8	MBW day 14 (g)	%MBW day 14
DW	182.50	188.00	3.01	184.75	1.22
U	200.40	203.40	1.50	206.20	2.81
UCM	195.60	198.60	1.53	195.80	0.10
UCM+ML	186.20	195.00	4.73	192.40	3.22
CM+ML	205.50	212.00	3.16	212.00	3.07
UML	182.40	180.40	-1.10	189.80	3.90

n=5 for all the groups.

Keywords: MBW- Mean body weight, DW-Distilled water (control group), U-Ulcerated rats, UCM-Ulcerated rats administered cimetidine, UCM+ML-Ulcerated rats administered cimetidine and melatonin, CM+ML-Rats administered cimetidine and melatonin, UML-Ulcerated rats administered melatonin.

**Figure 1.**

Changes in the relative weights of the reproductive organs and pituitary following the coadministration of melatonin to ulcerated rats treated with cimetidine.

ed rats not given cimetidine. Compared with that in piroxicam-ulcerated rats treated with only cimetidine (UCM+ML), the sperm count in piroxicam-ulcerated rats treated with cimetidine (UCM) was significantly greater ($p < 0.05$) than that in piroxicam-ulcerated rats

treated with only cimetidine (UCM). There were no significant changes in the percentage of sperm with abnormal morphology, as shown in Table 2.

Antioxidant status in the pituitary, epididymis, and testis of piroxicam-ulcerated rats treated with cimetidine and melatonin

The effects of melatonin on the antioxidant profiles of the pituitary, epididymis, and testis of piroxicam-ulcerated rats treated with cimetidine are shown in Figure 2. The pituitary glutathione peroxidase (GPX) level was significantly lower ($p < 0.05$) in the ulcerated group (U), ulcerated rats treated with cimetidine (UCM), and ulcerated rats treated with cimetidine and melatonin (UCM+ML) than in the rats treated with distilled water (DW). Compared with rats treated with distilled water (DW), ulcerated rats treated with only melatonin (UML) presented a significant

($p < 0.05$) increase in pituitary catalase activity, as did ulcerated rats without any treatment (U). There was no significant difference in the pituitary SOD level between the treated groups and the control group.

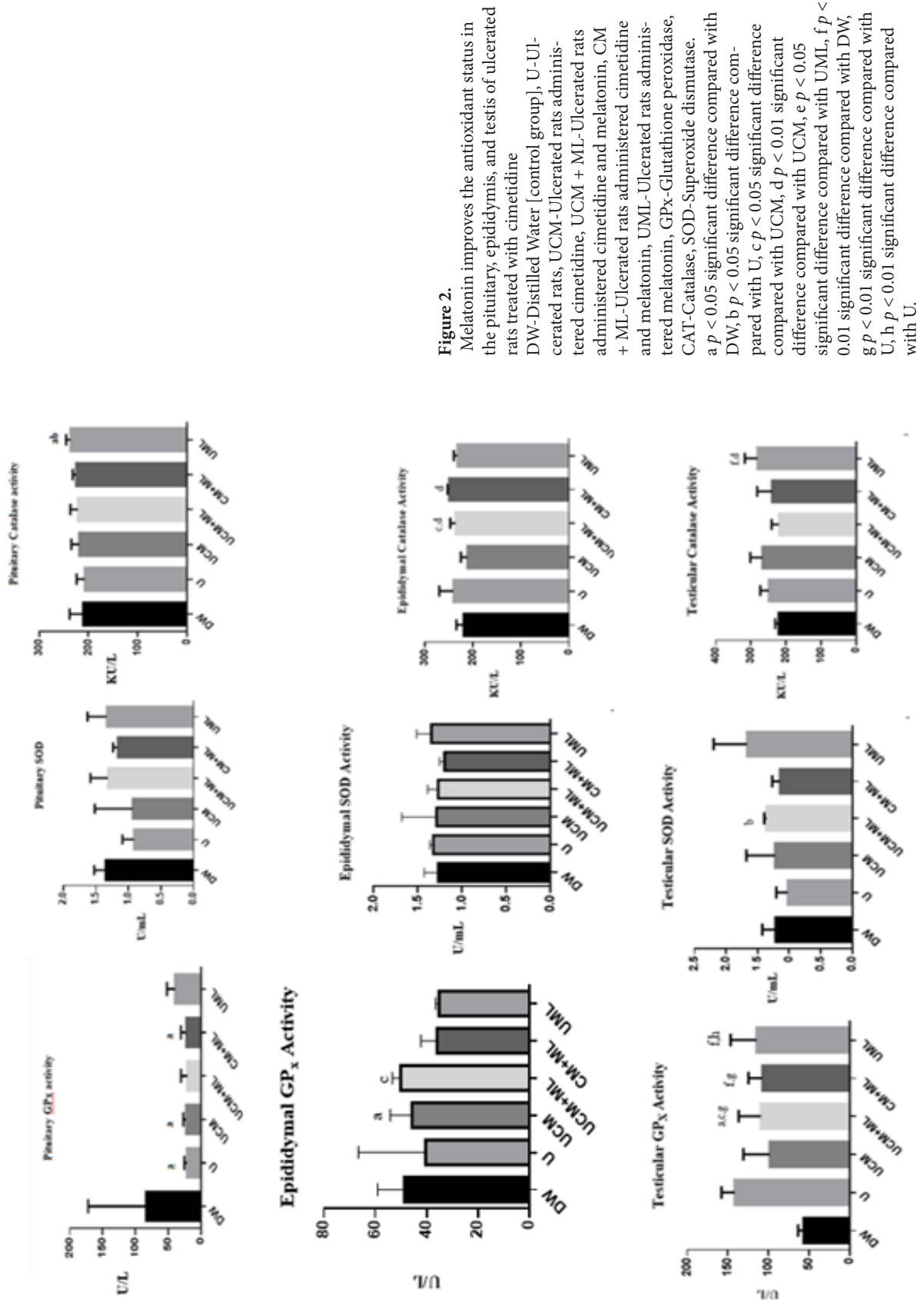
Compared with ulcerated rats treated with only

Table 2.

Melatonin improves the sperm parameters of piroxicam-treated rats treated with cimetidine

Parameters	DW	U	UCM	UCM+ML	CM+ML	UML
Sperm motility [%]	83.75 ± 11.09	70.00 ± 7.07	64.00 ± 8.94 ^b	66.00 ± 5.47 ^a	70.00 ± 0.00	62.00 ± 4.47 ^b
Sperm count [x10 ⁶ cells/ml]	138.00 ± 18.26	112.80 ± 9.757 ^a	103.40 ± 11.22 ^b	110.40 ± 13.58 ^{ac}	108.80 ± 9.935 ^a	101.40 ± 11.08 ^b
Sperm viability %	96.80 ± 1.64	94.20 ± 5.36	96.20 ± 1.64	96.20 ± 1.64	95.20 ± 3.27	76.20 ± 38.44
% ASM	12.17 ± 0.57	13.00 ± 1.45	13.45 ± 1.17	13.17 ± 0.83	13.05 ± 0.82	13.96 ± 0.56

ASM: Abnormal sperm morphology, a $p < 0.05$ significant reduction compared with DW, b $p < 0.05$ significant decrease in comparison with U, c $p < 0.05$ significant difference compared with UCM



cimetidine, ulcerated rats treated with cimetidine and melatonin presented a significant increase ($p < 0.05$) in the level of epididymal glutathione peroxidase, whereas the SOD level was not significantly affected by melatonin coadministration. Coadministration of melatonin to ulcerated rats treated with cimetidine caused a significant increase ($p < 0.05$) in epididymal catalase activity (UCM vs UCM+ML). Coadministration of melatonin to ulcerated rats treated with cimetidine caused a significant increase ($p < 0.05$) in testicular glutathione peroxidase (UCM+ML vs UCM). There was also a significant increase ($p < 0.05$) in testicular SOD activity in ulcerated rats treated with cimetidine and melatonin (UCM+ML) compared with untreated ulcerated rats (U). Melatonin administration to ulcerated rats (UML) caused a significant increase ($p < 0.05$) in testicular catalase activity compared with that in ulcerated rats treated with melatonin (UCM).

Testicular alkaline phosphatase and lactose dehydrogenase levels

Melatonin increases testicular alkaline phosphatase and lactose dehydrogenase. Melatonin administration to piroxicam-treated rats treated with cimetidine caused a significant increase ($p < 0.05$) in the testicular levels of alkaline phosphatase and lactose dehydrogenase, as shown in Figure 3.

Histopathological changes in the testes and epididymides of ulcerated Wistar rats treated with cimetidine and melatonin

The ductus epididymides of piroxicam-ulcerated rats treated with cimetidine presented empty pockets

characterized by complete absence to reduce sperm activity, as shown in Figure 4. Coadministration of melatonin to piroxicam-ulcerated rats treated with cimetidine (UCM+ML) caused the epididymis to be filled with a few sperm cells. The epididymides of piroxicam-ulcerated rats treated with only melatonin (UML) presented with sperm-filled ductus. Melatonin reversed the marked cellular degeneration and reduced spermatogenic activity observed in the photomicrograph of the testes of piroxicam-treated rats treated with cimetidine.

Discussion

Male reproduction is a complex process subjected to hormonal interplay regulated by the hypothalamic-pituitary-gonadal axis. Certain antiulcer drugs negatively impact the male reproductive system and result in infertility and subfertility in male species [22]. One of these drugs is cimetidine, an H₂-receptor antagonist that is commonly used as an antiulcer drug [23]. Melatonin involves multiple mechanisms to control cellular physiology, including via membrane receptors, nuclear binding sites, and interaction with cytosolic molecules. Melatonin acts through receptor and non-receptor pathways in testicular tissues, where it scavenges reactive oxygen species and increases the antioxidant body systems. Several studies have shown that sperm parameters (concentration, motility, and morphology) were positively correlated with exogenous administration of melatonin [24]. Several studies have shown that melatonin effectively ameliorates infertility in male humans and invariably in animals

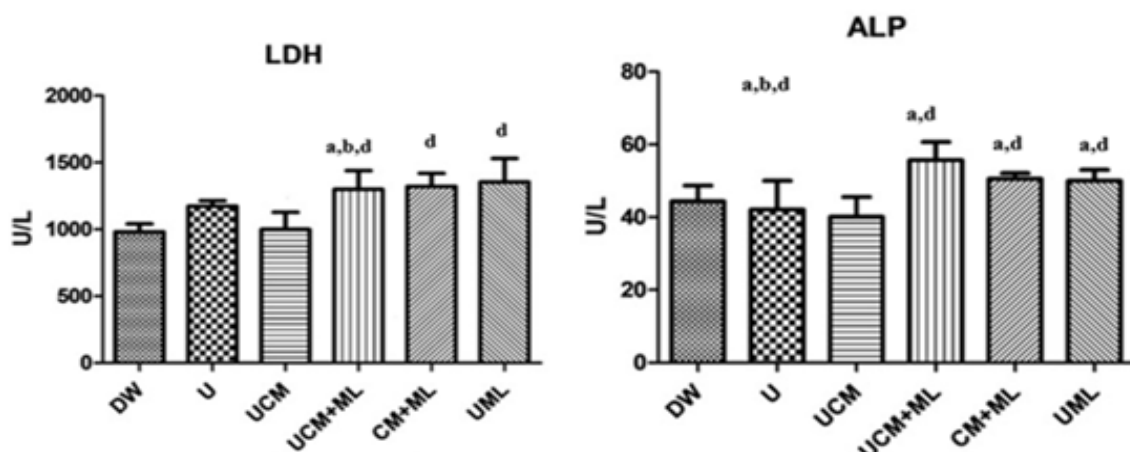


Figure 3. Testicular levels of lactose dehydrogenase and alkaline phosphatase DW-Distilled Water [control group], U-Ulcerated rats, UCM-Ulcerated rats treated with cimetidine, UCM+ML-Ulcerated rats treated with cimetidine and melatonin, CM+ML-Rats treated with cimetidine and melatonin, UML-Ulcerated rats treated with melatonin, LDH-Lactose dehydrogenase, ALP-Alkaline phosphatase. a $p < 0.05$, significant reduction compared with DW; b $p < 0.05$, significant difference compared with U; c $p < 0.05$, significant difference compared with UCM; d $p < 0.01$, significant difference compared with UCM.

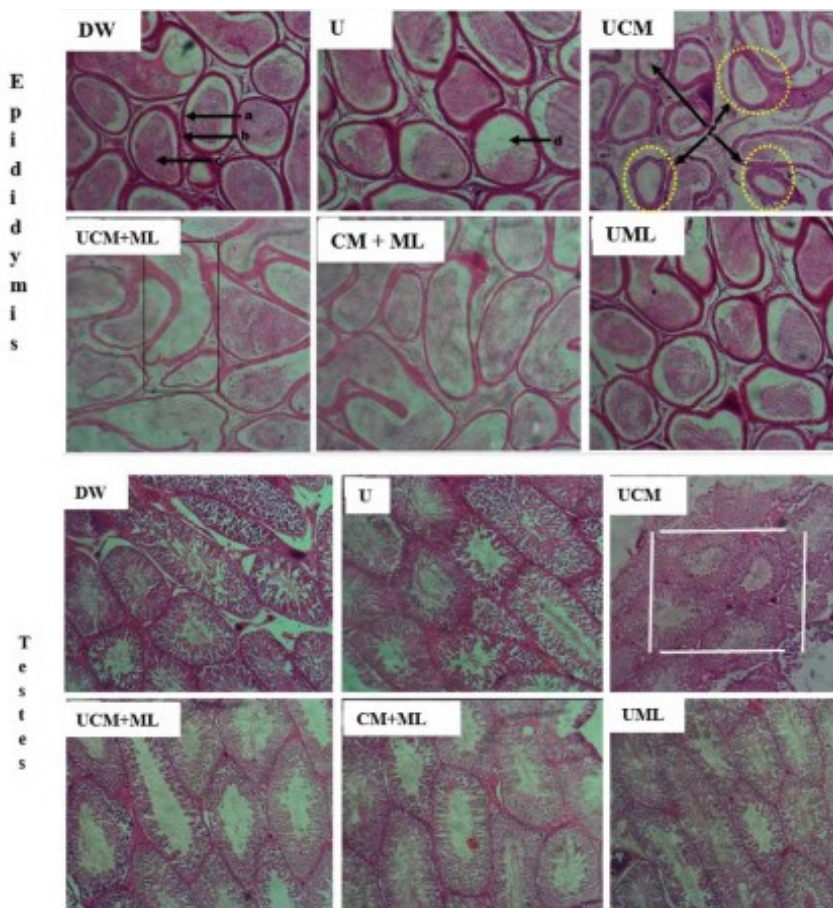


Figure 4. Changes in the relative weights of the reproductive organs and pituitary following the coadministration of melatonin to ulcerated rats treated with cimetidine.

based on its antioxidant properties and ability to regulate the circadian rhythm [25, 26]. The antioxidative properties of melatonin have been shown to ameliorate the toxic effects of tramadol, including hepatotoxicity, cholecystitis, and cholelithiasis, either by acting directly as an antioxidant or indirectly by increasing the concentration of other antioxidants in the body [14]. Because melatonin is lipophilic and hydrophilic, it is capable of crossing cell membranes, including the blood-testis barrier, thereby exerting its antioxidative influence on the reproductive system. Alcoholic patients exhibit a reduction in the endogenous melatonin blood concentration, resulting in stress-related disorders and other alcohol-related diseases. However, treatment with exogenous melatonin has been shown to mitigate these effects [27].

The findings of our study showed that melatonin consumption significantly improved feed consumption and invariably increased body weight.

The analysis of the mean body weight gain across all groups revealed an increase on days 8 and 14 compared with the mean body weight on day 1, except in the UML group, which later experienced a percentage increase in body weight on day 14. It was expect-

ed that there would be an increase in the body weight of rapidly growing rats administered the right feed in the right quantity and quality. Another study revealed that melatonin attenuated body weight gain in old female mice [28]. Moreover, the absence of melatonin led to overweight in rats [29]. The rat group with the lowest growth rate, as measured by the percentage increase in mean weight, was ulcerated and treated with cimetidine (UCM); on day 14, the percentage increase was 0.1%. In contrast, the three groups with the highest growth rates were the UML group [ulcerated rats administered melatonin – 3.9%], the UCM+ML group (ulcerated rats administered cimetidine and melatonin – 3.22%), and the CM+ML group (rats administered cimetidine and melatonin – 3.07%).

Cimetidine, an H₂-receptor blocker, has been shown to cause oxidative stress in sperm cells, resulting in abnormal-

ities in vital sperm parameters such as sperm morphology, sperm motility, and sperm count [23]. There was a significant reduction in the sperm motility of the ulcerated rats in the cimetidine (UCM) group, the ulcerated rats in the cimetidine and melatonin (UCM+ML) group, and the ulcerated rats in the melatonin (UML) group. There was a significant reduction in the sperm count in the U, UCM, UCM+ML, CM+ML, and UML groups.

LH, testosterone, and FSH are the three primary endocrine hormones that control testicular functions in mammals [19, 30]. LH in the pituitary activates the Leydig cells of the testes to produce testosterone, which then works with FSH to stimulate Sertoli cells and aids in initiating spermatogenesis. This promotes the progression of germ cells into spermatozoa and the nourishing of developing sperm cells [19]. In our study, the LH levels of ulcerated rats treated with melatonin and cimetidine (UCM+ML), rats treated with cimetidine and melatonin (CM+ML) and ulcerated rats treated with melatonin only (UML) were greater than those of unadministered melatonin. These findings indicate that melatonin aids in improving LH levels and thus aids in enhancing spermatogenesis.

This mechanism involves the suppression of Leydig cell apoptosis through the targeted action of melatonin on the mitochondrial apoptotic Bax/Bcl2 pathway, as indicated by signal transduction analysis [31]. Studies have shown that melatonin can improve spermatogenesis by mediating the upregulation of genes linked to testosterone synthesis, such as steroidogenic acute regulatory protein factor (StAR), steroidogenic factor 1 [SF1], and the transcription factor GATA-4, in Leydig cells [31].

The antioxidative property of melatonin is based on its ability to directly scavenge free radicals in body tissues [32] or indirectly scavenge free radicals by stimulating the activities of antioxidative enzymes. Superoxide dismutase (SOD) is the first line of antioxidant defense in the body and catalyzes the dismutation of O₂⁻ to H₂O₂. Catalase then abates oxidative stress by neutralizing H₂O₂ to H₂O and O₂ [33]. SOD is considered the most important antioxidant enzyme in spermatozoa, where it plays a key role in sperm motility [34]. GPx maintains cellular lipid integrity by catalyzing the reaction of hydrogen peroxide with glutathione to form glutathione disulfide [33].

The antioxidant enzyme catalase (CAT) level in the pituitary gland was greater in ulcerated rats treated with melatonin (UML) than in the other groups. These findings reveal the role of melatonin in modulating CAT for antioxidative action. Catalase is an antioxidant present in almost all tissues, especially tissues that use oxygen, and it catalyzes the decomposition of H₂O₂ to H₂O and O₂. The presence of catalase in the pituitary is because it can cross the blood-brain barrier, where it exhibits antioxidative properties [35].

Compared with those in the other groups, the level of GPx in the epididymis of ulcerated rats treated with cimetidine and melatonin (UCM+ML) was greater. The antioxidative properties of catalase in the epididymis were greater in the UCM+ML group [ulcerated rats treated with cimetidine and melatonin] and CM+ML group [rats treated with cimetidine and melatonin]. These findings indicate that melatonin plays a major role in alleviating the effects of oxidative stress present in the epididymis.

In the testes, the GPx level was higher in the rats co-administered melatonin, i.e., UCM+ML (ulcerated rats administered cimetidine and melatonin), CM+ML (rats administered cimetidine and melatonin) and UML (ulcerated rats administered melatonin only), but it was lower in the rats treated with cimetidine. This result is consistent with studies showing decreased levels of antioxidant enzymes in testicular and epididymal tissues due to oxidative stress generated by cimetidine [23]. The rats in the UML group presented the highest GPx activity; this

finding highlights the antioxidative properties of melatonin in modulating glutathione peroxidase activity. SOD, CAT, and LDH levels in the testes were greater in ulcerated rats coadministered melatonin (UML) than in the other groups, further revealing the antioxidative properties of melatonin through the modulation of SOD, CAT, and LDH in the testes. Alkaline phosphatase is an important enzyme needed for the biosynthesis of macromolecules, as well as for detoxification and the regulation of metabolic processes [33]. The alkaline phosphatase (ALP) level in the testes was greater in non-ulcerated rats concurrently administered cimetidine and melatonin (CM+ML) than in any other group.

In conclusion, the administration of cimetidine to piroxicam ulcerated rats induced oxidative stress in the epididymis, pituitary gland, and testis while also reducing the epididymal sperm count and motility. Cimetidine also disrupts the histological structure of the epididymis and testis. Melatonin coadministration reversed the alterations in the antioxidant system and improved the sperm parameters and histoarchitecture of the epididymis and testis. Therefore, melatonin coadministration with cimetidine is recommended for male ulcer patients who are in active reproductive life.

Materials & Methods

Chemicals and consumables

The following chemicals were purchased: Piroxicam capsule (Wintech Pharmaceuticals, Plot No. 45--46, Stice, Musalgaon, Nashik, Maharashtra, India, 422112. Mfg Llc. No. NKD-66, NAFDAC reg No. B4-7357), and cimetidine tablets (Manufactured by New Divine Favour Pharmaceutical Industries LTD, Anambra State, Nigeria. BN: NDF/NCC/0037, NAFDAC Reg. No: A4-218), melatonin powder (Glenthams Life Sciences, UK. Batch number: 001ZDK), ethanol, diethyl ether, eosin/nigrosine stains, wells and agar stains, phosphate buffer solution, and ethylene diamine tetra acetic acid (EDTA). The following kits were also used: a Testosterone ELISA kit (Calbiotech, Catalogue no: TE187S, USA), Luteinizing Hormone (LH) ELISA kit (Calbiotech, Catalogue no: LH231F, USA), Follicle Stimulating Hormone (FSH) ELISA kit (Calbiotech, Catalogue no: FS046F, USA), Rat PRL (Prolactin) ELISA Kit (Elabscience, Catalogue No: E-EL-R3006, USA), SOD Fortress diagnostic kit (Fortress Diagnostics Limited, UK, product code: BXC0173), CAT Fortress diagnostic kit (Fortress Diagnostics Limited, UK, product code: BXC0173), GPx Fortress diagnostic kit (Fortress Diagnostics Limited, product code: BXC0551), ALP Fortress diagnostic kit (Fortress Diagnostics Limited, UK, product code: BXC0183A), LDH Biorex diagnostic kit (Biorex Diagnostic Limited, UK product code: BXC0242), ELISA plate reader (UV/VIS 752, Pec Medical, USA), and Electronic balance (Golden-Mettler®, USA).

Animal Care

Thirty (30) adult male Wistar rats were housed in a perforated

plastic cage with wood bedding at an optimum room temperature of 24°C +/- 2°C to acclimatize the Wistar male rats to laboratory conditions. The rats were obtained from the Biochemistry Department Faculty of the Faculty of Life Sciences, University of Ilorin. The rats were fed commercial pelletized grower feed (Vital® feeds), and portable water was provided ad libitum. This study was approved, and ethical approval no (UERC/FVM/15/32TA010) was assigned by the faculty of veterinary medicine ethical review committee.

Experimental design

Preliminary ulcer induction

Three rats were randomly chosen for the preliminary study of ulcer induction. The mice were administered 30 mg/kg of piroxicam and then sacrificed after 14 days. Ulcer indices were then measured, and it was confirmed that piroxicam could induce ulcers in rats treated with 30 mg/kg piroxicam [12].

Dosing protocol

The rats were randomly assigned to six groups (five rats each). The first group served as a control and was administered distilled water only (DW 3 ml/kg BW). Group 2 (U) was ulcerated with piroxicam at 30 mg/kg BW. Group 3 (UCM) was ulcerated with 30 mg/kg piroxicam and treated with 200 mg/kg cimetidine [13]. Groups 4 (UCM+ML) and 5 (CM+ML) were treated with 200 mg/kg cimetidine and 10 mg/kg melatonin [14], but only group 4 was ulcerated with 30 mg/kg piroxicam. Group 6 (UML) was ulcerated with 30 mg/kg piroxicam and treated with only melatonin (10 mg/kg BW) [15]. The duration of this treatment lasted for fourteen days.

Sperm analysis

Sperm collection: The epididymis was excised, and the caudal epididymis was squeezed as described by [16] and then placed in a Petri dish. Before the evaluation of the sperm parameters, the diluted sperm were incubated for 10 minutes at 32 °C in physiological saline.

Sperm parameter evaluation: Sperm motility, the live-dead ratio, the sperm count, the sperm volume, and morphology were determined on the basis of the principles of [17] and [18]. Sperm motility was assessed with a microscope [Olympus®] at 40x magnification. Motile and nonmotile spermatozoa were counted. Sperm motility was determined on the basis of the percentage of motile to total spermatozoa counted [18]. The epididymal sperm count was determined with the aid of a haemocytometer. Five milliliters [5 mL] of the diluted sperm was placed on the central square of the Neubauer counting chamber. The sperm cells were counted by viewing [at 40x magnification]. The 5 squares of the Neubauer counting chamber were observed under a microscope. The result was expressed as a 1 million/1 ml sample size [18]. The sperm morphology was determined by smearing the sperm on a glass slide and allowing it to air dry overnight. The sperm were further stained with 1% eosin-Y/5% nigrosine. The specimen was then viewed under a microscope at 100x magnification for the observation of spermatozoa with abnormal morphology, such as headless tails, looped tails, rudimentary tails, curved tails, curved midpieces, and bent midpieces [18].

Blood collection and serum preparation

Blood was drawn into an EDTA-filled sample bottle from experimental rats that had been anesthetized with a combination of xylazine and ketamine via their orbital sinus. The collected blood was kept undisturbed for half an hour on the laboratory bench.

After that, the mixture was centrifuged at 2000 × g for 10 minutes. The supernatant was collected with a pipette and kept at -4 °C until use.

Tissue sample preparation

The tissue samples were placed into a table mortar and pounded with a pestle to form a homogenate before they were subsequently placed in plain sample bottles and spun at 5000 rpm for 30 min via a centrifuge [Axiom Medical Ltd., UK]. The supernatants were dispensed into Eppendorf tubes via a Pasteur pipette and then analysed for antioxidant levels.

The antioxidant levels of superoxide dismutase [SOD], catalase [CAT], and glutathione peroxidase [GPx] in the epididymis, testes, and pituitary gland were assessed. SOD, CAT, and GPx were analysed by using a SOD Fortress diagnostic kit [Fortress Diagnostics Limited, UK; product code: BXC0173], a CAT Fortress diagnostic kit [product code: BXC0173], and a GPx Fortress diagnostic kit [product code: BXC0551], respectively, following the guidelines of the kit manufacturers.

An alkaline phosphatase [ALP] Fortress diagnostic kit [produced by Fortress Diagnostics Limited, UK; product code: BXC0183A] was used to measure ALP. The rate at which p-nitrophenol is formed through the reaction of alkaline phosphatase and p-nitrophenyl phosphate is closely correlated with alkaline phosphatase levels.

A lactate dehydrogenase [LDH] Biorex diagnostic kit [Biorex Diagnostic Limited, UK product code: BXC0242] was used to measure lactate dehydrogenase.

Hormone assay

Serum levels of testosterone, follicle-stimulating hormone, luteinizing hormone, and prolactin were measured via an enzyme-linked immunosorbent assay (ELISA) kit that is specific for each hormone to be assayed [19]. The ELISA kit manual was strictly adhered to during the procedure. Briefly, the ELISA principle is based on the following antigen-antibody response: the antigen, which is the blood sample, and the antibody, which is the precoated microwell for the specific ELISA hormone kit. Serum was added with the aid of an automatic pipette into the precoated microwells and then allowed to rest for an hour for the antibody-antigen reaction to take place before the plate was loaded into the automatic plate reader.

Histopathology

For histopathological changes, the testes and epididymides were first fixed in 10% buffered formaldehyde, dehydrated with increasing ethanol concentrations, and embedded in molten paraffin wax. Thin sections of the paraffin-embedded tissue were cut, collected on glass slides coated with glycerin egg albumin, and labelled. These sections were dried, stained with hematoxylin and eosin [H&E], dehydrated, and cleaned. A glass coverslip was placed over the tissue sections with a mounting medium, and the slides were examined under a light microscope and photographed to identify any histopathological changes [20].

Body weight and organ weight determination

The mean body weight was determined via a Metler balance on days 1, 8, and 14 across all groups, and the percentage mean body weight was calculated.

The mean organ weights of the right testis, left testis, left epididymis, liver, spleen, kidney, pituitary gland, prostate gland, and

seminal vesicle of the experimental rats were also measured, and the relative organ weights in terms of body weight were also measured [21].

Statistical analysis

The body weight data are expressed as percentages, while the relative organ weights are presented as simple bar charts. Other data are presented as the means \pm standard deviations (means \pm SDs). ANOVA was used to analyse the data, while the significance level was evaluated via Tukey's multiple comparisons test with the aid of GraphPad Prism® [version 8.3.0, GraphPad® Software, www.graphpad.com]. The values were deemed statistically significant at $p < 0.05$.

Authors' Contributions

BA and ACO: conceptual development and Design. BA, AA, and ACO: Methodology and literature search. ACO, OAO: dosing of the rats and daily management of rats. BA, ACO, AGJ, AA, IAO, and OAO: rat sacrifice, sample collection and sample processing. BA, ACO and AGJ: data analysis and manuscript drafting. AA, BA and OAO: Manuscript review and final copy.

Acknowledgements

The authors acknowledge the support of Mr. Bolaji and Afolabi of the Department of Veterinary Pathology, University of Ilorin, regarding the histopathology of the testis and epididymis in this work.

Conflict of interest

The authors declare that there is no conflict of interest.

References

- Sabiu S, Garuba T, Sunmonu TO, Sulyman AO, Ismail NO. Indomethacin-induced gastric ulceration in rats: Ameliorative roles of *Spondias mombin* and *Ficus exasperata*. *Pharma Bio*. 2016;54:180-186. Doi: 10.3109/13880209.2015.1029050.
- Han S, Lu Y, Xie J, Fei Y, Zheng G, Wang Z et al. Probiotic Gastrointestinal Transit and Colonization After Oral Administration: A Long Journey. *Front cell infect microbiol*. 2021;11:609722. Doi: 10.3389/fcimb.2021.609722.
- Irshad Z, Sajjad Khan M, Kamran, Sohail M, Fahim M, Naeem S et al. Role of *Helicobacter pylori* Infection and Non-steroidal Anti-Inflammatory Drug Use in Bleeding Peptic Ulcers: Anti-Inflammatory Drug Use in Bleeding Peptic Ulcers. *Pakistan J H Sci*. 2023;4(3):147-51. Doi:10.54393/pjhs.v4i03.555.
- Brogden RN, Heel RC, Speight TM, Avery G S. Cimetidine: A Review of its Pharmacological Properties and Therapeutic Efficacy in Peptic Ulcer Disease. *Drugs*. 1978;15:93-131. Doi: 10.2165/00003495-197815020-00002.
- Adelakun SA, Ogunlade B, Akintunde OW, Omilachi VO. Long-term exposure to cimetidine induced gonado-toxicity in male rats: Modulating role of *Ocimum gratissimum*. *Rev Int Androl*. 2022;20 Suppl 1:S2-S16. Doi: 10.1016/j.androl.2020.10.012.
- Beltrame FL, Sasso-Cerri E. Vitamin B12-induced spermatogenesis recovery in cimetidine-treated rats: effect on the spermatogonia number and sperm concentration. *Asian J Androl*. 2017;19:567-672. Doi: 10.4103/1008-682X.182397.
- Aprioku JS, Ibeachu C, Amah-Tariah FS. Differential effects of H2 receptor antagonists on male reproductive function and hepatic enzymes in Wistar rats. *Asian J Biomed Pharm Sci*. 2014;4:1-6.
- Adelakun SA, Ogunlade B, Akintunde OW, Omilachi VO. Long-term exposure to cimetidine induced gonado-toxicity in male rats: Modulating role of *Ocimum gratissimum*. *Rev Int Androl*. 2022;20, Suppl 1: S2-S16. Doi: 10.1016/j.androl.2020.10.012.
- Rocha CS, Rato L, Martins AD, Alves MG, Oliveira PF. Melatonin and Male Reproductive Health: Relevance of Darkness and Antioxidant Properties. *Curr Mol Med*. 2015;15(4):299-311. Doi: 10.2174/1566524015666150505155530.
- Reiter RJ, Rosales-Corral SA, Manchester LC, Tan DX. Peripheral reproductive organ health and melatonin: Ready for prime time. *Int J Mol Sci*. 2013;14(4):7231-7272. Doi: 10.3390/IJMS14047231.
- Sohrabi G, Malmir M, Ghafarizadeh, A. Ameliorative Effect of Melatonin Versus the Passage of Time and Lipid Peroxidation on Sperm Motility in Asthenotratospermic Men. *Jorjani Biomed J*. 2021;9:44-54. Doi: 10.29252/jorjanibiomedj.9.1.44.
- Ibrahim H, Metwaly E, Galal A, Sherif S. Potential Curative Effect of Curcumin on Gastric Ulcer Induced by Piroxicam in Male Albino Rats. *Zagazig Vet J*. 2019;47:378-387. Doi: 10.21608/zvjz.2019.14389.1056.
- Kolawole TA, Dapper DV, Oluwatayo BO, Wali CA. Effects of Methanolic Extract of the Rind of *Lanatus* (Watermelon) in Aspirin induced Gastric Ulceration in Male Wistar Rats. *Merit Res J Med Med Sci*. 2016;47:344-350.
- Adikwu E, Bokolo B. Melatonin and n- acetylcysteine as remedies for tramadol-induced hepatotoxicity in albino rats. *Adv Pharm Bull*. 2017;7:367-374. Doi: 10.15171/apb.2017.044.
- Basu AN, Mitra EL, Mukherjee DE, Ghosh AK, Firdaus SB, Ghosh DE, et al. Aqueous tulsi leaf [*Ocimum sanctum* L.] extract protects against piroxicam-induced gastric ulceration in rats: involvement of antioxidant mechanisms. *Int J Pharm Pharm Sci*. 2013;5(1):437-447.

16. Basiru A, Aremu A, Azeez OM, Soetan KO, Olayemi FO. In Vivo bioactivity-guided isolation of antifertility fraction of *Waltheria indica* Linn root in male Wistar rats. *Future J Pharm Sci.* 2021;1-9. Doi: 10.1186/s43094-021-00228-0.
17. Kamal EM, Anees LM. Ameliorative role of melatonin against cypermethrin or gamma irradiation induced testicular damage in male rats. *Inter J Rad Res.* 2020;18:765-776. Doi: 10.18869/acadpub.ijrr.18.4.765.
18. Motahareh K, Nematollah A, Ebrahim M, Fatemeh S. Ameliorative Effect of Melatonin Against Reproductive Toxicity of Tramadol in Rats via the Regulation of Oxidative Stress, Mitochondrial Dysfunction, and Apoptosis-related Gene Expression Signalling Pathway. *Addict Health.* 2020;12:118-129. Doi: 10.22122/ahj.v12i2.265.
19. Owumi SE, Aliyu-Banjo NO, Odunola OA. Selenium attenuates diclofenac-induced testicular and epididymal toxicity in rats. *Andrologia.* 2020;52[9]. Doi: 10.1111/and.13669.
20. Musumeci G. Past, present and future: Overview on Histology and histopathology. *J Histol Histopathol.* 2014;1:5. Doi:10.7243/2055-091X-1-5.
21. Muratoğlu S, Akarca Dizakar OS, Keskin Aktan A, Ömeroğlu S, Akbulut KG. The protective role of melatonin and curcumin in the testis of young and aged rats. *Andrologia.* 2019;51:e13203.
22. Sands K, Jansen R, Zaslau S, Greenwald D. Review article: the safety of therapeutic drugs in male inflammatory bowel disease patients wishing to conceive. *Aliment Pharmacol Ther.* 2015;4:821-834. Doi: 10.1111/apt.13142.
23. Semet M, Paci M, Saïas-Magnan J, Metzler-Guillemain C, Boissier R, Lejeune H, et al. The impact of drugs on male fertility: a review. *Andrology.* 2017;5:640-663. Doi: 10.1111/andr.12366.
24. Replace with this "Yong W, Ma H, Na M, Gao T, Zhang Y, Hao L, Yu H, Yang H, Deng, X. Roles of melatonin in the field of reproductive medicine. *Biomed Pharmacother.* 2021;144:112001. Doi: 10.1016/j.biopha.2021.112001.
25. Yang M, Guan S, Tao J, Zhu K, Lv D, Wang J, Li G, Gao Y, Wu H, Liu J, Cao L, Fu Y, Ji P, Lian Z, Zhang L, Liu, G. Melatonin promotes male reproductive performance and increases testosterone synthesis in mammalian Leydig cells†. *Biol Reprod.* 2021;104(6):1322-1336. Doi:10.1093/biolre/ioab046.
26. Sun TC, Li HY, Li XY, Yu K, Deng SL, Tian L. Protective effects of melatonin on male fertility preservation and reproductive system. *Cryobiol.* 2020;95:1-8.
27. Li T, Lv Y, Wu Z, Guo, M., Liu R, Zeng W, Zheng Y. Systematic assessment of hexavalent chromium-induced damage to male fertility and the preventive role of melatonin: a longitudinal study from the translational point of view. *Mol Hum Reprod.* 2023; 29: gaad020. Doi:10.1093/molehr/gaad0.
28. Kurhaluk N. Alcohol and melatonin. *Chronobiol Int.* 2021;38:785-800. Doi: 10.1080/07420528.2021.1899198.
29. Tamura I, Tamura H, Kawamoto-Jozaki M, Doi-Tanaka Y, Takagi H, Shirafuta Y, et al. Long-term melatonin treatment attenuates body weight gain with aging in female mice. *J Endocrinol.* 2021;251:15-25. Doi: 10.1530/JOE-20-0462.
30. Buonfiglio D, Parthimos R, Dantas R, Cerqueira Silva R, Gomes G, Andrade-Silva J, et al. Melatonin Absence Leads to Long-Term Leptin Resistance and Overweight in Rats. *Front Endocrinol [Lausanne].* 2018;9:122. Doi: 10.3389/fendo.2018.00122.
31. Chen Y, Tang Y, Liu B, Wang J, Wang H, Li B, Liu S, Adeniran SO, Zheng P. Melatonin alleviates oxidative stress and inflammation of Leydig cells of Min pig through SIRT1 pathway. *Theriogenology.* 2025; 233:112-122. Doi:10.1016/j.theriogenology.2024.11.021.
32. Minghui Y, Shengyu G, Jingli T, Kuanfeng Z, Dongying L, Jing W, et al. Melatonin promotes male reproductive performance and increases testosterone synthesis in mammalian Leydig cells. *Bio Repro.* 2021;104(6):1322-1336. Doi: 10.1093/biolre/ioab046.
33. Korkmaz A, Reiter R, Topa, T, Manchester L, Oter S, Tan, D. Melatonin: an established antioxidant worthy of use in clinical trials. *Mol Med.* 2009;15:43-50.
34. Jebur AB, El-Demerdash FM, Kang W. Bromelain from *Ananas comosus* stem attenuates oxidative toxicity and testicular dysfunction caused by aluminum in rats. *J Trace Elements Med Bio.* 2020;62. Doi: 10.1016/j.jtemb.2020.126631.
35. Dehdari Ebrahimi N, Sadeghi A, Ala M, Ebrahimi F, Pakbaz S, Azarpira N. Protective effects of melatonin against oxidative stress induced by metabolic disorders in the male reproductive system: a systematic review and meta-analysis of rodent models. *Front Endocrinol (Lausanne).* 2023;14:1202560. Doi: 10.3389/fendo.2023.1202560.
36. Dare BJ, Oyeniyi F, Olaniyan OT. Role of Antioxidants in Testicular Integrity. *Annu Res Rev Biol.* 2014;4(7):998-1023.

COPYRIGHTS

©2025 The author(s). This is an open access article distributed under the terms of the Creative Commons Attribution (CC BY 4.0), which permits unrestricted use, distribution, and reproduction in any medium, as long as the original authors and source are cited. No permission is required from the authors or the publishers.

**How to cite this article**

Basiru A, Adetunji CO, Akorede GJ, Aremu A, Ishola AO, Olatunji AO. Cimetidine-induced Male Reproductive Defects in Piroxicam-induced Gastric Ulcerated Wistar Rats and Their Amelioration by Melatonin. Iran J Vet Sci Technol.2025; 17(1): 64-74.

DOI: <https://doi.org/10.22067/ijvst.2025.90142.1432>

URL: https://ijvst.um.ac.ir/article_46436.html