



## Anatomical and Radiographical Studies of the Skull in Adult European Badger (*Meles meles*)

a b c d  
Babak Rasouli, Mohammadali Adibi, Arad Jahankhani, Omid Zehtabvar

- <sup>a</sup> Department of Basic Sciences, Faculty of Veterinary Medicine, Semnan University, Semnan, Iran.  
<sup>b</sup> Department of environment of Semnan province, Semnan, Iran.  
<sup>c</sup> DVM student, Faculty of Veterinary Medicine, Semnan University, Semnan, Iran.  
<sup>d</sup> Department of Basic Sciences, Faculty of Veterinary Medicine, University of Tehran, Tehran, Iran.

### ABSTRACT

The European badger (*Meles meles*) is a powerful animal native to Europe and parts of West Asia. The skull imparts the phylogenetic morphology to the skulls of animal species and functions as a safeguard for vital organs, including the brain and eyes. The aim of our study was to improve the current data by providing a comprehensive investigation of the morphology and dimensions of the cranium and mandible of badgers. This information enhances comprehension of radiological and surgical attributes. We conducted anatomical studies and measured the morphometric features. We received the skulls from naturally occurring carcasses. We employed unpaired t-test for statistical analysis. This study demonstrated that the anatomical features of the skull exhibit no discernible differences between badgers and other wild carnivores, such as tiger and wolf. The presence of a twin jugular foramen in the skull of badgers distinguishes them as a distinct characteristic not found in any other carnivorous animals. Moreover, radiographical studies showed two distinct sinuses and a cavity in the skull of badger which is different from dogs. Males and females differ significantly in some morphometric traits, which is entirely consistent with the behavioral and nutritional traits of the animal. Modern imaging techniques, such as CT scans, are necessary for more thorough studies on the skulls of wild carnivores.

### Keywords

*European badger, Skull, Morphology, Morphometry, Radiography.*

Number of Figures: **10**  
Number of Tables: **2**  
Number of References: **21**  
Number of Pages: **9**

### Abbreviations

CT: *Computed Tomography*

**Introduction**

European badger is classified taxonomically as a member of the Mammalia class, Carnivora order, and Mustelidae family. Globally, this animal's habitat spans Europe, Asia, and Africa. Forests and steppe areas with soft soils are the best environments for badgers [1]. They are renowned for their distinctive black and white stripes and robust bodies, and they utilize their powerful front paws to excavate food and construct their unique burrows known as 'setts' [1]. The cranium determines the form and shape of the head, as well as creating a defensive bed for the enamel, brain, eyes, and ears [3]. The difference in shape between the skull and mandible simultaneously impacts the cross-sectional area of the masticatory muscle tissues and biting force [4]. To perform their treatment procedures in zoos and natural world, veterinarians and animal surgeons must have basic anatomical information about animals [21]. In addition, craniometry is the inspiration for medical and surgical practices. Furthermore, the exceptional openings in the skull have significant therapeutic relevance in the administration of local anesthetic in the head [5].

The Mustelidae family's skull anatomy has been the subject of numerous studies. In 2022, Martonos et al. conducted a comprehensive study on the middle ear ossicles in badgers. Zagrai et al. in 2019 compared skull morphology in badgers and otters. Taraska et al. in 2016 and Gálvez-López in 2022 conducted extensive studies on the corneal shape and craniometric parameters in mink species. In 2012, Suzuki et al. performed comprehensive research on the morphologi-

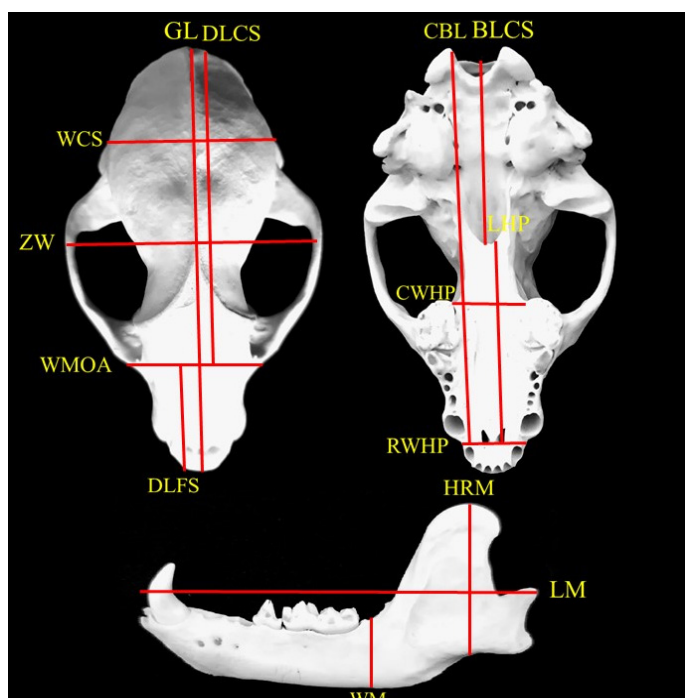
cal characteristics of the cranium and lower jaw in weasels. He et al. performed osteological studies on the skull and mandible of ferrets in 2002. Mustelidae skull scale increases from weasels to stoats, minks, polecats, pine martens, and otters. Overall, the skull anatomy of Mustelidae adapts to their carnivorous diet, featuring specialized teeth and a form that facilitates efficient hunting and consumption of prey. The width of the zygomatic arch and the height of the sagittal crest are important variables for distinguishing mustelid species [6].

The primary objective of this study was to examine and analyze the anatomical characteristics of the skull and mandible, with a particular emphasis on their morphometric, morphological, and radiological properties. Table 1 and Figure 1 provide the meanings of the abbreviations used for these measurements. We thoroughly compared these traits in adult badgers and other carnivores, as well as between genders. The main goal of this study was to explain the macroscopic anatomy and radiology of cranial bones. We enhance the exist-

ing knowledge based on this topic by conducting anatomical comparisons with other species. The results of this study also contribute to the expansion of data on veterinarians who treat unusual animals. The specified morphometric and morphological specifications improve comprehension of radiological and surgical attributes. These findings can aid in the identification of wild species found in various natural environments.

**Table 1.**  
Morphometric indices of skull of the badger

DLCS	Dorsal length of cranium of skull
GL	Greatest length of skull
WCS	Width of the cranium of skull
ZW	Zygomatic arch width
WMOA	Width between the medial eye angles (Canthus)
DLFS	Dorsal length of the facial part of skull
BLCS	Basal length of the cranial part of skull
CBL	Condylo-basal Length of skull
RWHP	Rostral width of hard palate
CWHP	Caudal Width of hard palate
LHP	Length of the hard palate
LM	Maximum Length of mandible
WM	Maximum Width of mandible
HRM	Maximum High of ramus of mandible



**Figure 1.**  
Illustration of morphometric measurements of skull of the Badger.

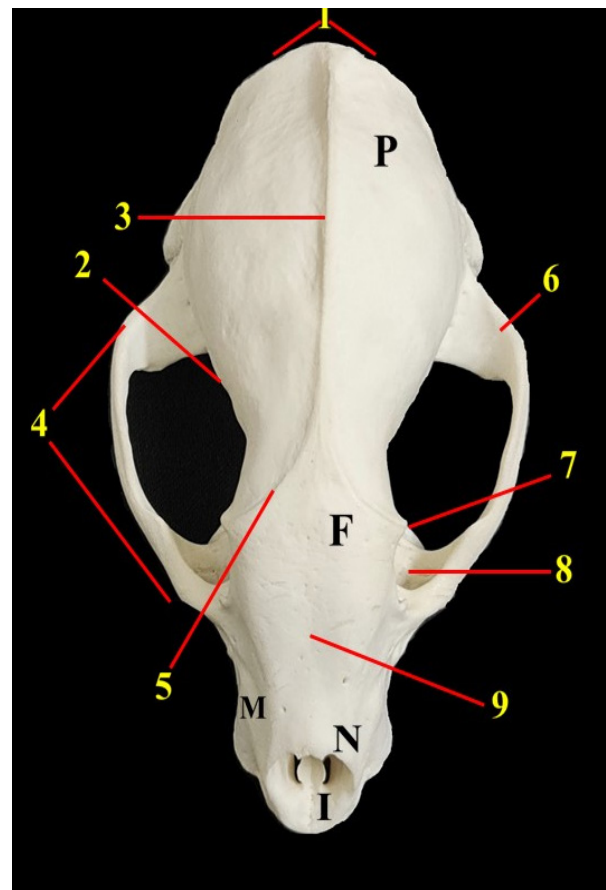
## Results

The frontal, nasal, and parietal bones were observed from a dorsal perspective. An important feature that stood out was a large external sagittal crest, clearly visible as a continuous, unbroken line. The prominent temporal lines emerged from the rostral of this crest and were connected to the zygomatic process of the frontal bones, forming the caudal border of the orbit. The parietal bones were observed as two asymmetrical triangles. These are the factors that led to the limited development of the frontal bones. The temporal fossa was a curved area that extends across the external sagittal crest. The supraorbital groove and supraorbital foramen were not observed (Figure 2).

The nuchal crest was highly noticeable at the posterior end of the external sagittal crest. The interparietal bone was integrated into this line and did not exist separately. The neuro-cranium exhibited significant elongation, measuring twice the length of the facial part of the skull. Consequently, the maxillary and nasal bones were limited and small (Figure 2). The ventrolateral view revealed the presence of several foramina in the pterygopalatine fossa located at the back of the orbit on the wing of the presphenoid bone. These foramina included the ethmoidal, optic, round, and rostral alar (Figure 3).

The zygomatic process of the temporal bone was strongly connected to the zygomatic bone's temporal process, causing the zygomatic arch to seem curved when viewed from the lateral view. Despite having a relatively large diameter, the external acoustic meatus had a low wall height. The articular tubercle and retro-articular process were noticed, but the retro-articular foramen was not readily visible. Furthermore, the mastoid process exhibited significant development in the posterior region of the external acoustic meatus. This view allowed the observation of a sharp Hamulus process. The frontal process of the zygomatic bone and the zygomatic process of the frontal bone were situated at a considerable distance from each other near the posterior border of the orbit. The infra-orbital foramen, clearly visible and of significant size, was situated over the alveolus of the third and fourth premolar teeth (Figure 4).

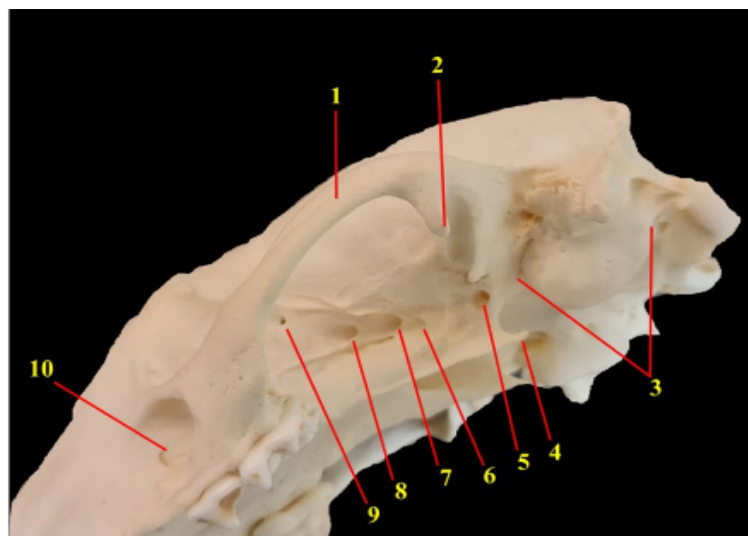
The ventral surface of the basi-occipital and basi-sphenoid bones had a short muscle tubercle. However, the border between the two bones was clear. The jugular foramen was observed in double form laterally to the basi-occipital bone. The boundary between the extensive tympanic bulla and



**Figure 2.**

Dorsal view of skull of the badger.

P) Parietal bone, F) Frontal bone, N) Nasal bone, M) Maxillary bone, I) Incisive bone, 1) Nuchal crest, 2) Temporal fossa, 3) External sagittal crest, 4) Zygomatic arch, 5) Temporal line, 6) Zygomatic process of frontal bone, 7) Zygomatic process of frontal bone, 8) Orbit, 9) Inter-frontal suture.

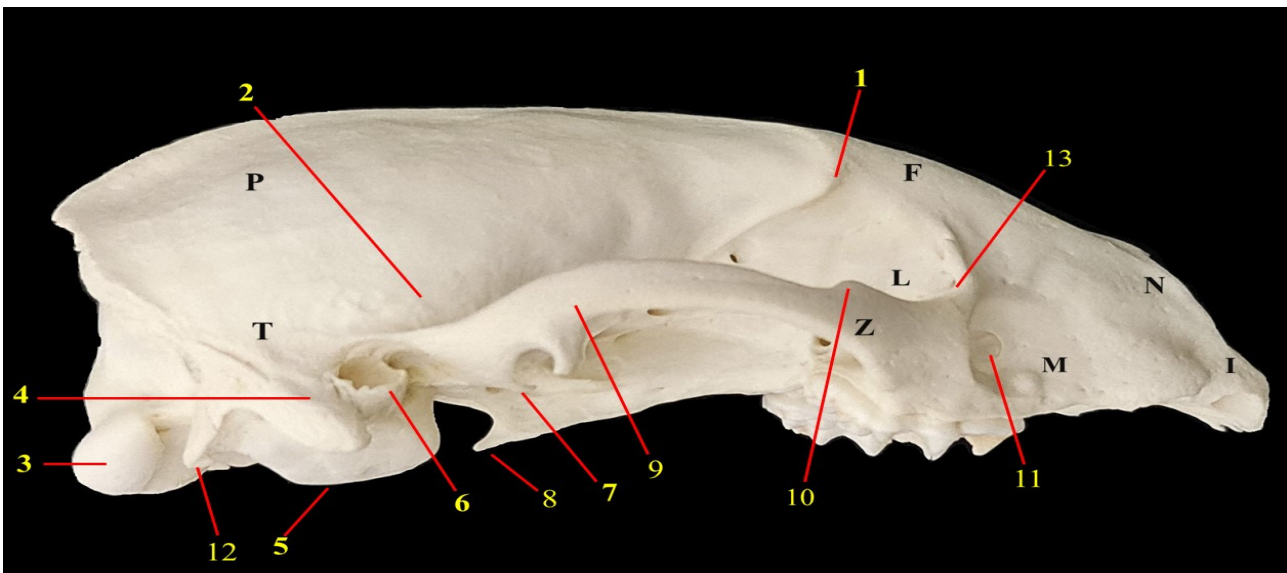


**Figure 3.**

Ventrolateral view of skull of the badger.

1) Zygomatic bone, 2) Condylod process, 3) Tympanic bulla, 4) Hamulus pterygoideus, 5) Caudal alar foramen, 6) Rostral alar foramen, 7) Orbital foramen, 8) Optic foramen, 9) Ethmoidal foramen, 10) Infraorbital foramen.





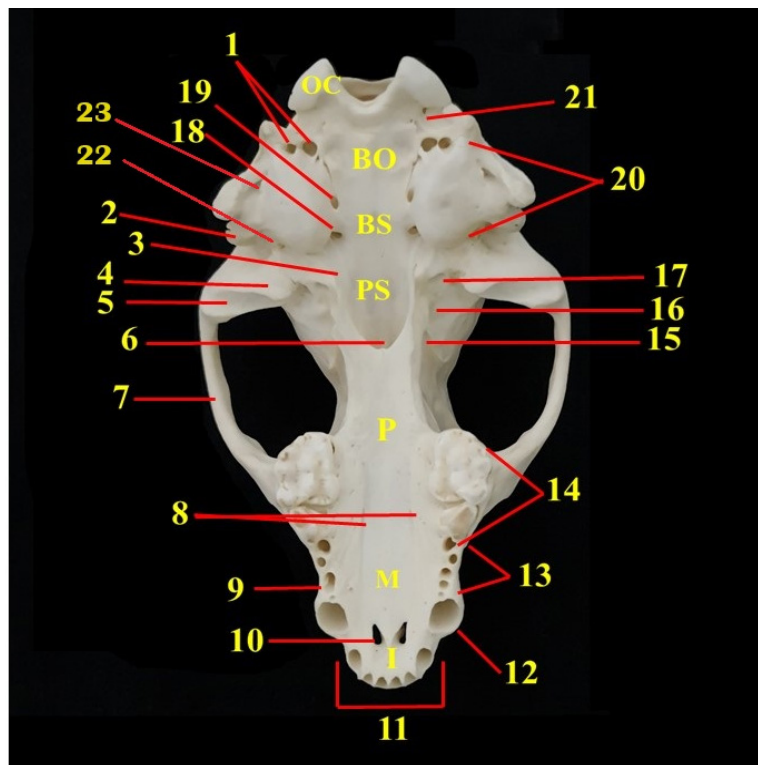
**Figure 4.**

Lateral view of skull of the badger.

T) Temporal bone, P) Parietal bone, F) Frontal bone, N) Nasal bone, M) Maxillary bone, L) Lacrimal bone I) Incisive bone, Z) Zygomatic bone, 1) Zygomatic process of frontal bone, 2) Temporal fossa, 3) Occipital condyle 4) Mastoid process 5) Tympanic bulla 6) External acoustic meatus, 7) Retro-articular process, 8) Hamulus pterygoideus, 9) Zygomatic process of temporal bone, 10) Frontal process of zygomatic bone, 11) Infra-orbital foramen, 12) Jugular process, 13) Lacrimal foramen.

the basi-sphenoid of the carotid foramen was distinct and clear. Despite being covered by tympanic bulla, the spinous and oval foramina were observable. Furthermore, the muscular process was observed to be very small and needle-shaped. The major palatine foramina were small and located medial to the fourth premolars in the hard palate area. These two were located along the two palatine grooves. Therefore, the horizontal part of the palatine bone was roughly large and constituted the largest portion of the hard palate. The incisive bones constituted a minor portion of the hard palate, and the prominence of palatine fissures was obvious (Figure 5).

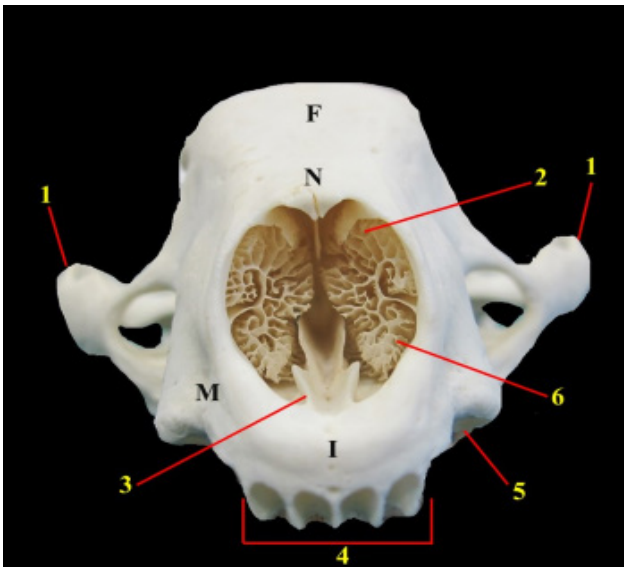
The rostral view revealed a long, robust, single bone that extended into the nasal cavity at the front and connected with the premaxilla, presphenoid, and maxilla bones. Furthermore, a deep groove was visible between its edges. The concha bones in the nasal cavity were attached to its lateral walls as delicate, scroll-like, complex bony plates (Figure 6). The nuchal surface was somewhat triangular. The shape of the foramen magnum was rounded, and its diameter was recorded to be 1.5 cm. The nuchal crest at the dorsal part of the squamous occipital bone was bow-shaped and very promi-



**Figure 5.**

Ventral view of skull of the badger.

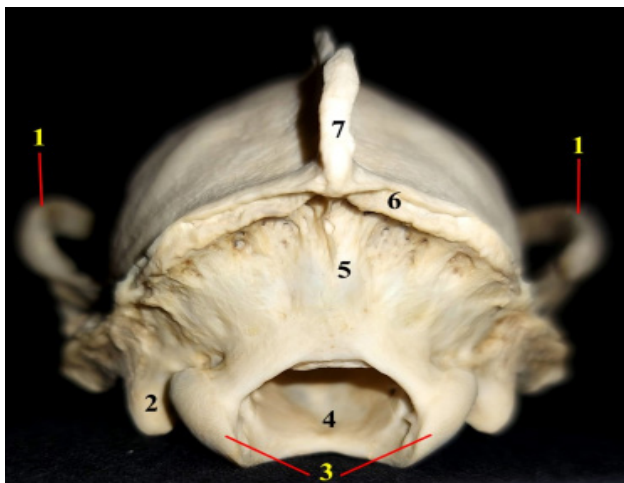
Oc) Occipital condyle, Bo) Basi-occipital, Bs) Basi-sphenoid bone, Ps) Pre-sphenoid bone, P) Parietal bone, M) Maxillary bone, I) Incisive bone, 1) Jugular foramen, 2) Muscular process, 3) hamulus pterygoideus, 4) Retro-articular process, 5) Mandibular fossa, 6) Choana, 7) Zygomatic arch, 8) Minor palatine foramen, 9) Major palatine foramen, 10) P1 tooth 11) Palatine fissure, 12) Incisor teeth, 13) Canine tooth, 14) Premolar teeth, 15) Molar teeth, 16) Rostral alar foramen, 17) Caudal alar foramen, 18) Oval foramen, 19) Carotid foramen, 20) Tympanic bulla, 21) Hypoglossal canal, 22) Retroarticular foramen, 23) Stiolomastoid foramen.



**Figure 6.**

Rostral view of skull of the Badger.

M)Maxillary bone F) Frontal bone. I) Incisive bone, N) Nasal bone, 1) Zygomatic arch, 2) Dorsal concha. 3)Vomer bone, 4) Incisor teeth alveoli, 5) Canine tooth alveolus, 6) Ventral concha.



**Figure 7.**

Caudal view of the skull of the badger.

1) Zygomatic process of temporal bone, 2) Jugular process, 3) Occipital condyles, 4) Magnum foramen, 5) Squamous part of occipital bone, 6) Nuchal crest, 7) External sagittal crest.

ment, and the rounded mastoid process was very well developed and fused with the ventral end of the crest on each side. The jugular processes of the badger were small and pointed (Figure 7).

The mandibular body exhibited a robust and trap-pezoidal shape, with a medial flattening that formed the mandibular symphysis. Furthermore, the ventral border appeared nearly linear. There were three mental foramina located on the side surface of the front half of the mandibular body, positioned behind the sockets of the premolar teeth. The rostral, middle, and caudal mental foramina were referred to, and the middle foramen was larger in all cases. The mandible's ramus has a triangular shape and consists of three distinct

processes. The coronoid process had a prominent and broad structure, constituting the upper half of the ramus. The angular process was small and positioned near the tail end. The condylar process, which is fashioned like a rod, was formed horizontally and connects with the mandibular fossa. A masseteric fossa was present on the lateral aspect of the coronoid process. The object had a triangle shape and provided a point of attachment for the masseteric muscle. The muscle's range of motion was restricted by the coronoid crest at the front and the condyloid crest at the back. The inner surface of the coronoid process had a minor degree of roughness, specifically designed to accommodate the insertion of the temporal muscle, located directly above the mandibular foramen (Figure 9).

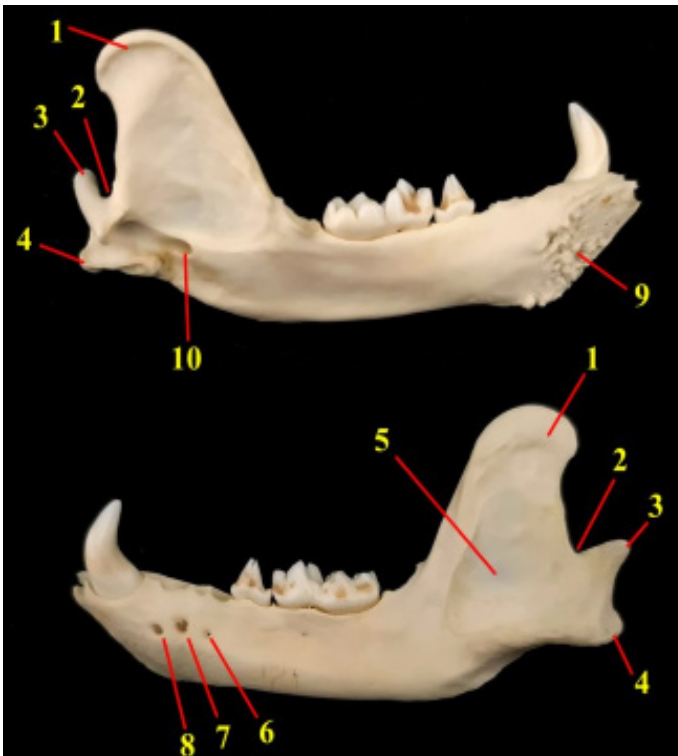
## Discussion

From a general standpoint, the badger's skull is more elongated than that of other carnivores, and the rostral area is not very wide. Dolichocephalic dogs also exhibit this feature, setting them apart from mongooses and lynxes that have a wide muzzle. The wideness of rostrum enhances the biting strength of the jaws [7]. Badger is a nocturnal and shy animal, and typically uses smaller animals and plants. On the other hand, the eyesight of this animal is weak, which limits its hunting abilities. As a result, the narrowness of this area is consistent with the animal's behavioral and nutritional characteristics.

The badger, similar to other wild carnivores, such as the tiger, wolf, cheetah, and lynx, does not possess the interparietal bone. Domestic cats and dogs also possess this bone (8, 9). With the exception of the marten and Egyptian mongoose, most carnivores have a noticeable external sagittal crest and pronounced temporal lines that extend to the posterior border of the orbit. These observations are also noted in the present investigation [10]. We did not observe the inter-incisive canal in our findings. However, this canal is present in brown bears, ferrets, and dogs. [11].

This study found that the orbital ligament completes the orbit, which is not entirely bony. All carnivores, except mongoose, have the same characteristic [5]. Four foramina, called ethmoidal, optic, orbital, and rostral alar, were situated on the posterior border of the orbit. These openings can also be seen in other carnivorous animals. However, the alar foramen is not present in lynx and cheetah [7]. The badger lacked the facial part of the lacrimal bone, but its orbital part was larger than that of a dog or domestic cat. The mastoid process of badger was very well-developed and distinct, similar to that of other carnivores. However,

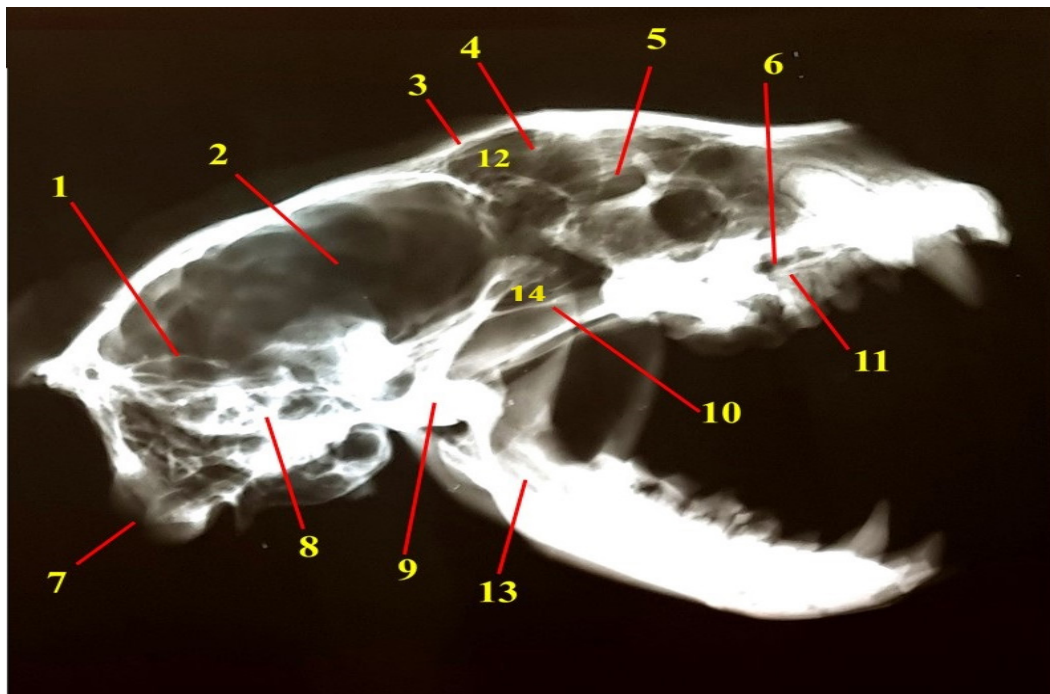
This



**Figure 8.**  
Lateral and Medial view of mandible of the badger.  
1) Coronoid process, 2) Mandibular notch, 3) Condylar process, 4) Angular process, 5) Masseteric fossa, 6) Caudal mental foramen, 7) Middle mental foramen, 8) Rostral mental foramen, 9) Mandibular symphysis, 10) Mandibular canal

it seems that in badgers, it is relatively larger than in other species [10]. Research indicated that the infra-orbital foramen, which is both large and round in shape, is positioned above the alveolus of the fourth premolar tooth. Therefore, these data are highly helpful for tracking the infra-orbital nerve and are crucial for the process of desensitizing the skin on the upper lip, nostril, and cheek [12].

The badger's tympanic bulla was relatively large, similar to previous reports in lions, cats, dogs, and tigers. Although it was small in brown bears. A short jugular process is seen in all the carnivores. In the badger, this process was distinct and well-developed [11, 13, 14]. The important point was the presence of a double jugular foramen in the skull of the badger. This state has been reported only in human, macaca, and rats, and these two openings are called anterior and posterior jugular foramens. It seems that due to the location of these two openings in the badger, they are called medial and lateral jugular foramens, which are separated by an inter-jugular septum [15]. Furthermore, the retro-articular and stilo-mastoid foramina were indistinguishable on the ventral surface of the mongoose skull.



**Figure 9.**  
Lateral radiograph of skull of the badger.  
1) Tentorium cerebrale osseum, 2) Facies cerebralis, 3) Frontal bone, 4) Cribriform plate, 5) Orbit, 6) Recessus maxillaris, 7) Occipital condyle, 8) Petrous part of temporal bone, 9) Temporomandibular joint, 10) Zygomatic arch, 11) Hard plate, 12) Frontal sinus, 13) Mandibular canal, 14) Sphenoid sinus.



Both of these foramina are present in the skulls of canines and ursids, but were not detected in the mongoose skull [5]. The ventral view did not reveal the border between the palatine bone and the maxilla. However, the presence of distinct major palatine foramina partially defines the large extent of the palatine. According to the previous studies, this feature seems to be consistent with mongooses, tiger, and lions, while different from canines and bears [14].

On the lateral surface of the mandible ramus, there were three mental foramina (rostral, middle, and caudal); the tiger, lynx, and dog showed a similar result. Nevertheless, the mongoose, leopard, and lion have two foramina, while the Persian cat and maned wolf only have one foramen. One can perform a mandibular nerve block in the mental zone by administering local anesthetic medications into the mandibular canal through three mental foramina. This will ensure the complete anesthesia of the lower incisors, premolar, and lower lip on the same side in cases of lower lip damage, dental

extraction, and tooth traumas [14, 16]. In males, the rostral and middle mandibular foramina are large and similar, whereas in females, only the middle opening is large. It seems that the large skull in males increases the need for nerve and blood supply.

An examination of golden jackal skulls revealed distinct morphological variations between females and males, which contrasts with the findings of the current study [17]. Although males and females have identical appearances, there are numerous notable distinctions in the measurement of morphometric variables between the two genders. The SL index, indicating the maximum width of the skull in relation to its length ( $ZW/GL \times 100\%$ ), was 55.3% and 58.4% in males and females, respectively (Table 2 and Figure 1). In ferrets, the average index is 61.5 for males and 58.8 for females. In mongoose, the index is 54.8 for males and 56.8 for females. The index in cheetahs is consistently 83.86, irrespective of gender [5, 18]. In the study of Japanese weasels, the CBL (Condylar-basal Length of the skull) index reached a maximum of 60 mm. We measured this index at 106 mm in male badgers [19]. According to Taraska et al., increasing the length of the skull in Mustelidae species reduces the level of wildness and hunting power, which is in agreement with the present study [20] (Figure 10).

The radiographical studies showed two distinct sinuses and a cavity in the skull of the badger. These ob-

**Table 2.**

Mean and standard deviation of morphometric characteristics of skull of the badger (\* significant difference  $p \leq 0.05$ ).

	Male (n= 5)	Female (n= 5)	P value
DLCS (mm)	88.29 ± 4.34	78.50 ± 2.65	0.032*
GL (mm)	112.23 ± 5.56	101.20 ± 6.21	0.041*
WCS (mm)	43.63 ± 2.96	37.75 ± 3.30	0.072
ZW (mm)	62.33 ± 4.35	59.80 ± 3.97	0.086
WMOA (mm)	27.24 ± 2.66	23.42 ± 2.54	0.067
DLFS (mm)	23.85 ± 1.71	19.04 ± 2.23	0.042*
BLCS (mm)	48.06 ± 5.25	43.70 ± 3.88	0.039*
CBL (mm)	106.64 ± 6.74	87.84 ± 5.05	0.011*
RWHP (mm)	17.05 ± 2.88	14.21 ± 3.60	0.025*
CWHP (mm)	25.17 ± 3.62	20.93 ± 3.75	0.176
LHP (mm)	56.10 ± 4.02	45.95 ± 6.12	0.040*
LM (mm)	90.95 ± 6.03	75.96 ± 4.54	0.012*
WM (mm)	16.09 ± 3.40	12.50 ± 3.09	0.102
HRM (mm)	41.14 ± 4.54	34.55 ± 4.24	0.086

servations are apparent in mongooses, cats, and foxes, as they possess sphenoid and frontal sinuses. The recessus maxillaris does not qualify as a real sinus due to its formation between distinct bones rather than between the two plates of the maxilla [21].

This study examined the anatomical characteristics and measurements of the skulls of male and female badgers. These characteristics are consistent with the behavioral and nutritional characteristics of the animal, and they are more similar to those of wild carnivores. Furthermore, except in minor cases, such as the size of the mandible foramina, there was no clear difference between the skull anatomy in the two genders. In the current study, we conducted a thorough anatomical examination of the badger's skull. However, to obtain additional information, the use of advanced diagnostic imaging techniques, such as CT scans, is necessary.

## Materials & Methods

This research focused on the skulls of ten adult European badgers, which included samples from both freshly obtained and museum collections. There were five male and five female badgers. The new samples were retrieved from naturally dying animals found in the wild. The Environment Organization sent us these cases over a three-year period from various regions of Semnan, Iran, and we then brought them to our center (Department of Anatomy, School of Veterinary Medicine). In the animal museum, we also used the complete skeletons of the Indian Gray Badgers. We selected them based on their

apparent good health and lack of bone-related ailments. Badgers typically display their complete set of teeth once they reach the age of ten months or older. To confirm their complete growth, we examined the teeth and dental formula of specimens (I3/3, C1/1, P4/4, M1/2=38) (Yam tav).

We cut the heads at a specific joint and then treated them in the laboratory to prepare their skeletons. A previous study (Zagrai) reported that this process involved boiling. We removed the bones from the soft parts of the body, removed the fat, whitened, and dried them. We conducted morphometric examinations and used a digital measuring tool (INSIZE, USA, Model: 1502S-1205) to obtain significant measurements of the anatomical characteristics. To describe, identify, and obtain approval, we adhered to the guidelines set by Nomina Anatomica Veterinaria. We recorded the results using a Canon Legria HF R16E digital camera from Canon Inc., Japan. An X-ray machine, called TUR 800 D-1, was used to perform the radiological study (Röntgenbelichtungsautomat-20029). Radiographs were obtained in dorsal-ventral and left lateral projections with a focus film distance of 120 cm, a kilovolt peak of 65 kV, and milliamperes-seconds of 10 mAs.

We used descriptive statistics to describe the measurements. Moreover, we utilized the unpaired t-test to study the differences between the male and female skulls in terms of their measurements and proportions. The differences were significant if P-value < 0.05.

### Authors' Contributions

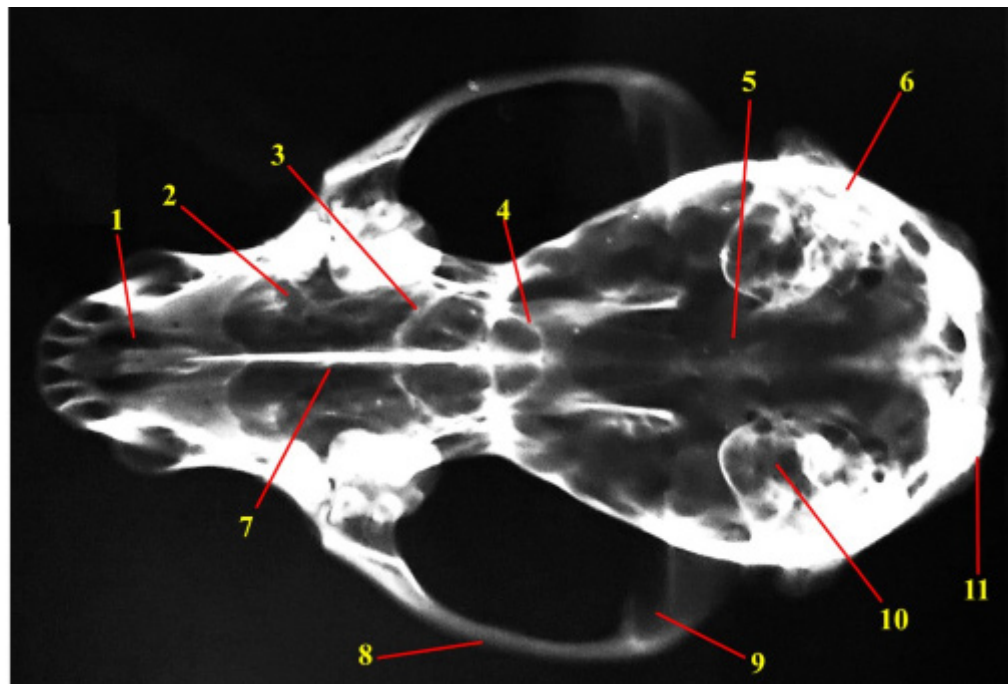
A. and B. conceived and planned the experiments. A. and C. carried out the experiments. C. contributed to sample preparation. A.C. and D. writing the manuscript. All authors provided critical feedback and helped shape the research, analysis and manuscript.

### Acknowledgements

The authors would like to thank Semnan University for financial support.

### Conflict of interest

The authors declare that there is no conflict of interest.



**Figure 10.**

Dorso-ventral radiograph of skull of badger.

1) Palatine fissure, 2) Maxillary recess, 3) Cribriform plate, 4) Naso-frontal suture, 5) Facies cerebri, 6) Petrous part of temporal bone, 7) Inter-palatal suture, 8) Zygomatic arch, 9) Mandibular fossa, 10) Tympanic bulla, 11) Occipital condyle.

### References

- Martonos C, Gudea A, Lațiu C, Blagojevic M, Stan F. Morphological and morphometrical aspects of the auditory ossicles in the European badger (*Meles Meles*). *Veterinary Sciences*. 2022;9(9):483. Doi: 10.3390/vetsci9090483
- Yoshimura K, Shindo J, Kageyama I. Light and scanning electron microscopic study on the tongue and lingual papillae of the Japanese badgers, *Meles meles anakuma*. *Okajimas folia anatomica Japonica*. 2009;85(4):119-27. Doi: 10.2535/ofaj.85.119
- Singh B. Dyce, Sack, and Wensing's textbook of veterinary anatomy: Saunders St. Louis, Missouri; 2018. 4th edn:177-96.
- GÜRBÜZ İ, AYTEK AI, DEMIRASLAN Y, VEDAT O, ÖZGEL Ö. Geometric morphometric analysis of cranium of wolf (*Canis lupus*) and German shepherd dog (*Canis lupus familiaris*). *Kafkas Üniversitesi Veteriner Fakültesi Dergisi*. 2020;26(4). Doi: 10.9775/kvfd.2019.23841
- Rasouli B, Yousefi MH. Skull, mandible and hyoid apparatus in the Indian grey mongoose (*Herpestes edwardsii*): A comprehensive anatomical study. *Anatomia, Histologia, Embryologia*. 2023. Doi: 10.1111/ahe.12895
- Lee S, Mill P. Cranial variation in British mustelids. *Journal of Morphology*. 2004;260(1):57-64. Doi: 10.1002/jmor.10212
- Georgescu B, Predoi G, Belu C, Purdoi L, Ghimpețeanu M, Chereji M, et al. Morphometric biodiversity of the skull in jaguar (*Panthera onca*). Case study. 2014.



8. König H, Liebich H. Veterinary anatomy of domestic mammals: textbook and colour atlas. 2014. 3th edn:120-196.
9. Mihaylov R, Dimitrov R, Krastev S, STAMATOVAYOVCHVA K. Morphology and anomaly of the skull of zoo Lynx lynx (Carnivora: Felidae): ecological aspects for further reintroduction. Bulgarian Journal of Agricultural Science. 2018; 24(1): 270 -4.
10. Pandey Y, Vaish R, Pandey A, PODHADE D. Gross morphometrical studies on cranial bones in tiger. Bioscan. 2017;12:811-4. Doi: 10.1111/ahc.12269.
11. Yousefi MH. Anatomical study of the Iranian brown bear's skull (Ursus arctos): A case report. Iranian Journal of Veterinary Medicine. 2016;10(3):237-44. Doi: 10.22059/IJVM.2016.58686.
12. Monfared AL. Anatomy of the Persian cat's skull and its clinical value during regional anesthesia. Global Veterinaria. 2013;10(5):551-5. Doi: 10.5829/idosi.gv.2013.10.5.72101.
13. Atalar Ö, Üstündag Y, Yaman M, Özdemir D. Comparative anatomy of the neurocranium in some wild carnivora. Journal of Animal and Veterinary Advances. 2009;8(8):1542-4.
14. Mohamed R. Anatomical and radiographic study on the skull and mandible of the African lion (Panthera leo). Journal of Morphological Sciences. 2019;36(3):174-81. Doi: 10.3390/vetsci5020044.
15. Wysocki J. Morphology of the temporal canal and postglenoid foramen with reference to the size of the jugular foramen in man and selected species of animals. Folia Morphologica. 2002;61(4):199-208.
16. de Souza P, de Moraes FM, de Carvalho NdC, Canelo EA, Thiesen R, Santos ALQ. Mandibular morphometry applied to anesthetic blockage in the maned wolf (Chrysocyon brachyurus). Journal of Zoo and Wildlife Medicine. 2016;47(1):91-7. Doi: 10.1638/2015-0092.1.
17. Rezić A, Bošković I, Lubinu P, Piria M, Florijančić T, Scandura M, et al. Dimorphism in the skull form of golden jackals (Canis aureus Linnaeus, 1758) in the Western Balkans: a geometric morphometric approach. Pakistan Journal of Zoology. 2017;49(3).Doi:10.17582/journal.pjz/2017.49.3.989.997
18. He T, Friede H, Kiliaridis S. Macroscopic and roentgenographic anatomy of the skull of the ferret (Mustela putorius furo). Lab Anim. 2002;36(1):86-96. Doi: 10.1258/0023677021911795
19. Suzuki S, Abe M, Motokawa M. Integrative study on static skull variation in the Japanese weasel (Carnivora: Mustelidae). Journal of Zoology. 2012;288(1):57-65. Doi: 10.1111/j.1469-7998.2012.00924.x
20. Taraska M, Sulik M, Lasota B. Comparison of the craniometric parameters of wild and farm American mink (Mustela vison). Folia Morphol (Warsz). 2016;75(1):251-6. Doi: 10.5603/FM.a2015.0092.
21. Mahdy MA, Zayed M. Computed tomography and cross-sectional anatomy of the head in the red fox (Vulpes vulpes). Anatomia, Histologia, Embryologia. 2020;49(6):708-17.

**COPYRIGHTS**

©2025 The author(s). This is an open access article distributed under the terms of the Creative Commons Attribution (CC BY 4.0), which permits unrestricted use, distribution, and reproduction in any medium, as long as the original authors and source are cited. No permission is required from the authors or the publishers.

**How to cite this article**

Rasouli B, Adibi MA, Jahankhani A, Zehtabvar O. Anatomical and Radiographical Studies of the Skull in Adult European Badger (*Meles meles*). Iran J Vet Sci Technol.2025; 17(1): 75-83.

DOI: [https://doi.org/ 10.22067/ijvst.2025.88540.1390](https://doi.org/10.22067/ijvst.2025.88540.1390)

URL: [https://ijvst.um.ac.ir/article\\_46292.html](https://ijvst.um.ac.ir/article_46292.html)