



Evaluation of supracondylar femur fractures in cats: a retrospective study

Sadık Yayla, Semih Altan, Emine Çatalkaya, Berna Ersöz-Kanay, Nahit Saylak

Department of Surgery, Faculty of Veterinary Medicine, University of Dicle, Diyarbakir-Turkey, 21280.

ABSTRACT

Femoral fractures in cats are common and are usually treated using pins and wires, lag screws, intramedullary pins, as well as interlocking pins and plates. Among femur fractures, supracondylar femur fractures have an important place, and both proximal and distal femur fractures are more difficult than diaphyseal fractures. This study, which was conducted on 55 cats with the distal femur and supracondylar fractures, aimed to retrospectively evaluate the results of three different methods used traditionally. These methods were Rush pinning, cross pinning, and locked anatomic plates. Despite the disadvantages of each of the techniques, no problem was found in the application of either of them. No complications, including pin migration or plate and screw related complications, were encountered in the postoperative period. Functional improvement was achieved in all cats. As a result, it can be said that the method to be used in supracondylar fractures in cats varies according to the surgeon's preference and the orthopedic materials in his or her inventory. However, the anatomical locking plates may be preferred due to their advantages, such as not using bandages and starting to use the limb in the early postoperative period.

Keywords

Cats, Cross pinning, Locked L plates, Rush pinning, Supracondylar femur fractures

Number of Figures: 4
Number of Tables: 1
Number of References: 18
Number of Pages: 5

Abbreviations

IV: intravenous
IM: intramuscular

Introduction

Femoral fractures in cats are common due to traumatic causes, such as falling from height and traffic accidents and constitute 20%-26% of total fractures [1-3]. According to the Salter-Harris classification, distal femur fractures are classified as metaphyseal, physeal, or epiphyseal in cats that are not yet fully grown, whereas distal metaphyseal fractures are defined as supracondylar fractures in adult cats [1, 3, 4]. Supracondylar fracture is one of the most common types in dogs and cats. Important factors affecting the treatment of distal femur fractures can be listed as correct surgical approach, minimal dissection, preservation of soft tissue and fracture line, anatomic reduction, adequate stabilization, appropriate material selection, and effective postoperative care [1, 4-7].

In any treatment method chosen, the desired goal is functional recovery by providing rapid bone healing. Distal femoral fractures in cats are successfully treated with pin application techniques (e.g., pin and wires, Rush pins, intramedullary threaded pins, interlocking pins, and cross pin) and plate osteosynthesis techniques [1, 8-12]. The aim of this study was to retrospectively compare different pin applications, such as Rush pin and cross-pin, and locked L plate osteosynthesis in supracondylar femoral fractures, which are common in cats.

Results

In the cases investigated in the current study, fracture occurred due to falling from height in 26 cases, traffic accident in 19 cases, crash in 3 cases, and unknown reason in 7 cases. Cats with other fractures, diaphragmatic hernia, or head trauma were not included in the study. In terms of the technique used, the cases were randomly distributed, and 20 cats were treated with the first method (rush pin, Figure 1), 17 cats with the second method (cross rush pin, Figure 2), and 18 cats with the third method (locking L plate, Figures 3 and 4).

It was determined that none of the cases had adverse problems during the operation and the treatment was completed without any problems. Cats who underwent plate osteosynthesis started walking within 3 days, while the functional recovery was achieved in all cats within 3 weeks postoperatively. There was atrophy, albeit very little, since the movement was limited in the bandaged cats. However, this situation resolved spontaneously when the cat started to use the relevant extremity. No serious complications, such as pin migration or plate- and screw-related complications were encountered in the postoperative period.

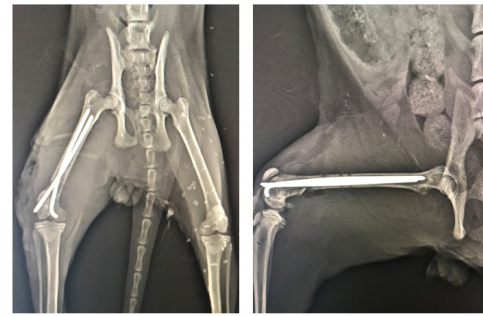


Figure 1.
An example of Rush pin implementation

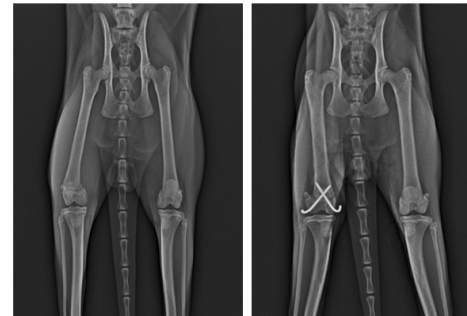

Figure 2.
An example of a cross pin application

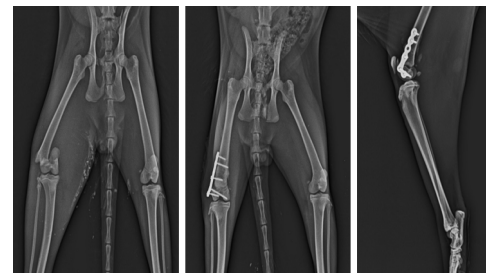


Figure 3.
A case with a locked anatomic L plate

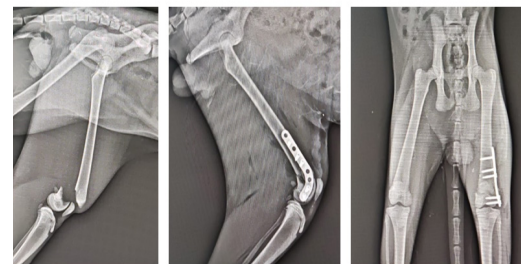


Figure 4.
A case with a locked anatomical cane plate

Discussion

Femoral fractures are common problems in cats and dogs, with supracondylar femur fractures having special clinical importance. The etiology is mostly a trauma, such as a traffic accident or falling from a height. Since cats have a lower body weight than dogs, post-operative care conditions are relatively easier.

However, the treatment options planned for supracondylar femur fractures in cats are very similar to those in dogs. Among these, cross rush pin application, cross pin technique, and anatomical plate osteosynthesis technique are widely used [1, 5, 9]. The present study aimed to retrospectively evaluate different treatment options, namely Rush pin application, cross-pin application, and locked L plate osteosynthesis for supracondylar femur fractures in cats.

Although some methods, such as intramedullary pinning or interlocking nailing techniques are widely used in femur fractures, it is known that intramedullary nails are insufficient for fixation compared to the femoral body for distal femur fractures, especially supracondylar fractures [1, 5, 9, 13-18]. Therefore, in contrast to retrograde pinning in supracondylar fractures, cross Rush pin application is preferred to the femoral medullary canal from the distal of the condyle, which is exposed by cutting the joint capsule. In addition, the fixation technique has become widespread in recent years by sending a Kirschner wire crosswise from the lateral and medial condyles to the femoral medulla. It is necessary to open the joint capsule both for rush nails and for the use of the cross pinning technique. In addition, in these two methods, it is difficult to maintain the immobility of the extremity, especially in hyperactive cats, to provide adequate immobilization in the postoperative period [1, 5]. We think that the bandage applied to prevent pin migration may cause some complications. Sometimes atrophy may develop in the extremity muscles after bandage usage. Despite these described disadvantages, Rush pin and cross pin techniques also have some advantages, including being easy to apply and being economical. The approaches to the condyles are very similar in Rush pin and cross pin. In the intraoperative process, there is almost no joint damage. However, extremity movements should be limited against pin migration in the postoperative period.

Recently, the number and variety of plaques used in veterinary orthopedics have increased with technological developments. With the widespread use of locking plates, the usage of shaped anatomical plates, such as T plate, L plate, and C plate became easier. Among these, the use of a locked L plate is extremely easy, especially for supracondylar femur fractures [4, 5, 9-11]. In addition, the use of locking plates, which allow animals to walk immediately after the operation, eliminates the need for bandages in the postoperative period. This is important to avoid bandage-related complications [9-11]. In our study, no complications related to the plate or screw were observed in the cats to which the plate was applied. Since bandages were not applied to these cats, they started to use the relevant extremity immediately after the surgery.

According to the data obtained from this study, it can be said that the Rush pin technique, cross pin technique, and locking plate are sufficient for fracture stabilization in supracondylar femur fractures in cats. Each technique has advantages as well as disadvantages. We observed in our study that bandage restricts the comfort of cats in the postoperative period rather than the success of the preferred method. As a result, the method to be used in supracondylar fractures in cats might vary based on the type of fracture, the surgeon's preference, and the available orthopedic materials in the inventory. However, the use of an anatomical locking plate may be preferred due to its advantages, including not using postoperative bandages and starting to use the limbs in the early postoperative period. Although these plates may provide more stability, they are more expensive than other methods, and the left-side and right-side plates should be available. In addition, caution should be exercised in the use of plaques in young cats before growth plates close.

Materials and Methods

In this study, 55 cats with supracondylar or distal femur fractures were selected out of the patients who presented to the Department of Surgery, Faculty of Veterinary Medicine, Dicle University, during 2019-2022 with the complaint of hind limb lameness. Cats (n = 55) included in the study were of different breeds (26 mixed breeds, 9 tabby breed cats, 5 Persian cats, 7 Van cats, 3 Ankara cats, 3 British, and 2 Siamese), different genders (32 female and 23 male), with the mean \pm standard deviation age of 14.78 ± 5.80 months and mean \pm standard deviation body weight of 3.18 ± 0.93 kg. Surgery was planned after the fracture was confirmed based on the physical and radiological examinations.

All operations were performed under general anesthesia. Each animal was administered 1 mg/kg IV xylazine for premedication and 15 mg/kg IV ketamine for anesthesia. Moreover, for multimodal analgesia during operation, a combination of 12 mg ketamine + 4.8 mg butorphanol + 40 μ g medetomidine in 100 ml saline was given IV as 5ml/kg/h. After each animal in the study was placed in the lateral recumbency, routine preparations for the operation were made and the area was limited with sterile covers. A lateral parapatellar skin incision was made to the fracture line for an appropriate surgical approach. Subcutaneous tissues were dissected and the capsular incision was made. The fracture line was exposed by pulling the patella and patellar ligament medially. Next, the stifle joint was reached and the condyles were exposed. After this stage, three different methods were followed.

In the first method (n = 20), Rush pins sent over the side face of the medial and lateral condyles were placed in the proximal femur medulla (Figure 1). In the second method (n = 17), two pins, which were sent in a similar way to the Rush pin technique, were diagonally based on the proximal femoral cortex (Figure 2). In the third method (n=18), a locking L plate was placed craniolaterally to the femur (Figures 3 and 4). The area was routinely closed after the patella was brought to its normal position.

All animals using the first and second methods were protected with a bandage for 10 days postoperatively. A postoperative bandage was not applied in cats with plaque. Amoxicillin clavulanic acid at a dose of 12.5 mg/kg IM was injected for 5 days. In addition, 0.2 mg/kg IM meloxicam was used for 3 days. All cases were followed up clinically and radiologically with 1-week intervals postoperatively until functional recovery and callus formation

Table 1.
Thermal environmental parameters of the experimental site in the hot-dry season

Method of treatment	Breed	Gender		Bandage use	Comparison
		Male	Female		
First method (Rush pinning) n=20	15 mixed	6	9	Bandage used	Bandage-related atrophy or poor circulation may be seen. Enough for good stabilization.
	2 tabby	2	0		
	2 Persian	1	1		
	1 Van	1	0		
Second method (Cross pinning) n=17	7 mixed	2	5	Bandage used	Bandage-related atrophy or poor circulation may be seen. It can be applied more easily than Rush pinning. Enough for good stabilization.
	4 tabby	3	1		
	3 Van	1	2		
	3 Ankara	1	2		
Third method (Locking L plate) n=18	4 mixed	2	2	No bandage	A more comfortable postoperative process. Enough for good stabilization. It is a great advantage to not have bandages and to start walking immediately the day after the operation. May be more expensive than other techniques and requires experience.
	3 tabby	1	2		
	3 Persian	0	3		
	3 Van	1	2		
	3 British	1	2		
	2 Siamese	1	1		

* Humerus, radius-ulna, tibia, and distal fractures were ignored in the animals included in the study. However, cats with vertebral and pelvic fractures requiring surgery were excluded from the study.

** All of the cases had a distal fracture of the femur and there was no second fracture of the same femur.

was completed. In animals with Rush pins and cross pins, these pins were removed by the decision of either the veterinarian or the owner of the patient due to concerns that they would disrupt bone growth and cause irritation.

Authors' Contributions

S.Y., S.A., E.Ç., B.E.K. and N.S. conceived and planned the experiments. All authors took part in the operations. S.Y. wrote the manuscript.

Acknowledgements

This study was not funded by any institution.

Conflicts of Interest

The authors declare that there is no conflict of interest.

References

- Altunatmaz K, Karabağlı M, Aydın Kaya D, Güzel O, Eravcı Yalın E, Uğurlu U, Şadlak DJ, Ekici H. The Treatment of Supracondylar and Diaphyseal Femoral Fractures in Cats Using Intramedullary Two-Way Stacked Kirschner Wire Application. *Turk J Vet Anim Sci.* 2017; 41: 282-7.
- Whitehair JG, Vasseur PB. Fractures of The Femur. *Vet Clin North Am Small Anim Pract.* 1992; 2: 149-159.
- Scotti S, Klein A, Pink J, Hidalgo A, Moissonnier P, Fayolle P. Retrograde Placement of A Novel 3,5 mm Titanium Interlocking Nail For Supracondylar and Diaphyseal Femoral Fractures in Cats. *Vet Comp Orthop Traumatol.* 2007; 20: 211-8.
- Beale B. Orthopedic Clinical Techniques Femur Fracture Repair. *Clin Tech Small Anim Pract.* 2004; 19: 134-150.
- Cebeci MT, Karli B. Treatment of Cats Distal Diaphyseal and Supracondylar Femur Fractures With Intramedullary Cross Pinning Technique. *Harran Üniv Vet Fak Derg.* 2021; 10 (2), 184-190,
- Chandler JC, Beale BS. Feline Orthopedics. *Clin Tech Small Anim Pract.* 2002; 17 (4): 190-203.
- Fossum TW, 2013: Small Animal Surgery. 4th ed. Elsevier. Philadelphia, USA. pp: 1181-1185.
- Gill KK, Kumar A, Sangwan V, Anand A, Mahajan SK, Mohindroo J: Comparative Functional Outcome of Supra-

- condylar Femoral Fracture Stabilized With Cross and End Threaded Intramedullary Pinning in Dogs. *Indian J Anim Sci.* 2018; 88 (2): 161-9.
9. Jagan MRK. Clinical Study on The Use of Supracondylar Femur Plate (J plate/ hockey stick plate) For Repair of Supracondylar Femur Fractures in Cats. *The Pharma Innovation Journal.* 2020; 9(12): 19-25.
 10. Lidbetter DA, Glyde MR. Supracondylar Femoral Fractures in Adult Animals. *Compend Contin Educ Pract Vet.* 2000; 22:1041-55.
 11. Lovric L, Kreszinger M, Pecin M. Surgical Treatment of Canine Femoral Fractures – A Review. *World Vet J.* 2020; 10 (2): 137-45.
 12. Robinson A. Use of A Rush Pin to Repair Fractures of The Distal Femur in Cats. *VetRecord.* 2000; 146: 429-32.
 13. Denny HR, Butterworth SJ. *A Guide to Canine and Feline Orthopaedic Surgery.* 4th ed. Oxford, UK: Blackwell Science, 2000.
 14. Smalle TM, Coetzee GL, Naude SH. Corrective Wedge Osteotomy for An Atypical Femoral Procurvatum Deformity Stabilised With A Supracondylar Bone Plate. *Journal of the South African Veterinary Association.* 2018; 1019-9128.
 15. Spangberg C, Spangberg IB, Bergstrom A. Stainless Steel Wire in A Figure-of-Eight for Repair of Distal Femoral Physeal Fractures in Ten Cats: A Case Report. *J Vet Sci.* 2019; 20 (6): 1-6.
 16. Sharma M, Sarma DK, Boro PK. Fixation of Distal End Femoral Fracture in Dogs With Arrow Pinning: A Case Report. *Int J Curr Microbiol App Sci.* 2018; 7: 2161-4.
 17. Syam KV, Venkateswaralu B, Sarada AT, Raji TA, Ranjith M. External Skeletal Fixation in Combination With Intra-Medullary Pinning MedDocs Publishers Journal of Veterinary Medicine and Animal Sciences 5 and Cerclage Wiring for The Measurement of Comminuted Fractures of Humorous in Dog. *Ind J Canine Prac.* 2012; 4: 54-5.
 18. Libardoni RN, Costa D, Menezes FB, Cavalli LG, Pedrotti LF, Kohlrausch PR, Minto BW, Silva MAM. Classification, fixation techniques, complications and outcomes of femur fractures in dogs and cats: 61 cases (2015-2016). *Ciencia Rural.* 2018; 48 (6): 1-6.

COPYRIGHTS

©2022 The author(s). This is an open access article distributed under the terms of the Creative Commons Attribution (CC BY 4.0), which permits unrestricted use, distribution, and reproduction in any medium, as long as the original authors and source are cited. No permission is required from the authors or the publishers.

**How to cite this article**

Yayla S, Altan S, Çatalkaya E, Kanay B, Saylak N. Evaluation of supracondylar femur fractures in cats: a retrospective study. *Iran J Vet Sci Technol.* 2022; 14(4): 37-41.

DOI: <https://doi.org/10.22067/ijvst.2022.77601.1167>

URL: https://ijvst.um.ac.ir/article_43281.html