

Effect of single-dose pimobendan on echocardiographic parameters in healthy New Zealand White rabbits

Authors:

Ariana Askari Ghalehi ^a, Ali Moradganjeh^b, Vria Tohidi^c, Ali Rostaei^d

^a Department of Veterinary Clinical Sciences, Karaj branch, Islamic Azad University, Karaj, Iran

^b Department of Pharmacology, Karaj branch, Islamic Azad University, Karaj, Iran

^c Department of Radiology, Karaj branch, Islamic Azad University, Karaj, Iran

^d Department of Surgery and Radiology, Faculty of veterinary medicine, University of Tehran, Tehran, Iran

Corresponding author: Dr. Ali Moradganjeh^b

Postal address: Pharmacology Department, Faculty Veterinary Medicine, Azad University, Karaj, Iran

University/organization email address: Moradganjeh@kiaau.ac.ir

ORCID ID: 0000-0001-9512-6105

Tel. number: 09122507213

Keywords

Echocardiography, pimobendan, rabbits, cardiac function

Abstract

keeping rabbits as pets and their use in laboratory research increased the need for research into heart disease and treatment in rabbits. Pimobendan is one of the most common drugs which is used in cardiac diseases. Its use in rabbits is anecdotal. The first step toward the approval of pimobendan in rabbits is the potential for beneficial effects on cardiac function. Echocardiographic functional parameters can detect it.

This study aimed to determine the pimobendan's effects on echocardiographic parameters.

Eleven rabbits were included in this study. Echocardiographic examinations were done before and after pimobendan administration for each rabbit.

Left ventricle morphological and functional parameters were compared between time points.

Pimobendan resulted in changes in several echocardiographic variables in rabbits; Specifically, fractional shortening, ejection fraction, stroke volume, left ventricular posterior wall end-systole, and left atrium end-systolic increased ($p=0.0001$, $p=0.0001$, $p=0.0284$, $p=0.0272$, and $p=0.0007$, respectively), whereas left ventricular internal diameter end-systole and end systolic volume decreased ($p=0.0343$ and $p=0.038$). It wasn't a meaningful change in some parameters like left ventricular internal diameter end-diastole, left ventricular posterior wall end-diastole, end diastolic volume, left atrium maximum dimension, Mitral annulus diameter, and left atrium to aorta ratio.

Considering that the factor fractional shortening indicates an increase in the power of heart contraction and consequently an improvement in heart function, and which has increased in this study after pimobendan administration, it can be concluded that pimobendan improves cardiac function. Further studies are required to investigate whether pimobendan has similar effects in rabbits with cardiac disease.

Introduction

Heart disease in rabbits can result in congestive heart failure (CHF), characterized by an excess of fluid volume that manifests in signs of left-sided failure, such as pulmonary edema and pleural effusion, as well as signs of right-sided failure, including abdominal effusion, hepatomegaly, and splenomegaly. The initial indications of heart disease include reduced activity, weight loss, alterations in eating patterns, and breathing difficulties.

Pimobendan, a benzimidazole pyridazinone medication, has demonstrated significant advantages in CHF, preclinical dilated cardiomyopathy, and preclinical degenerative valve disease in dogs [1][2]. Pimobendan is used to treat dogs with congestive heart failure (CHF) secondary to dilated cardiomyopathy (DCM). It has positive inotropic and vasodilatory

effects by phosphodiesterase 3 inhibition and calcium sensitization [1]. It has other effects such as increasing coronary blood flow, positive effects on myocardial oxygen consumption, and satisfactory effects on myocardial compliance [2].

Rabbits have been widely used as animal models to study various cardiac diseases, such as endocarditis and cardiomyopathies [3,4]. The most common types of cardiovascular disease in rabbits include myocarditis, arteriosclerosis, and cardiomyopathy. Electrocardiograms, [5,6] blood pressure measurements, and echocardiograms [7,8] can be used for diagnostic purposes in rabbits.

The extra-label use of pimobendan in rabbits with CHF has garnered a lot of attention in the past decade. The positive inotropic effect of the drug has been reported in rabbits without any negative impacts on morbidity and mortality [9].

In 2020, Ozawa et al. evaluated the pharmacokinetics of oral pimobendan administered to healthy New Zealand White rabbits. According to their findings,[10] the half-life of pimobendan was 3.54 ± 1.32 hours, the plasma concentrations were detected for up to 24 hours, and desmethyl pimobendan, which is the active metabolite of pimobendan, was detectable for 24 to 36 hours [10].

The present study was designed to address the knowledge gap by investigating the echocardiographic effects of pimobendan administered orally to healthy New Zealand White rabbits.

Abbreviations

LVIDs: Left ventricular internal diameter end-systole

LVIDd: Left ventricular internal diameter end-diastole

LVPWs: Left ventricular posterior wall end-systole

LVPWd: Left ventricular posterior wall end-diastole

IVSs: Interventricular septum end-diastole

IVSd: Interventricular septum end-systole

EDV: End-diastolic volume

ESV: End-systolic volume

EF: Ejection fraction

SV: Stroke volume

FS: Fractional shortening

LA max: Left atrium maximum dimension

LA min: Left atrium minimum dimension

MVA max: Mitral valve maximum area

MVA min: Mitral valve minimum area

LA/Ao: Left atrium to Aorta ratio

CHF: cardiac heart failure

DCM: Dilated cardiomyopathy

LV: Left ventricle

LA: Left atrium

Results

Pimobendan caused noticeable changes in some parameters compared with the pre-drug group; SV, EF, FS, LVPWs, and minimum size of left atrium increasing were noticeable (P-value < 0.05), whereas LVIDs and ESV were decreased (p=0.0343 and p=0.038, respectively).

There wasn't a meaningful change in some parameters like Left ventricular internal diameter end diastole (LVIDd), Left ventricular posterior wall thickness in diastole (LVPWd), End-diastolic volume (EDV), Maximum left atrial diameter (LA max), Mitral annulus diameter and LA/Ao (Figure 1,2).

Table 1 clarifies changes from the base time (before administration) up to 3 hours after oral administration of pimobendan.

Discussion

This study gained information about pimobendan's effects on the left ventricle function of healthy adult rabbits. Pimobendan's increased LV function was confirmed by the results of some echocardiographic LV variables.

There was no significant change in LVID during diastole, but LVID during systole decreased after 3 hours. Pimobendan had the same results in a study in dogs with asymptomatic mitral valve disease [11].

This result was similar to the result of a study that examined pimobendan effects on beagle dogs by Saengklub et al [12].

In a study conducted by Boswood et al. and another study conducted by Haggstrom et al in dogs with myxomatous mitral valve disease both LVIDd and LVIDs were decreased. In another study, which was done by Kinel et al. (2021) on dogs with Mitral valve disease,

pimobendan only reduced the size of the left ventricle during diastole [13–15].

Left ventricle posterior wall was slightly increased during systole. This finding was found in two studies by Yata et al. on healthy dogs and healthy cats [1,2].

Because the main cavity of the heart is the left ventricle and the blood in LV pumps in the aorta to deliver oxygenated blood to all body tissues, increasing LVPW can interfere with the heart's ability to pump blood in the aorta. However, the increase in LVPWs in this study was very mild and remains in the normal range of left ventricle posterior wall thickness in rabbits, so it doesn't have destructive effects on LV function.

The fractional shortening reflects the left ventricle systolic function. Our study shows increased left ventricular fractional shortening after pimobendan administration, which means an increase in LV function. Left ventricular fractional shortening has been used in veterinary medicine [16] and human [17] to assess LV systolic function. Prior studies have shown increased left ventricular fractional shortening in other animals. For example, a study evaluated cardiovascular effects after a single dose of pimobendan on healthy cats. The same result was found in a study by Ro et al. after oral administration of a pimobendan-pentoxyfyllin mixture in dogs [1,18].

Changes in some echocardiographic parameters that indicate systolic function, such as the increase in FS and the decrease in LVIDs, indicate the positive inotropic effect of pimobendan in rabbits.

In this study, we found a decrease in ESV after 3 hours, but there was no significant change in blood volume at the end of diastole. This finding is similar to a finding that Sengklab et al. (2022) obtained in their study [12]. Many studies of M-mode in veterinary medicine, showed

a strong relationship between cardiac volume measurements (ESV, EDV) and cardiac output (19). In this study, the SV increased after half an hour of Pimobendan administration; as a result, despite the lack of change in cardiac output, it can be concluded that pimobendan can increase cardiac output and thus improve cardiac function in diseases such as heart failure which cardiac output decreases. In similar studies that had been done on dogs, different results had been found; SV was increased after pimobendan administration in one of them in dogs with dilated cardiomyopathy, while in another study in dogs with mitral regurgitation, there was no change in SV [20,21].

While in similar studies on dogs, SV was increased after pimobendan administration while in another study evaluated SV in dogs with mitral valve regurgitation, there was no change in SV [20,21].

The ejection fraction was significantly increased after taking pimobendan. Ejection fraction is the gold standard index in evaluating the left ventricle.

It depends on preload, afterload, and heart contractility. In patients with CHF, it can be reduced, which means the heart pumps less than before. With a significant increase of EF in this study, it can be concluded that pimobendan can be used in rabbits that have suffered from CHF or any other diseases that can decrease EF. We can find similar results in an article about 24 dogs with mitral valve disease [11] and another with DCM treated with pimobendan [20].

There are a few studies about LA size after pimobendan administration. In this study, left atrial size at the end of the diastole increased slightly after half an hour and didn't change since then. However, a study on dogs with cardiomyopathy showed that pimobendan in the group treated with it did not cause a change in the size of the left atrium [22]. Also, in a study

on the left ventricular function of myxomatous mitral valve disease in dogs treated with pimobendan, a similar result was obtained, and no change in the size of the left atrium was seen [23]. Pimobendan had similar effects to that in our study in cats in a study which investigated the effects of pimobendan on left atrial transport function in cats [24].

According to the differences in the findings obtained from the effects of pimobendan on the LA in rabbits, more research is needed. The reason for increasing the size of the left atrium in our study wasn't found.

Conclusion

Echocardiographic results after pimobendan administration indicate that pimobendan has useful effects on LV function in healthy rabbits.

Further study is needed to find out whether pimobendan is effective in rabbits with cardiac disease.

Material and Methods

Animals

Islamic Azad University, Karaj Branch approved all the procedures used in the current study for the care and treatment of animals (IR.IAU.K.REC.1401.018). Eleven White New Zealand rabbits (24-30 weeks old and weighing 2.1 ± 0.3 kg) were purchased from Pasteur Institute of Iran (Tehran, Iran), and were engaged in this study. All the rabbits were adopted under supervision after experiments were finished.

Drug

Pimobendan (0.3 mg/kg, Vetmedin 5 mg chewable tablet, Boehringer Ingelheim-Germany) was dissolved in distilled water and administered orally [10]. The medication has been calculated according to the weight of each rabbit, and an appropriate amount of powdered pimobendan, depending on each one's weight, has been separately dissolved in 1 cc of water and gently administered from the corner of their mouth.

Echocardiography protocol

Echocardiography was carried out under spontaneous respiration, and without any anesthesia. It was performed by a single-board certificate radiologist using a GE Vivid 7 ultrasound machine equipped with a phased-array (S10) probe (5-10 MHz).

To obtain the right parasternal window, rabbits were positioned in the right lateral recumbency, and an ultrasound probe was placed in the area on the cranial aspect of the thoracic wall, which was shaved before, through a gap in the echocardiography table.

For a short axis view from the right parasternal, M-mode imaging was made at the level of the papillary muscles. Measurements of the interventricular septum end-systole (IVSs) and end-diastole (IVSd), left ventricular internal diameter end-systole (LVIDs), and end-diastole (LVIDd), and left ventricular free wall in systole (LVFWs), and in diastole (LVFWd) were obtained. The right parasternal short-axis view with M-mode was used for the measurements of aortic and left atrial diameters at the level of the aortic valve. M-mode parameters were measured by the leading-edge method of the American Society of Echocardiography. Left ventricular ejection fraction and fractional shortening were calculated by these formulas:

$$FS = ((LVIDd - LVIDs) / LVIDd) \times 100$$

$$EF = (SV/EDV) \times 100$$

$$SV = EDV - ESV$$

Study design

Rabbits were healthy based on physical, radiology, echocardiography, and hematology examinations.

Chest radiography for possible respiratory disorders was obtained for all of them. The animals were fed with water and pellet. They were housed in steel cages at temperatures of 21-24 °C, with a 12:12 hour light-dark cycle.

Each rabbit went through five echocardiographic examinations: on day 0 the first examinations were done 1 hour apart and possible valvular blood regurgitation and thickening were checked by color Doppler and M-mode imaging. The third examination, the baseline, was done on day 1; the fourth and fifth studies were done 30 minutes and 3 hours after a single dose of pimobendan was administered, respectively [26]. The planning of the echocardiographic assessment time depended on a pharmacokinetics investigation of pimobendan in rabbits [10].

Statistical analysis

To compare the echocardiographic data in pre-drug and post-drug conditions, the average records were collected during

three quantitative assessments of pre-drug. The records were investigated between time points using SAS-9.2 software.

In this research, the primary descriptive statistics of the data were extracted, and the primary statistical distributions of the data were obtained and investigated. Examining the normal distribution of data and variance independence, test was performed with the Kolmogorov-Smirnov test at a statistical level of 5%. Then ANOVA procedure was used for the analysis of variance.

The mean values and standard deviations for each experimental group, including the records of pre-drug, half, and three hours after taking the drug for each parameter extracted, and comparison between the averages was done with Duncan's multiple range test. The coefficient of variation, mean value, and total standard deviation with the level of significance were calculated. Differences at $p < 0.05$ were considered significant.

References

1. Yata M, McLachlan AJ, Foster DJR, Hanzlicek AS, Beijerink NJ. Single-dose pharmacokinetics and cardiovascular effects of oral pimobendan in healthy cats. *Journal of Veterinary Cardiology*. 2016 Dec 1;18(4):310–25. Doi: 10.1016/j.jvc.2016.07.001.
2. Yata M, McLachlan AJ, Foster DJR, Page SW, Beijerink NJ. Pharmacokinetics and cardiovascular effects following a single oral administration of a nonaqueous pimobendan solution in healthy dogs. *J Vet Pharmacol Ther*. 2016 Feb 1;39(1):45–53. Doi: 10.1111/JVP.12243.
3. Yanni AE. The laboratory rabbit: An animal model of atherosclerosis research. *Lab Anim [Internet]*. 2004 Jul 23 [cited 2022 Aug 4];38(3):246–56. Available from:

<https://journals.sagepub.com/doi/abs/10.1258/002367704323133628>. Doi:

10.1258/002367704323133628.

4. Gava FN, Zacché E, Ortiz EMG, Champion T, Bandarra MB, Vasconcelos RO, et al. Doxorubicin induced dilated cardiomyopathy in a rabbit model: An update. *Res Vet Sci*. 2013 Feb 1;94(1):115–21. Doi: 10.1016/j.rvsc.2012.07.027.
5. Lord B, Boswood A, Petrie A. Electrocardiography of the normal domestic pet rabbit. *Veterinary Record* [Internet]. 2010 Dec 1 [cited 2022 Aug 4];167(25):961–5. Available from: <https://onlinelibrary.wiley.com/doi/full/10.1136/vr.c3212> Doi: 10.1136/vr.c3212.
6. Turner Giannico A, Ayres Garcia DA, Lima L, de Lara FA, Corona Ponczek CA, Shaw GC, et al. Determination of Normal Echocardiographic, Electrocardiographic, and Radiographic Cardiac Parameters in the Conscious New Zealand White Rabbit. *J Exot Pet Med*. 2015 Apr 1;24(2):223–34. Doi: 10.1053/j.jepm.2015.04.013.
7. Harvey L, Knowles T, Murison PJ. Comparison of direct and Doppler arterial blood pressure measurements in rabbits during isoflurane anaesthesia. *Vet Anaesth Analg*. 2012 Mar 1;39(2):174–84. Doi: 10.1111/j.1467-2995.2011.00685x.
8. Sato K, Chatani F, Sato S. Circadian and short-term variabilities in blood pressure and heart rate measured by telemetry in rabbits and rats. *J Auton Nerv Syst*. 1995 Sep 5;54(3):235–46. Doi: 10.1016/0165-1838(95)00016-Q.
9. Hagemeyer F. Calcium sensitization with pimobendan: pharmacology, haemodynamic improvement, and sudden death in patients with chronic congestive heart failure. *Eur*

- Heart J [Internet]. 1993 Apr 1 [cited 2022 Aug 4];14(4):551–66. Available from:
<https://academic.oup.com/eurheartj/article/14/4/551/654956> Doi:
10.1093/eurheartj/14.4.551.
10. Ozawa SM, Guzman DSM, Hawkins MG, Diao SM, Masri AE, Gunther-Harrington CT, et al. Pharmacokinetics of pimobendan following oral administration to New Zealand White rabbits (*Oryctolagus cuniculus*). Am J Vet Res [Internet]. 2022 Apr 1 [cited 2022 Aug 4];83(4):356–63. Available from:
<https://avmajournals.avma.org/view/journals/ajvr/83/4/ajvr.21.03.0032.xml> Doi:
10.2460/ajvr21.03.0032.
 11. Ouellet M, Bélanger MC, DiFruscia R, Beauchamp G. Effect of pimobendan on echocardiographic values in dogs with asymptomatic mitral valve disease. J Vet Intern Med. 2009;23(2). Doi: 10.1111/j.1939-1676-2008.0239.x.
 12. Saengklub N, Boonyarattanasoonthorn T, Kijawornrat A, Chantasart D. Preliminary Bioequivalence of an Oral Pimobendan Solution Formulation with Reference Solution Formulation in Beagle Dogs. Vet Sci. 2022;9(3). Doi: 10.3390/vetsci9030141.
 13. Klein S, Nolte I, Rumstedt K, Sehn M, Raue JF, Weiner F, et al. The effect of treatment with pimobendan in dogs with preclinical mitral valve disease – a placebo-controlled double-blinded crossover study. BMC Vet Res. 2021;17(1). Doi: 10.1186/s12917-021-03014-5.
 14. Häggström J, Boswood A, O’Grady M, Jöns O, Smith S, Swift S, et al. Longitudinal analysis of quality of life, clinical, radiographic, echocardiographic, and laboratory

- variables in dogs with myxomatous mitral valve disease receiving pimobendan or benazepril: The QUEST study. *J Vet Intern Med.* 2013;27(6). Doi: 10.1111/jvim.12181.
15. Boswood A, Gordon SG, Häggström J, Wess G, Stepien RL, Oyama MA, et al. Longitudinal Analysis of Quality of Life, Clinical, Radiographic, Echocardiographic, and Laboratory Variables in Dogs with Preclinical Myxomatous Mitral Valve Disease Receiving Pimobendan or Placebo: The EPIC Study. *J Vet Intern Med.* 2018;32(1). Doi: 10.1111/jvim.14885.
 16. Serres F, Chetboul V, Tissier R, Poujol L, Gouni V, Carlos Sampedrano C, et al. Comparison of 3 ultrasound methods for quantifying left ventricular systolic function: Correlation with disease severity and prognostic value in dogs with mitral valve disease. *J Vet Intern Med.* 2008;22(3). Doi: 10.1111/J.1939-1676.2008.0097.x.
 17. Tissot C, Singh Y, Sekarski N. Echocardiographic evaluation of ventricular function-for the neonatologist and pediatric intensivist. Vol. 6, *Frontiers in Pediatrics.* 2018. Doi: 10.3389/fped.2018.00079.
 18. Ro W Bin, Song DW, Kim KH, Jeong SH, Kang MH. Pharmacokinetics and pharmacodynamics of pimobendan-pentoxifylline liquid mixture after oral administration in dogs. *Journal of Veterinary Clinics.* 2019;36(3). Doi:10.17555/jvc.2019.06.36.3.159.
 19. Uehara Y, Takahashi M, Koga M. Determination of cardiac output by echocardiography. *Journal of Veterinary Medical Science.* 1995;57(3). Doi: 10.1292/jvms.57.401.

20. Sergeev D, Kovalev S, Trushkin V, Vasilev R, Nikitina A, Kiselenko P, et al. Use of high doses of pimobendan in animals with dilated cardiomyopathy. *The FASEB Journal*. 2021;35(S1). Doi: 10.1096/FASEBJ.2021.35.S1.01489.
21. Kanno N, Kuse H, Kawasaki M, Hara A, Kano R, Sasaki Y. Effects of pimobendan for mitral valve regurgitation in dogs. *Journal of Veterinary Medical Science*. 2007;69(4). Doi: 10.1292/JVMS.69.373.
22. Abbott-Johnson K, Pierce K V., Roof S, Rio CL del, Hamlin R. Acute Effects of Pimobendan on Cardiac Function in Dogs With Tachycardia Induced Dilated Cardiomyopathy: A Randomized, Placebo-Controlled, Crossover Study. *Front Vet Sci*. 2021;8. Doi: 10.3389/fvets.2021.646437.
23. Sarcinella F, Neves J, Maddox TW, Hodgkiss-Geere HM, Bode EF, Dukes-Mcewan J. Effect of pimobendan on left atrial function in dogs with preclinical myxomatous mitral valve disease. *Open Vet J*. 2019;9(4):375–83. Doi: 10.4314/ovj.v9i4.16.
24. Kochie SL, Schober KE, Rhinehart J, Winter RL, Bonagura JD, Showers A, et al. Effects of pimobendan on left atrial transport function in cats. *J Vet Intern Med*. 2021;35(1). Doi: 10.1111/jvim.15976.
25. Boon, J.A. In: Boon, J.A., editor. *Two-dimensional and M-mode Echocardiography for Small Animal Practitioner*. 2nd ed. John Wiley and Sons Inc., New York, United states. 2016. Doi: 10.1002/9781119028574
26. Valentin L. Effect of a single dose of pimobendan on right ventricular and atrial function in 11 healthy cats. Available from:

www.zora.uzh.chYear:2020URL:<https://doi.org/10.5167/uzh-192133>. Doi:

10.1016/j.jvc.2021.08.006.

Uncorrected Proof

Figure 1. Echocardiographic parameters in a rabbit before (lower image) and 3 hours after (upper image) orally administration of pimobendan at 0.3 mg/kg.

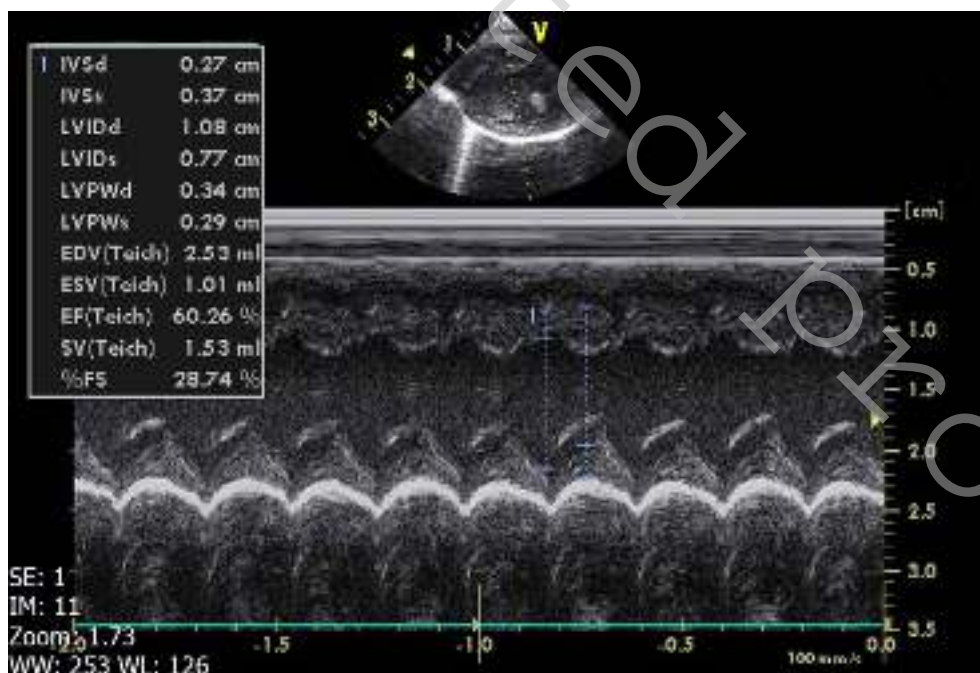
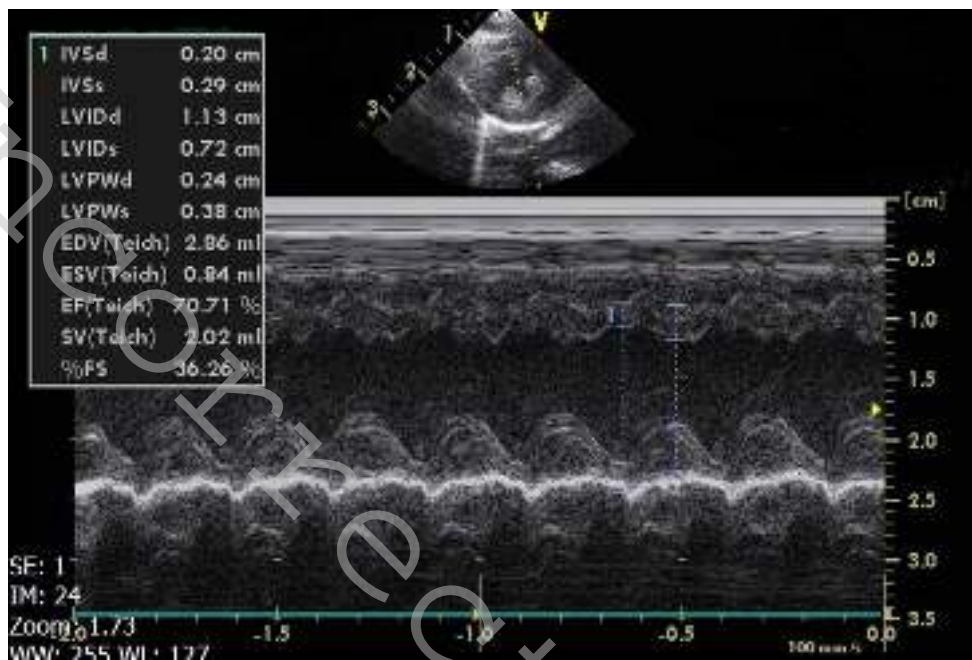


Figure 2. Left atrium size and mitral annulus diameter during systole (upper image) and diastole (lower image).

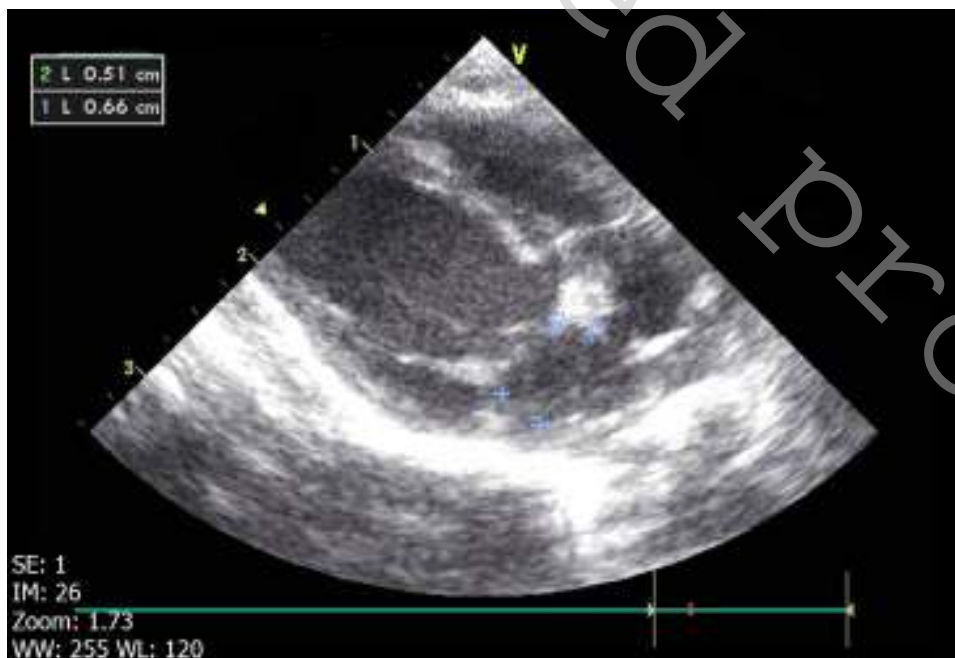
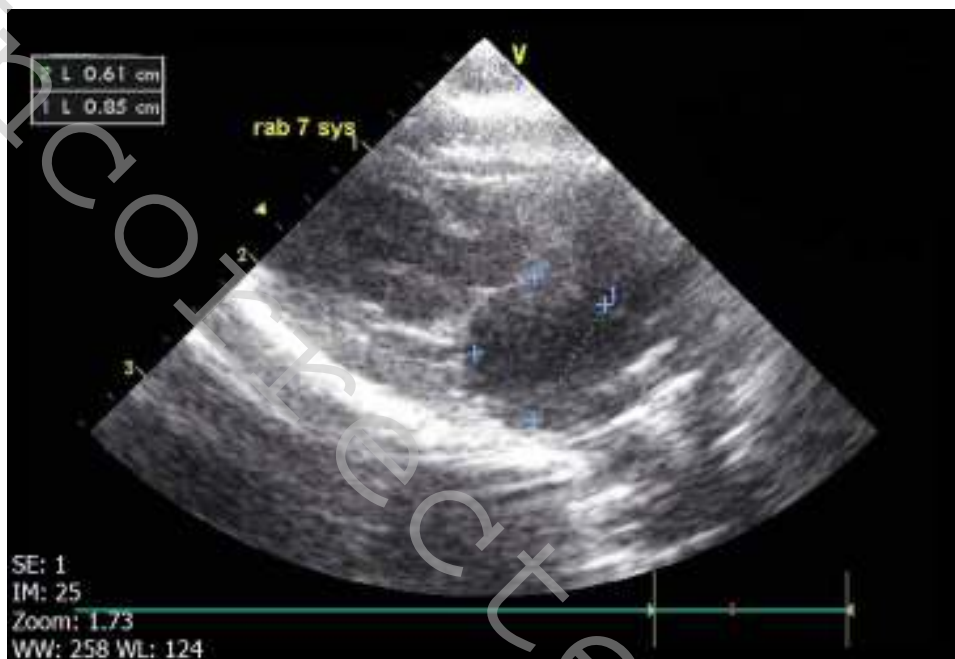

Table 1. Comparison of echocardiographic parameters before and after pimobendan administration

Variables	pre-drug	post-drug	<i>p</i> -value
IVSd	0.23 ± 0.02	0.22 ± 0.01	0.2158
IVSs	0.31 ± 0.01	0.32 ± 0.01	0.1388
LVIDd	1.05 ± 0.01	1.09 ± 0.02	0.2537
LVIDs	0.74 ± 0.02	0.73 ± 0.02	0.0343
LVPWd	0.29 ± 0.01	0.29 ± 0.01	0.4537
LVPWs	0.28 ± 0.01	0.30 ± 0.01	0.0007
EDV	2.36 ± 0.58	2.61 ± 0.13	0.2632
ESV	0.92 ± 0.16	0.89 ± 0.05	0.038
FS%	29.4 ± 0.64	32.95 ± 0.76	0.0001
EF%	60.99 ± 0.47	65.94 ± 0.99	0.0001
SV	1.4 ± 0.26	1.71 ± 0.09	0.0284
LA max	0.76 ± 0.02	0.78 ± 0.01	0.2736
LA min	0.57 ± 0.01	0.60 ± 0.01	0.0272
MVA max	0.52 ± 0.01	0.53 ± 0.01	0.7082
MVA min	0.46 ± 0.02	0.47 ± 0.01	0.3111
LA/Ao	1.12 ± 0.02	1.12 ± 0.02	0.7919

عنوان مقاله: بررسی اثر تک دوز پیموبندان بر پارامتر های اکوکاردیوگرافی عملکرد قلب

خرگوش های سالم نژاد سفید نیوزلندی

نویسندگان:

آریانا عسکری قلپی¹، علی مرادگنججه²، وریا توحیدی³، علی روستایی⁴

¹ گروه دامپزشکی، دانشکده دامپزشکی، دانشگاه آزاد واحد کرج، کرج، ایران
² گروه فارماکولوژی، دانشکده دامپزشکی، دانشگاه آزاد واحد کرج، کرج، ایران
³ گروه رادیولوژی، دانشکده دامپزشکی، دانشگاه آزاد واحد کرج، کرج، ایران
⁴ گروه جراحی و رادیولوژی، دانشکده دامپزشکی، دانشگاه تهران، تهران، ایران

نویسنده مسئول: دکتر علی مرادگنججه

آدرس پستی: ایران، کرج، دانشگاه آزاد، واحد کرج، دانشکده دامپزشکی، گروه فارماکولوژی

ایمیل سازمانی: Moradganjeh@kiaou.ac.ir

شماره تلفن: 09122507213

خلاصه فارسی:

با توجه به روند رو به رشد نگهداری خرگوش بررسی بیماری های قلبی خرگوش و درمان آن ها الزامی می باشد. یکی از رایج ترین داروهای قلبی مورد استفاده در دامپزشکی پیموبندان است. پیموبندان در مدیریت درمان نارسایی قلبی پر کاربرد است. استفاده از این دارو در خرگوش صرفا بر اساس تجربه بالینی و تجربیات به دست آمده در سگ ها است و هنوز تایید نشده است. بنابراین اولین قدم تایید اثر این دارو بر عملکرد قلب است که یکی از راه های سنجیدن آن اکوکاردیوگرافی است.

11 خرگوش هر کدام 5 بار برای اکوکاردیوگرافی فرستاده می شود. اولین و دومین بررسی اکوکاردیوگرافیک روز 0 به فاصله یک ساعت از هم انجام می شود. در روز 1، سومین بررسی اکوکاردیوگرافیک پیش از دادن پیموبندان و چهارمین و پنجمین بررسی، به ترتیب نیم ساعت و 3 ساعت پس از دادن تک دوز پیموبندان (0.3 mg/kg) انجام می شود.

تجویز خوراکی پیموبندان در خرگوش های سالم باعث ایجاد تغییراتی در برخی پارامتر های اکوکاردیوگرافی شد. از جمله، EF، FS، SV، LVPWS و اندازه دهلیز چپ در انتها دیاستول افزایش یافت (p=0.0001، p=0.0001، p=0.0284، p=0.0272 و p=0.0007، به ترتیب) در حالی که LVIDs و ESV کاهش یافت. (p=0.038 و p=0.0343، به ترتیب)

این مطالعه نشان داد که پیموبندان اثرات مثبتی بر روی بطن چپ داشته و باعث بهبود عملکرد کلی قلب شد. مطالعات بیشتری لازم است تا مشخص شود که تاثیر پیموبندان در خرگوش ها با بیماری قلبی مشابه تاثیری است که در این مطالعه بر خرگوش های سالم گذاشته است یا خیر.

واژگان کلیدی: پیموبندان، اکوکاردیوگرافی، عملکرد قلبی، خرگوش، سالم

Uncorrected Proof